계명대학교 동산병원
KEIMYUNG UNIVERSITY DONGSAN HOSPITAL

Clinical and Radiologic outcomes of MMPH root repair using a transtibial double tunnel pull-out technique using M-A stitches

계명대학교 동산병원 정형외과
스포츠의학 및 관절경
김두한

Natural course of MM root tear

Non-operative management of medial meniscus posterior horn root tears is associated with worsening arthritis and poor clinical outcome at 5-year follow-up

Aaron J. Krych[1] · Patrick J. Reardon[1] · Nick R. Johnson[1] · Rohith Mohan[1] · Logan Peter[1] · Bruce A. Levy[1] · Michael J. Stuart[1]

Knee Surg Sports Traumatol Arthrosc (2017) 25:383–389
DOI 10.1007/s00167-016-4359-8

AOSSM Annual Meeting 2016

Table 1 Summary of non-operative treatments of MMPRTs

Physical therapy (*n*, %)	27	52 %
Injection (*n*, %)	42	81 %
Knee brace (*n*, %)	10	19 %
Orthotic (*n*, %)	2	4 %
Cane/crutches (*n*, %)	11	21 %

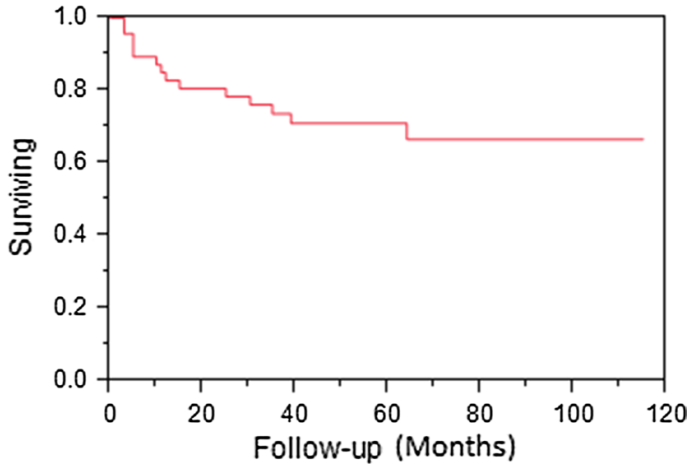

Conservative Tx. : 52 patients

16 (31%) patients – conversion to TKA at mean 30±32 months

Failure : 87% of patients

Partial meniscectomy for MM root tear

Partial meniscectomy provides no benefit for symptomatic degenerative medial meniscus posterior root tears

Aaron J. Krych[1] · Nick R. Johnson[1] · Rohith Mohan[1] · Diane L. Dahm[1] · Bruce A. Levy[1] · Michael J. Stuart[1]

	PMM group	Non-operative group	*p* value
IKDC Score, mean ± SD	67.8 ± 19.8	57.8 ± 23.4	n.s
Tegner Score, median (range)	3 (2–7)	4 (2–6)	n.s
Final K-L Grade, median (range)	2 (1–4)	3 (1–4)	n.s
Presence of arthritis (%)	91.3%	79.2%	n.s
Progression to arthroplasty, *n* (%)	14 (54.0%)	9 (34.6%)	n.s
Time to arthroplasty (months), mean ± SD	54.3 ± 35.4	30.2 ± 38.2	n.s

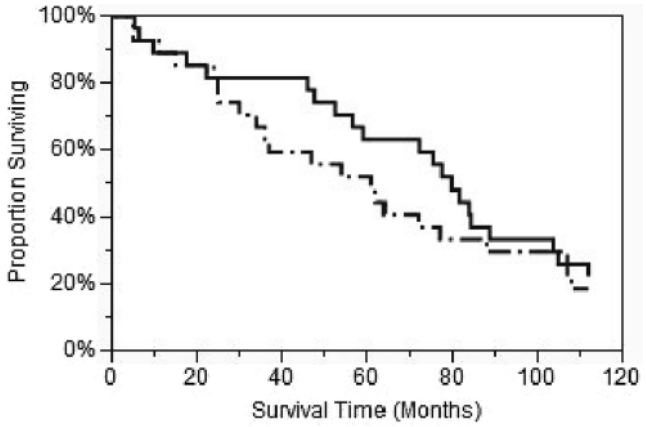

Partial meniscectomy

- Poor clinical outcomes
- Progress to significant arthritis
- Conversion to TKA : 54% at 5-year follow-up.

Challenging situation

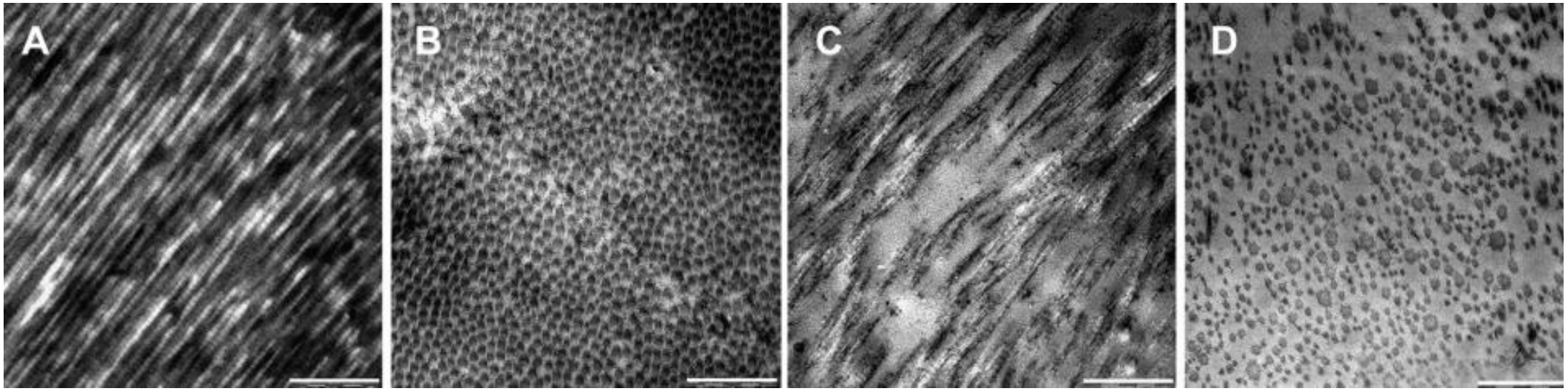

Intact meniscus root *Torn meniscus root*

- Disrupted collagen fibers
- Intrafibrillar edema
- Severe disarray

Seo YJ et al, AJSM, 2019

Purpose

- To evaluate clinical and radiographic outcomes of MMPRR using transtibial double tunnel pull-out technique with MA stitches.

- We hypothesized that the clinical & radiological outcomes after this surgery would be improved at 1 year follow-up.

Method

- Inclusion criteria
  - ➢Younger than 70 years of age
  - ➢OB classification (MRI) less than grade
  - ➢KL grade less than grade I
  - ➢Symmetric alignment (<5°)
  - ➢Willingness to undergo gradual rehabilitation
  - ➢Minimum 12 months follow-up

Table 1. Indications for Repair of Medial Meniscus Posterior Root Tears

No.	Indications
1	Younger than 65 years of age
2	Outerbridge classification of less than grade 3
3	Kellgren-Lawrence grade I or II, some salvage cases for grade III
4	Symmetric alignment (<3°)
5	Ability to endure a relatively high-demand activity
6	Willingness to undergo partial weight bearing for more than 6 weeks

➔ ***29 patients***

Outcomes

- Clinical outcomes
  - ➢VAS pain score
  - ➢IKDC score
  - ➢Lysholm score
- Radiographic outcomes
  - ➢K-L grade
  - ➢Hip-knee-ankle angle

MRI findings

- Root repair continuity
  1. well-healing
  2. partial healing
  3. re-tear
- Root healing state
  1. well-healing (low signal)
  2. partial healing (intermediate signal)
  3. re-tear (high signal)
- Meniscus medial extrusion

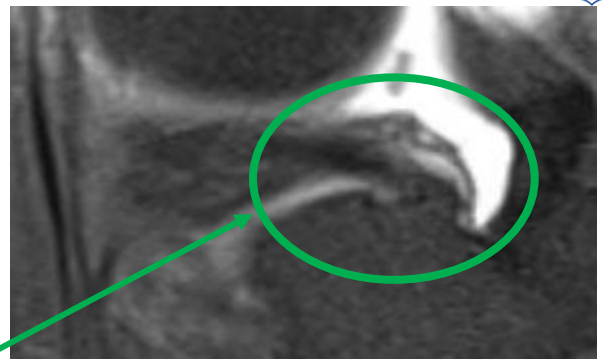

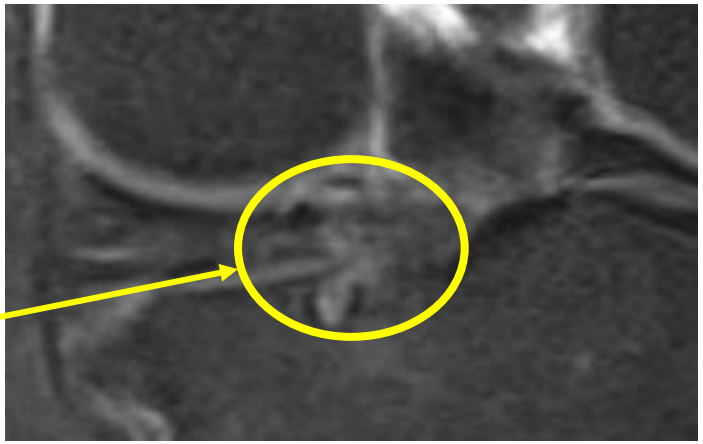

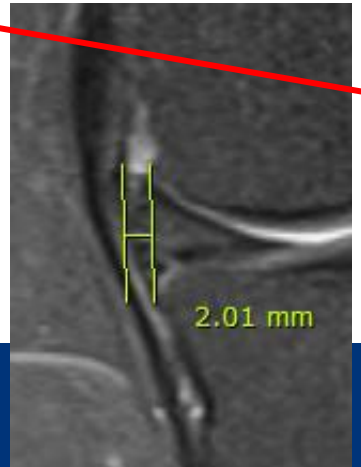

Surgical technique - MCL release

dMCL subperiosteal stripping

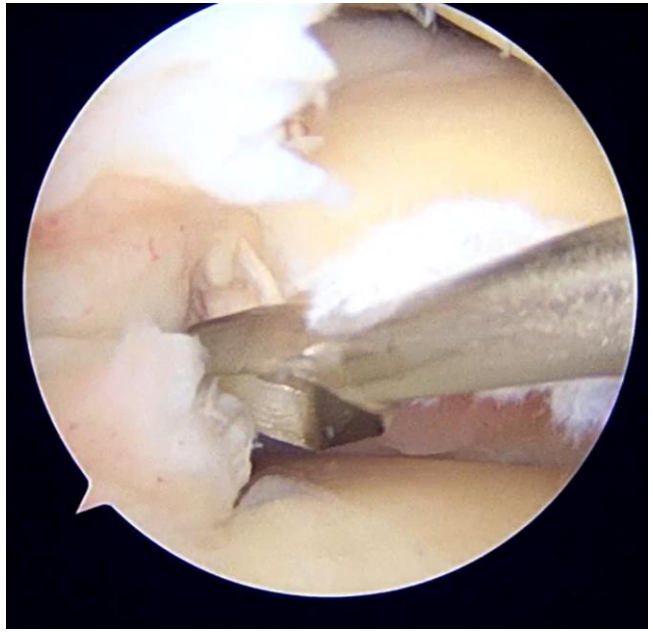

Thorough decortication

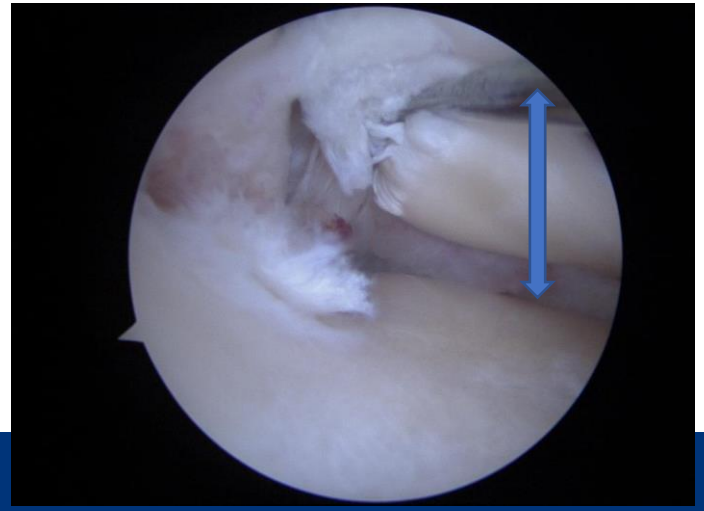

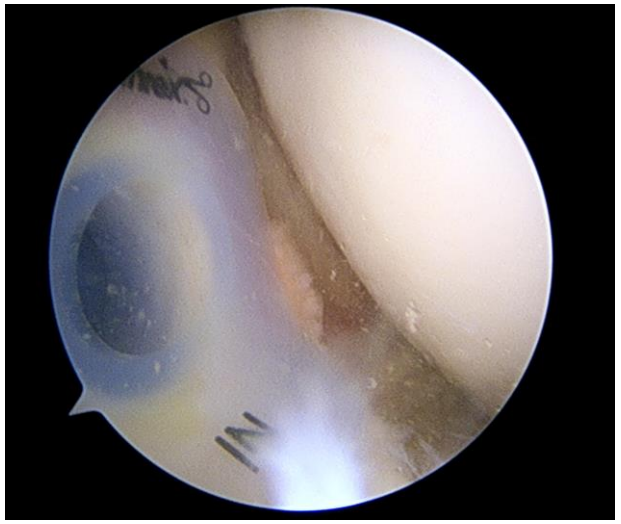

Jeon SW et al, KSSTA, 2017
Chung KS et al, Arthroscopy, 2017

Repair technique

medicina MDPI

계명대학교 동산병원
KEIMYUNG UNIVERSITY DONGSAN HOSPITAL

Technical Note

Posterior Medial Meniscus Root Repair Using Two Transtibial Tunnels with Modified Mason–Allen Stitches: A Technical Note

Du-Han Kim *, Ki-Cheor Bae, Chang-Jin Yon and Ji-Hoon Kim

Hospital, Keimyung University School of

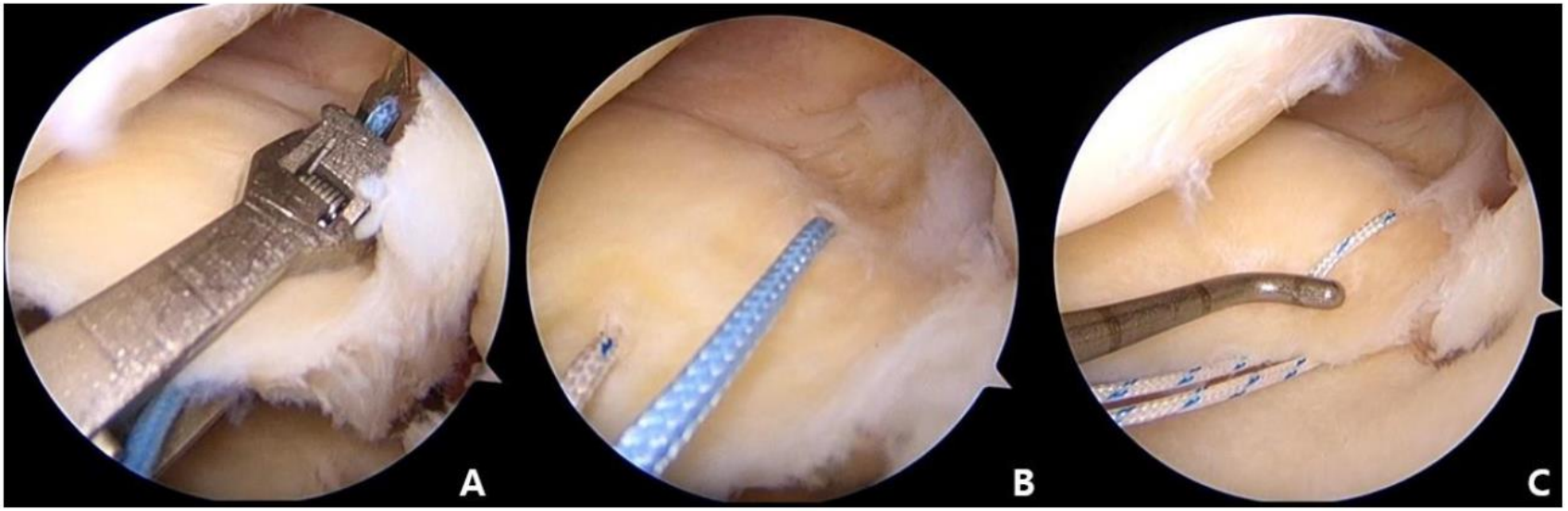

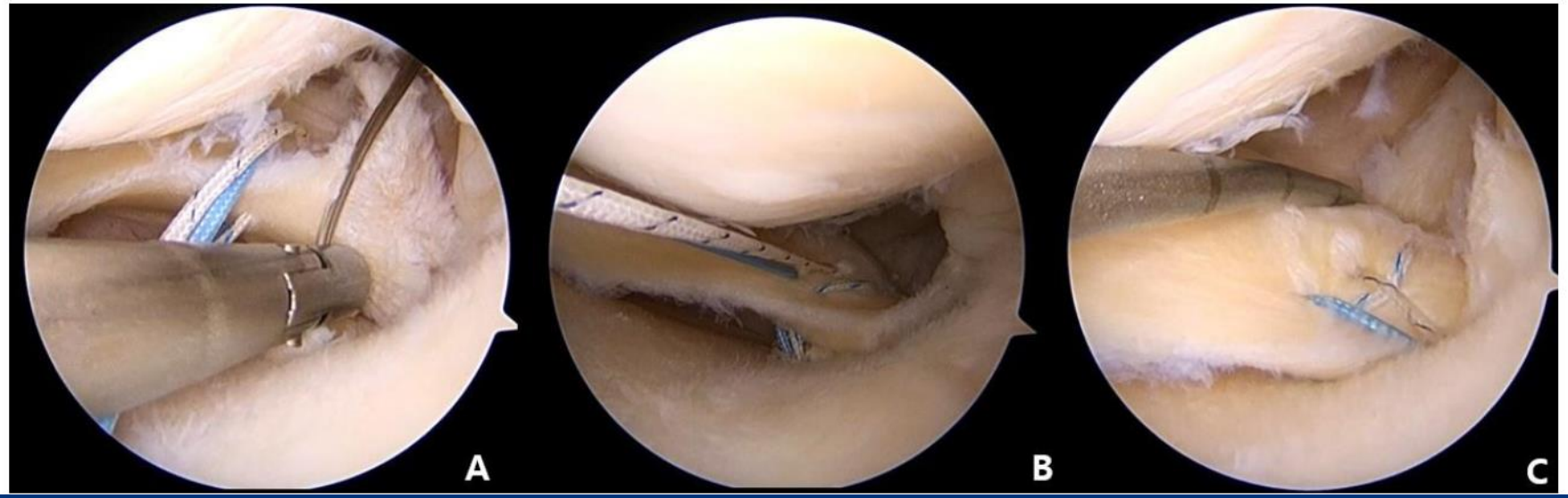

Results

- 29 patients, 59.9 ± 6.5 y (M 2, F 27), Mean follow-up 29.3 mo

	Preoperative	Follow-up	*p*-value
Clinical outcomes			
VAS pain	4.9 ± 2.2	1.6 ± 1.2	< 0.001*
IKDC	40.5 ± 10.4	70.0 ± 14.9	< 0.001*
Lysholm	60.0 ± 10.3	85.4 ± 10.7	< 0.001*
Radiologic outcomes (n =29)			
K-L grade	25/4/0/0/0	18/9/2/0/0	
Hip-knee-ankle angle	1.9 ± 1.7	2.5 ± 1.7	0.075
FU MRI findings (n =11)			
Continuity	-	6/5/0	
Healing state	-	5/5/1	
MME (mm)	2.9 ± 1.0	2.2 ± 1.2	0.047*

*Significant difference

Results - MRI findings

- Root repair continuity
  1. well-healing ➢ 54.5%
  2. partial healing ➢ 45.5%
  3. re-tear ➢ 0%
- Root healing state
  1. well-healing (low signal) ➢ 45.5%
  2. partial healing (intermediate signal) ➢ 45.5%
  3. re-tear (high signal) ➢ 9.0%
- Meniscus medial extrusion
  ➢ 0.7mm ↓

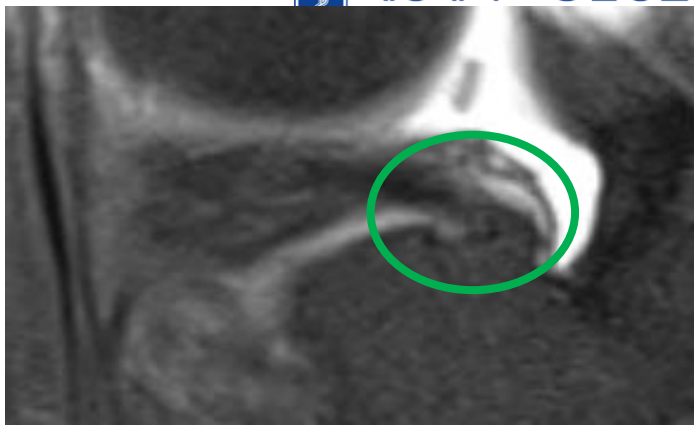

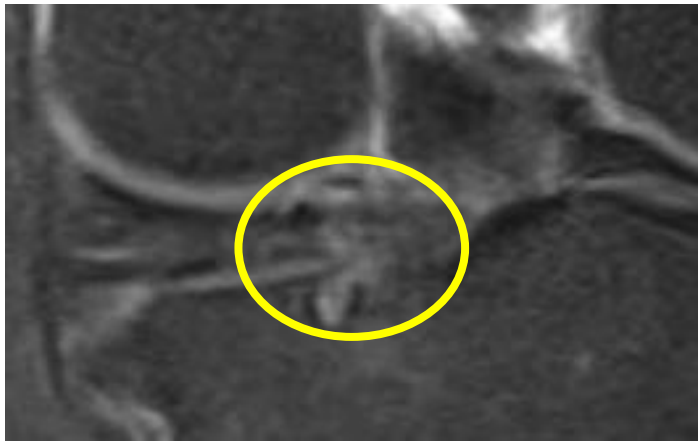

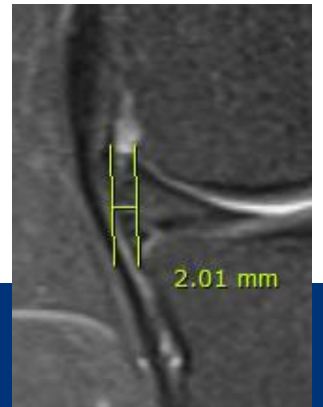

Conclusion

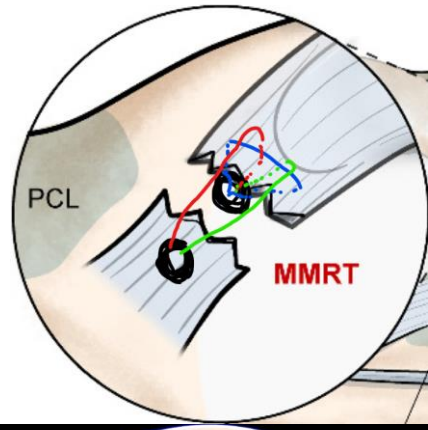

- Arthroscopic MMPRR using a transtibial double tunnel pull-out technique with modified MA stitches improved clinical and radiographic outcomes. (Minimun 1-year follow-up)

- Well-designed, comparative & prospective studies are needed better to understand the results of this technique.

계명대학교 동산병원
KEIMYUNG UNIVERSITY DONGSAN HOSPITAL

Thanks for your attention!!