ISAKOS CONGRESS 2025 | MUNICH GERMANY June 8–11

Patient Specific Instrument-Guided Distal Femur Biplanar Osteotomy of Valgus Knees

Jui-Cheng Lin, M.D.
Jia-Lin Wu, M.D., M.S.
Department of Orthopedics,
Taipei Medical University Hospital, Taipei, Taiwan

Faculty Disclosure Information

The faculty/speaker has no relevant financial relationships with ineligible companies and no conflicts of interest related to this presentation.

Introduction

- Distal femoral varus osteotomy (DFVO) is used to correct valgus malalignment combined with lateral compartment osteoarthritis [1].

- Clinical outcomes depend on construct stability, bony union time, and correction precision [2].

- This study aimed to evaluate the radiographic and functional outcomes of patient-specific instrument (PSI)-guided, distal femur varus-producing biplanar osteotomy in the knee joint.

Methods:

- Seventeen valgus knees with a mechanical lateral distal femoral angle (mLDFA) < 85° were studied, including three post-traumatic malunions.

- **Inclusion criteria :** (1) Kellgren–Lawrence grade 2–3 lateral compartment osteoarthritis. (2) MA passing >60% medial tibial articular margin. (3) mLDFA < 85° with normal MPTA.

- **Exclusion criteria** were inflammatory arthritis, multiple compartment osteoarthritis, severe joint space narrowing, or knee ligament instability.

Methods:

- All patients underwent PSI-guided osteotomy using either the **medial closing wedge (MCW) or lateral opening wedge (LOW)** technique.

- The correction targeted the mechanical axis (MA) at 50% of the tibial plateau width.

- Outcome measurements included MA, mLDFA, bony union time, and Oxford Knee Score (OKS). The mean follow-up period was 12.6 months.

MCW Techniques

- (A) The MCW PSI featured a "Ꞗ"-shaped biplanar cutting slot and two saw pin holes for positional wires , targeting the hinge point.
- (B) The asterisk (*) denotes the utilization of an additional K-wire for fixation.
- (C) The 3D module of the MCW DFVO. This module simulates the location of PSI placement, estimated correcting angle, depth of bone cuts, and wedge thickness.

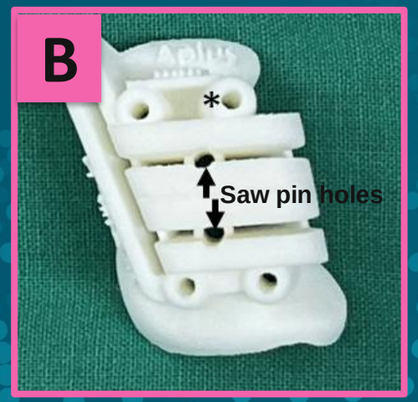

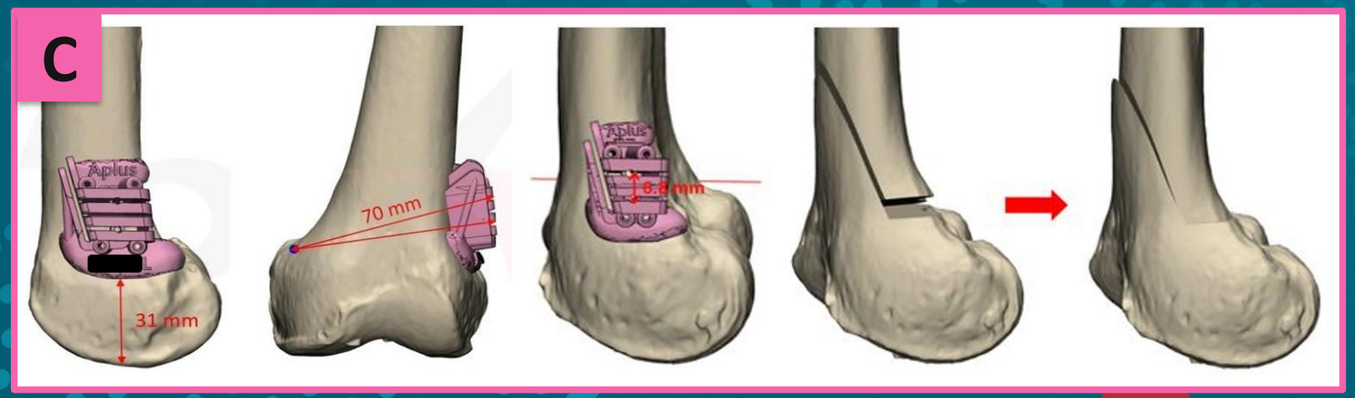

MCW Techniques & LOW

- (D) Two positional K-wires were inserted through the saw pin holes to target the hinge point, followed by four additional K-wires for fixation. The positional wires were then removed.

- (E) After completing the osteotomy, the osteotomy was gradually closed and stabilized using a medial plate.

- (F) In the LOW DFVO technique, the PSI contained a “⌋”-shaped cutting slot

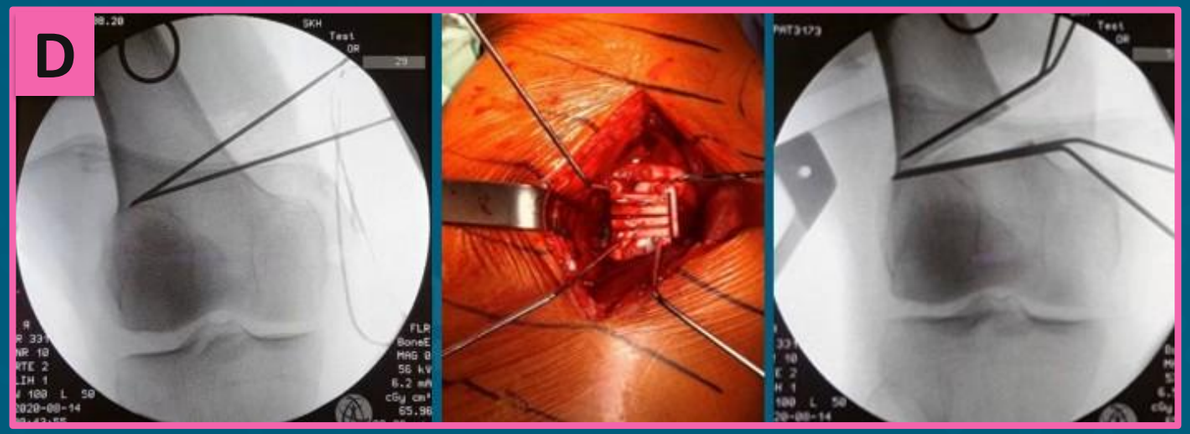

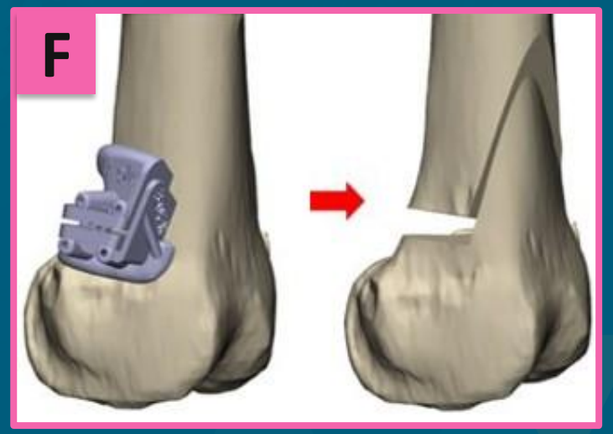

Results:

- The MA was corrected from 84.2% to 50% at the final follow-up, with a 0.6% deviation between the planned and executed MA.
- Bony union at the osteotomy site was achieved in 3.3 months for the MCW group and 8 months for the LOW group.
- The OKS improved significantly from 25.7 to 42.1 points.

Outcomes	Values (Pre-operative)	Values (Final follow-up)	P values
MA	84.2% ± 11.8%	50% ± 4.1%	<0.01
mLDFA	82.6° ± 3.1°	89.7° ± 2.7°	<0.01
OKS	25.7 ± 6.9	42.1 ±3.6	<0.01

Discussion: Surgical Selection MCW vs. LOW

- Why Choose MCW ?
  a) faster bony union time.
  b) postoperative weight-bearing begins 2 to 4 weeks earlier than LOW group [3].

- Why Choose LOW ?
  a) requires only two bone cuts: L-shaped vs. E-shaped in MCW.
  b) osteotomy site allows for intraoperative alignment adjustments.
  c) enables leg lengthening in post-traumatic malunion cases.

Discussion: LOW in post traumatic malunion case

- (G) Left femur post-traumatic malunion and 1.5 cm leg length discrepancy. The MA located at 95.6% .
- (H) After LOW DFVO, the MA was realigned to 50.1%, and the open wedge technique corrected left femur shortening.
- (I) MA remained unchanged after 1-year follow-up.

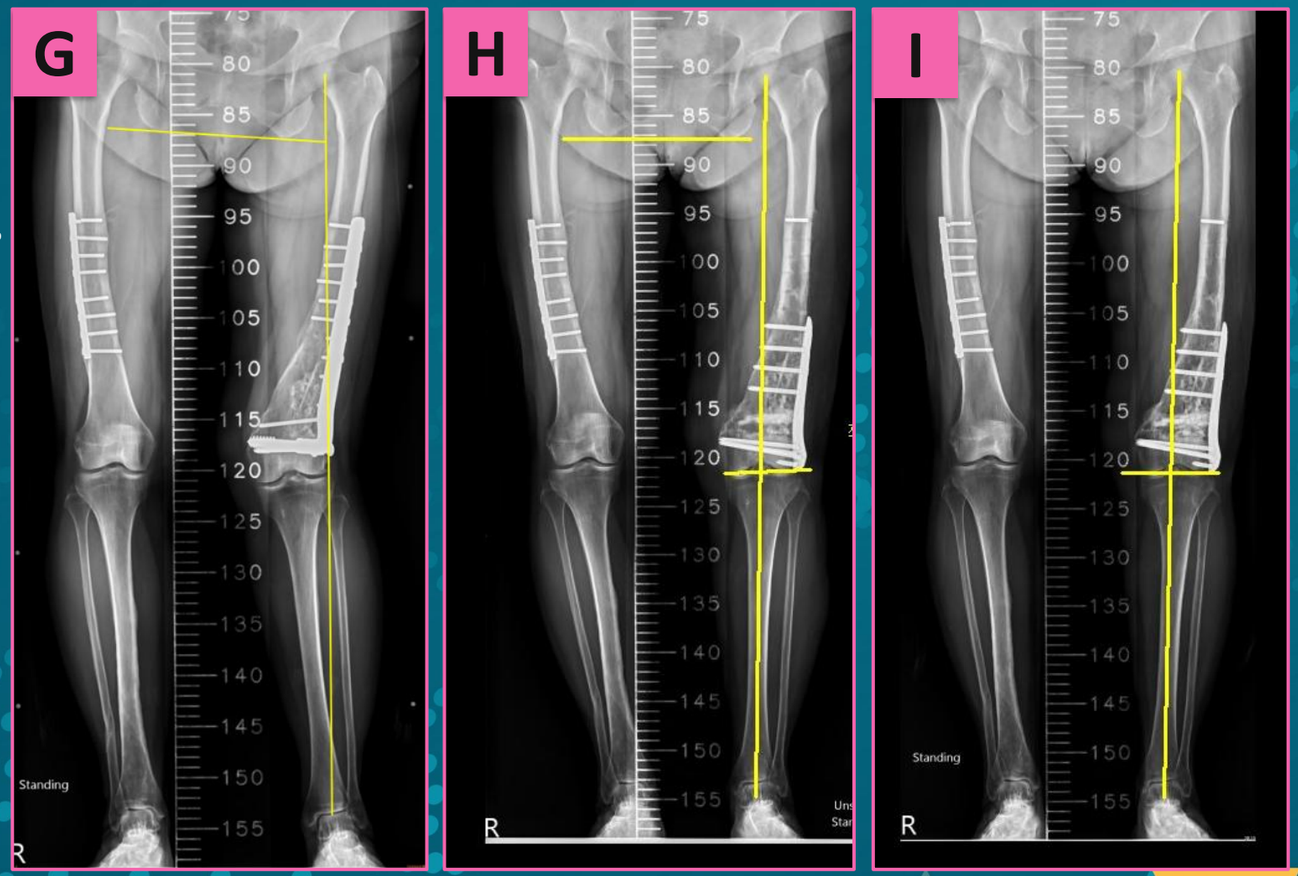

Discussion: biplanar osteotomy vs single-plane

- Faster bone healing & stability [4]
  a) Heals 2 months faster than single-plane (4 vs. 6 months).
  b) Enhanced axial stability & stiffness.

- Preserves patellofemoral joint & anterior femur surface
  a) The anterior flange protect the patellofemoral joint from transverse saw cuts [2]

- Better hinge placement [5]
  a) Placing the hinge more distally in the better-healing metaphyseal bone reduces fracture risk.

Conclusion: Key Benefits of PSI-Guided Biplanar DFVO

- **Accurate Valgus Correction:** PSI-guided improves precision over freehand techniques.
- **Simplifies & Standardizes Surgery:** enhances efficiency and makes the biplanar procedure easier to learn.
- **Optimized for PTOA Cases:** 3D planning reduces osteotomy uncertainty, improving outcomes.
- **Future Potential:** lower 3D printing costs could make PSI the standard for corrective surgery.

Reference:

1. **Sherman SL,** Thompson SF, Clohisy JCF. Distal femoral Varus osteotomy for the management of valgus deformity of the knee. *J Am Acad Orthop Surg* 2018; 26: 313-324. [DOI: 10.5435/JAAOS-D-16-00179]

2. **Brinkman JM,** Hurschler C, Agneskirchner JD, Freiling D, van Heerwaarden RJ. Axial and torsional stability of supracondylar femur osteotomies: Biomechanical comparison of the stability of five different plate and osteotomy configurations. *Knee Surg Sports Traumatol Arthrosc* 2011; 19: 579-587. [DOI: 10.1007/s00167-010-1281-3]

3. **Wylie JD,** Jones DL, Hartley MK, Kapron AL, Krych AJ, Aoki SK et al. Distal femoral osteotomy for the valgus knee: Medial closing wedge versus lateral opening wedge: A systematic review. *Arthroscopy* 2016; 32: 2141-2147. [DOI: 10.1016/j.arthro.2016.04.010]

4. **van der Woude JAD,** Spruijt S, van Ginneken BT, van Heerwaarden RJ. Distal femoral valgus osteotomy: Bone healing time in single plane and biplanar technique. *Strategies Trauma Limb Reconstr* 2016; 11: 177-186. [DOI: 10.1007/s11751-016-0266-2]

5. **Nha KW,** Chang YS, Shon OJ, Shim BJ, Lee JS, Song JS, et al. Where is the target point to prevent cortical hinge fracture in medial closing-wedge distal femoral Varus osteotomy? *J Knee Surg* 2019; 32: 274-279. [DOI: 10.1055/s-0038-1641144]