ISAKOS CONGRESS 2025 | MUNICH GERMANY June 8–11

Augmented artificial bone graft with arthroscopic Bankart repair makes glenoid enlargement and remodeling

Norishige Iizawa MD. PhD[1], Minoru Yoneda MD[2]. PhD,
Atsushi Okubo MD. PhD[3], Hiroaki Shirao MD[3], Naohiko Tomita MD[3],
Eishi Nakamura MD[3]

1: Dept. Orthopaedic Surg., Heisei Tateishi hospital, Japan
2: Dept. Orthopaedic Surg., ISEIKAI international general hospital, Japan
1: Dept. Orthopaedic Surg., Nippon Medical School, Japan

Heisei Tateishi Hospital

Faculty Disclosure Information

IIZAWA, Norishige

- **Education:**
  Medical school: Nippon Medical School, Tokyo, Japan. (1985-1991)
  Residency: Nippon Medical School Hospital, Tokyo, Japan(1991-1993)
  Graduate school: Nippon Medical School, Tokyo, Japan (1993-1997)

- **Hospital appointments:**
  1997-2002; Chief, Dept. of Orthopaedic Surgery, Kitamurayama Hospital.
  2002- ; Assistant Professor, Dept. of Orthopaedic Surgery, Nippon Medical School Hospital.
  2023- ; Associate Professor, Dept. of Orthopaedic Surgery, Nippon Medical School Hospital.
  2024- ; Vice director, Heisei Tateishi Hospital

- **I have no financial disclosure**

Introduction

Risk factors for recurrent instability after arthroscopic Bankart repair (ABR)

- **glenoid bone loss**
- contact/collision athletes
- age < 22 years
- male

1. Burkhart SS. 2000
2. Randelli P. 2012

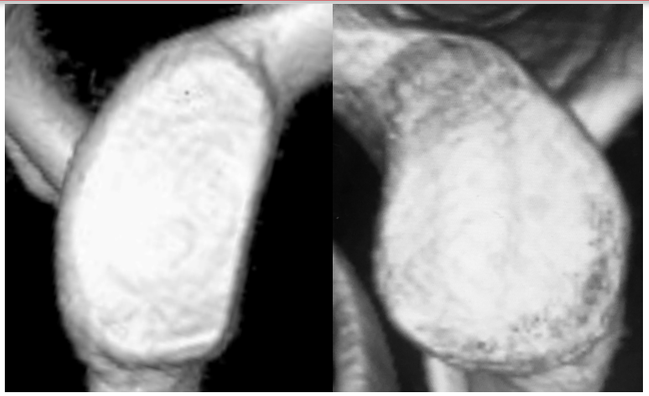

- **≥ 20% glenoid bone loss**
- **< 20% glenoid bone loss with high risk**

ABR with Double Anchor Footprint Fixation (**DAFF**)
+ arthroscopic artificial bone graft

ABR with DAFF + arthroscopic artificial bone graft

3. Iizawa N, et al. KSSTA. 2020

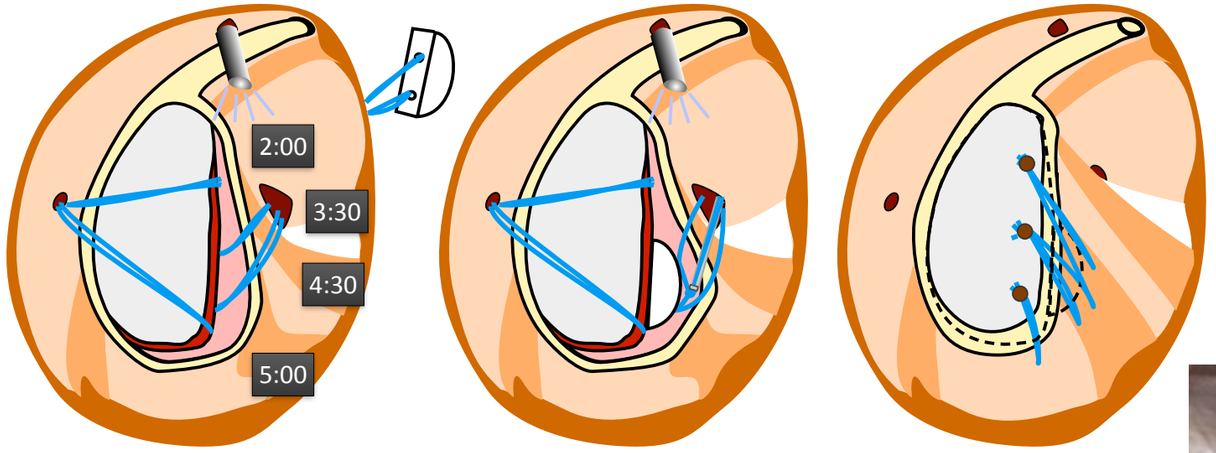

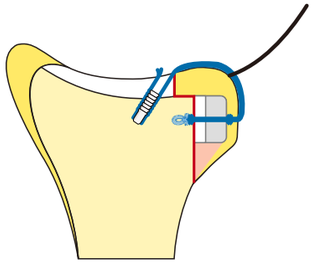

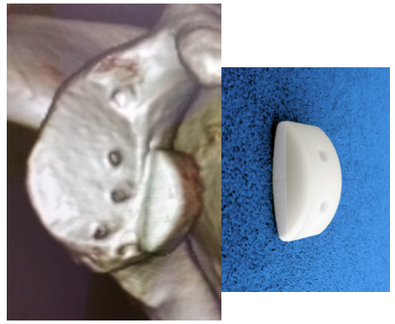

neck anchor: Jugger Knot (Zimmer Biomet)

face anchor: Gryphon BR (DePuy Synthes)

artificial bone: NEOBONE X2 (Aimedic MMT)

Postoperative management

-3W	immobilization	
3W-		ROM ex.
6W-	sling off	muscle strength ex.
3M-		unrestricted ADL
6M-		return to sports activity

Purpose

To evaluate the bone fusion status and bone reaction around the implanted artificial bone using Computed Tomography (CT) images

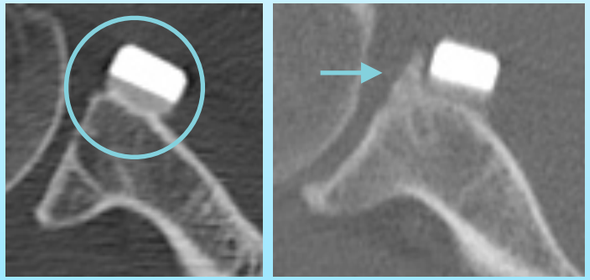

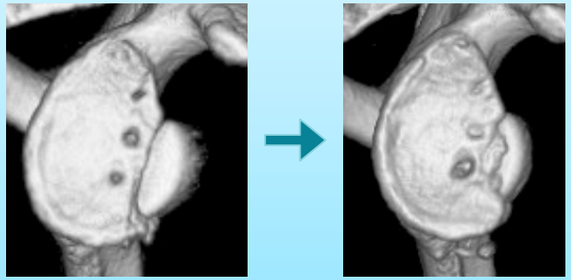

Materials and Methods

31 cases: Jan. 2016 - Dec. 2022

ABR with artificial bone graft augmentation

follow-up period > 12 months

age, years; mean±SD (median, range)	32.2 ± 15.2 (26, 17-73)
sex; male / female	22 / 9
side; right / left	23 / 8
follow-up, months; mean±SD (median, range)	16.2 (13, 12-30)

bone defect, %; mean±SD (median, range)	20.0 ± 6.6 (19.0, 10-39)
Rowe score (post-op); mean±SD (median, range)	94.4 ± 6.4 (95.0, 80-100)
re-dislocation rate, %	0

Evaluation using CT images
@immediate post-op (immediate) cf. @final follow-up (final)

1. position/inclination angle of the artificial bone
2. bony fusion status between artificial bone and glenoid recipient bone
3. resorption artificial bone or glenoid bone
4. new bone formation on the glenoid surface: presence rate and size

1. position/inclination angle of the artificial bone

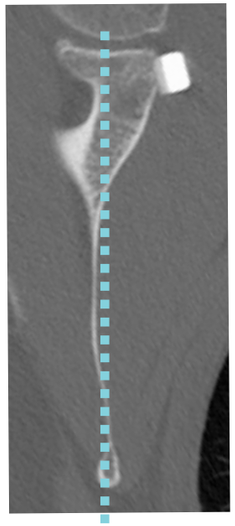

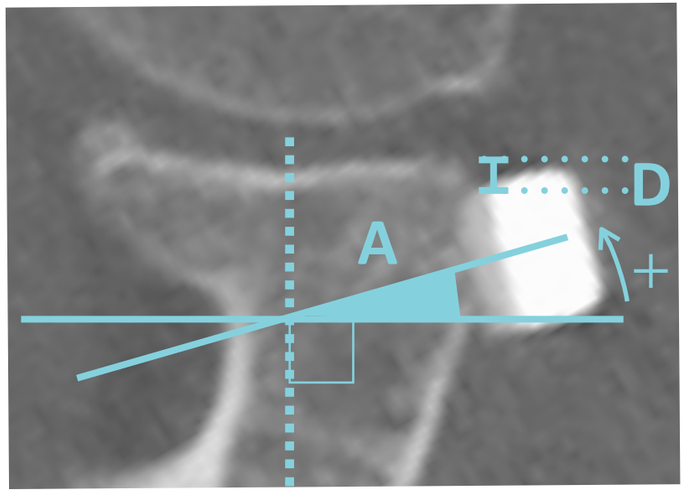

D: **distance** between glenoid surface and artificial bone
@ slice; M

A: **angle** between glenoid surface and artificial bone
@ slice; M

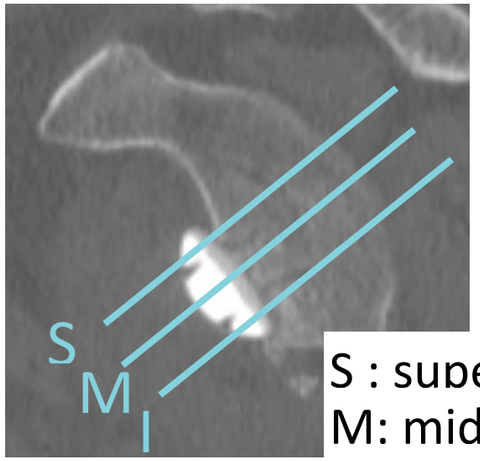

S : superior
M: middle
I : inferior

Evaluation using CT images @ final follow-up (final)

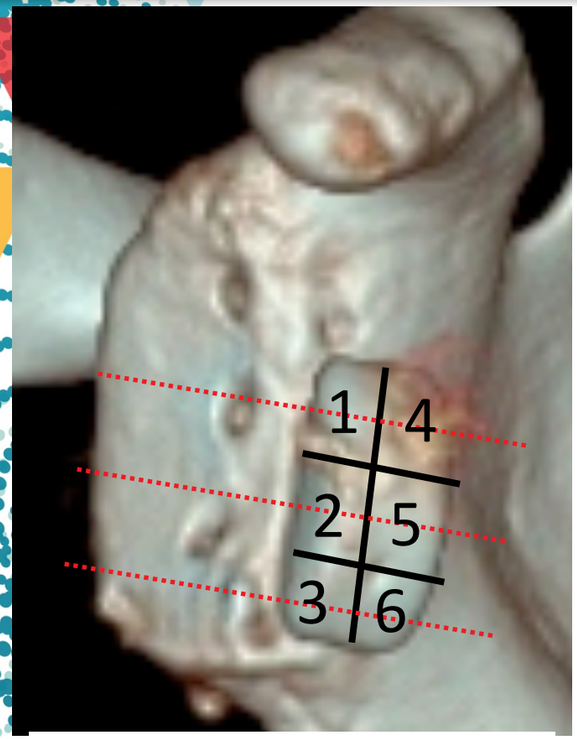

5. Iizawa N, et al. The shoulder joint. 2022

2. bony fusion status @1, 2, 3, 4, 5, and 6

CT-values of border between artificial bone and recipient bone ≥ CT-values of cancellous bone

4. Kanno Y, et al. Regenerative Therapy. 2016

3. resorption of artificial bone or glenoid bone

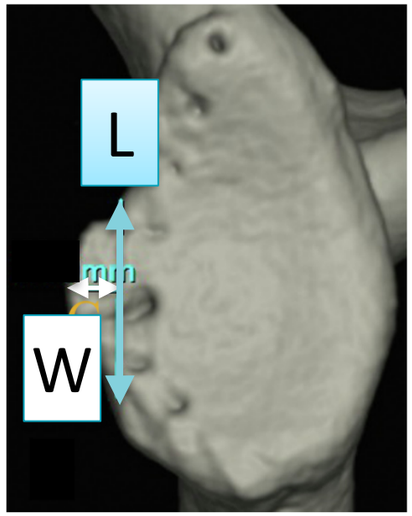

6. Nakagawa S, et al. JSES. 2023

4. new bone formation

L: the original anterior margin of the glenoid defect(mm) (**length**)

W: **width** of the new bone formation (mm)

Results

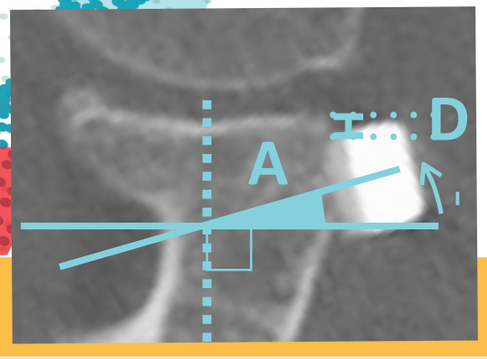

1. position/inclination angle of the artificial bone

	immediate	final	
D: Distance (mm); mean±SD (median, range)	0.3 ± 1.6 (0.0, -3.8~2.9)	1.8 ± 1.4 (1.4, -0.8~4.5)	*
A: angle (˚); mean±SD (median, range)	27.7 ± 18.1 (27.1, -4.9~55.2)	17.4 ± 17.4 (17.5, -11.2~47.1)	*

Statistical analysis: paired t-test,
*: significant difference; $p<0.05$

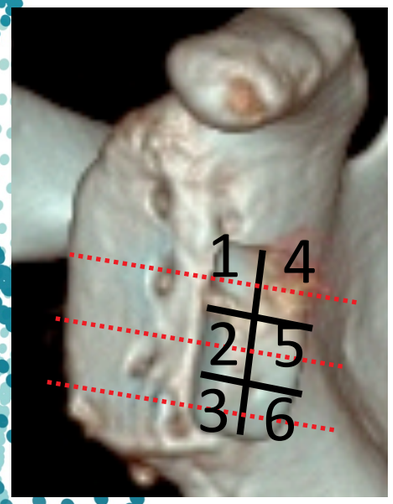

2. bony fusion status

1	2	3	4	5	6
80.6%	**93.6%**	87.1%	51.6%	61.3%	77.4%

Results

3. resorption of artificial bone or glenoid bone	0%

4. new bone formation

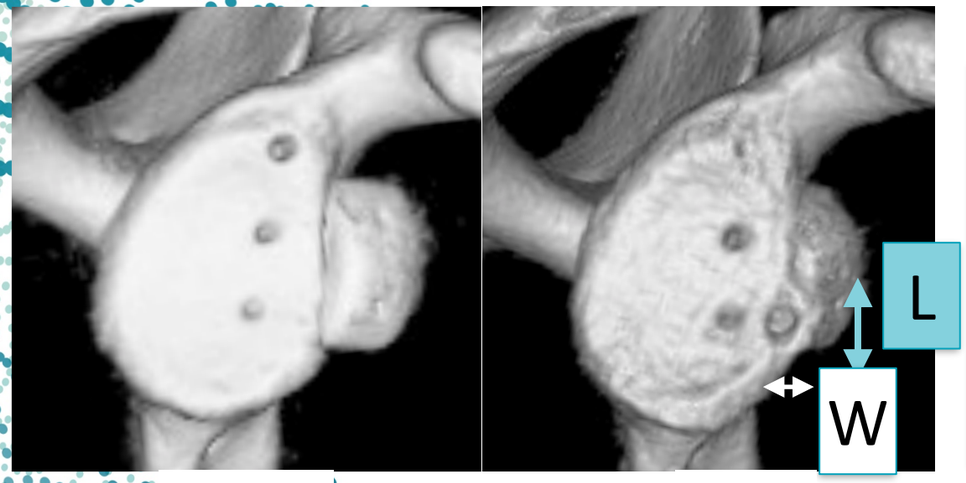

initial final

appearance rate	77.4% (24/31)
L: Length (mm); mean±SD (median, range)	8.9 ± 7.1 (6.2, 0.0-25.4)
W: Width (mm); mean±SD (median, range)	2.2 ± 1.6 (1.8, 0.0-4.9)

Discussions

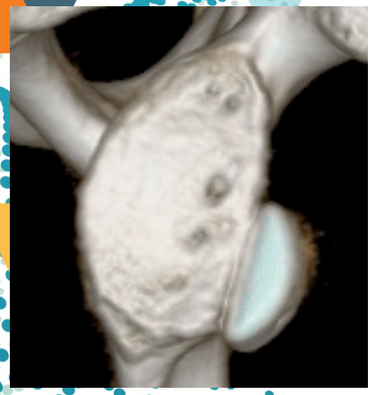

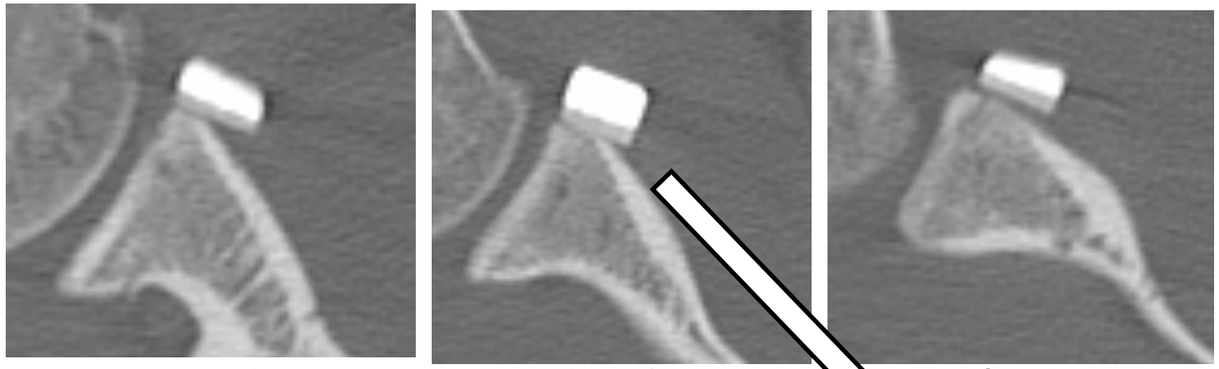

superior middle inferior

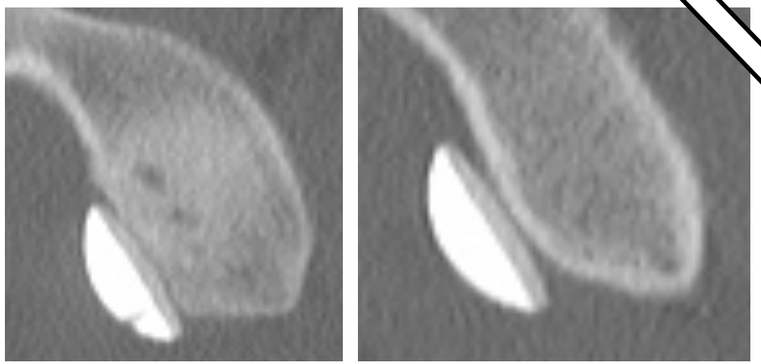

lateral medial

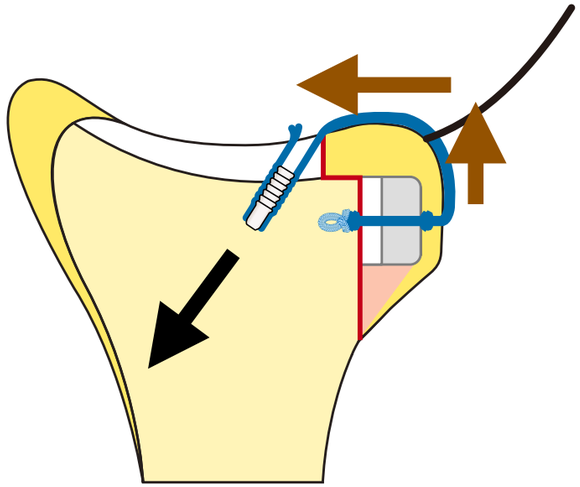

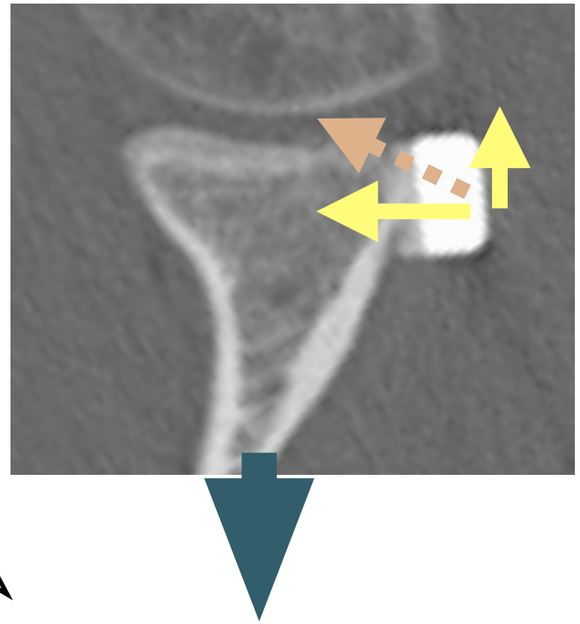

Bone fusion rate increased
in the lateral (glenoid side) and middle part

New bone formation on the glenoid

50y male

33y female

21y male

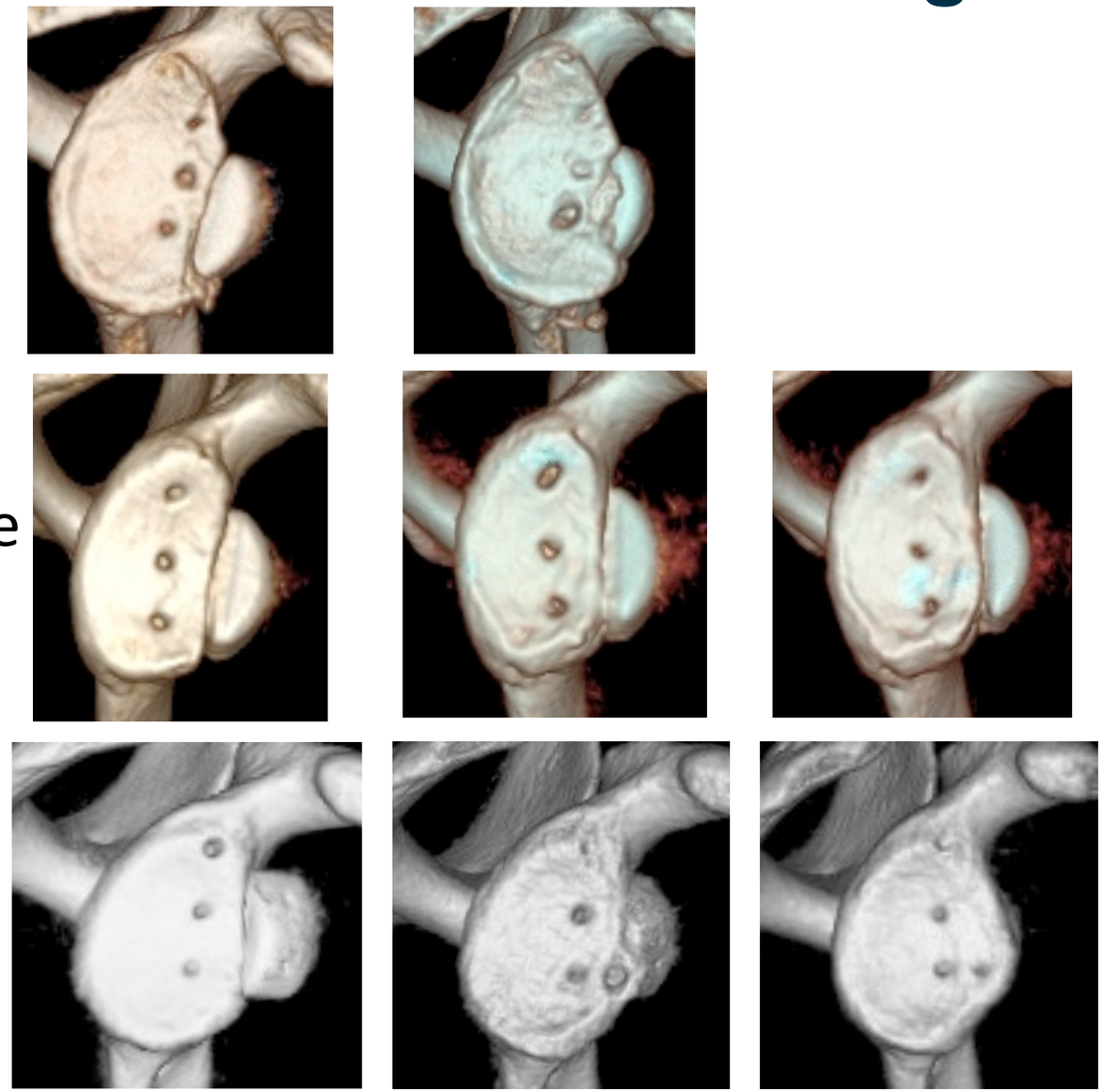

post-op immediate 12 months 24 months

related to

osteocyte attached to caspuloligamentous complex?

osteoconductivity of artificial bone?

time after primary dislocation?

age?

sex?

?

Conclusions

- The bony union and response after artificial bone graft augmentation for arthroscopic Bankart repair were evaluated using CT images.
- After artificial bone graft augmentation for arthroscopic Bankart repair using JuggerKnot and Gryphon BR, some cases were shifted the artificial bone, bone union was observed in 93.5% of the cases.
- New bone formation was observed in 77.4% of the cases as if the glenoid had been enlarged which was considered to be remodeling.

Reference

1. Burkhart SS, De Beer JF1. Traumatic glenohumeral bone defects and their relationship to failure of arthroscopic Bankart repairs: significance of the inverted-pear glenoid and the humeral engaging Hill-Sachs lesion. Arthroscopy. 2000;16(7):677-694.

2. Randelli P, Ragone V, Carminati S, et al. Risk factors for recurrence after Bankart repair a systematic review. Knee Surg Sports Traumatol Arthrosc. 2012;20:2129–2138.

3. Iizawa N, Yoneda M, Yamada S, et al. Benefits of bone graft augmentation to arthroscopic Bankart repair for recurrent anterior shoulder instability with glenoid bone loss. Knee Surg Sports Traumatol Arthrosc. 2020;28:2325–2333.

4. Kanno Y, Nakatsuka T, Saijo H, et al. Computed tomographic evaluation of novel custom-made artificial bones, “CT-bone”, applied for maxillofacial reconstruction. Regenerative Therapy. 2016;5:1-8.

5. Iizawa N, Yoneda M, Shirao H, et al. CT assessments of bony union and response after artificial bone graft augmentation for arthroscopic Bankart repair. The Shoulder Joint. 2022;46:58-62. (Article In Japanese)

6. Nakagawa S, Hirose T, Ohori T, et al. New bone formation after arthroscopic Bankart repair for unstable shoulders with an erosion-type glenoid defect. J Shoulder Elbow Surg. 2023;32:9-16.