ISAKOS CONGRESS 2025 | MUNICH GERMANY June 8–11

Change of joint line convergence angle and other coronal alignments after total hip arthroplasty

Yun Seong Choi, Seung Hoon Lee

Veterans Health Service Medical Center, Seoul, South Korea

Disclosures:

The authors have no conflicts of interest to declare.

Introduction

- Total hip arthroplasty (THA) may have unloading effect on knee because THA can change coronal alignments.

- Joint line convergence angle (JLCA) can represent unloading effect because it can change depending on loading axis.
  - *As joint-loading axis is moved from medial to lateral compartment, JLCA could change in direction of closing joint lateral space*

- After THA, change of parameters such as JLCA, HKA, MPTA, LDFA remain unclear.

- Sensitivity of JLCA in THA may differ from that of LDFA, MPTA, HKA due to nature of JLCA, which primarily reflects soft tissue.

Kocabiyik A, J Arthroplasty, 2017

Ollivier M, OTSR, 2013

Ogawa H, AOTS, 2016

Oh KJ, J Knee surg, 2016

Purpose & Hypothesis

❖Purpose

- To determine unloading effect of THA on ipsilateral knee joint through JLCA change
- To determine changes in other coronal radiographic parameters after THA
- To evaluate sensitivity of JLCA

❖Hypothesis

- THA would have unloading effect on medial compartment of knee joint and JLCA would be more susceptible to change after THA than other coronal alignments.

Materials and Methods
- Study cohort

THA from April 2016
to August 2022 (n = 281)

Inclusion Criteria
(1) Standing full-lower limb AP radiographs
before and 1 year after THA
(2) Available radiographs (patellar facing forward)

Case (n = 144)

Exclusion Criteria
(1) History of lower extremity surgeries (n = 45)
(2) Deformity of lower extremity (n = 2)
(3) KL IV or ankylosis condition of knee and ankle joint (n = 2)
(4) Postoperative complication (infection, fracture) (n = 2)
(5) Pathologic condition of contralateral hip joint (n = 23)

Eligible case (n = 70)

- **Male : 50, female : 20**
- **Age (year): 67±9.4 (38-88)**
- **BMI : 24.7±3.3 (17.9-34.2)**

Radiographic examination

Hip parameters

- Neck shaft angle (NSA)
- Neck length (NL)
- Femoral offset (FO)

Coronal alignment parameters

- Hip knee ankle angle (HKA)
- Femur length (FL)
- Lateral distal femoral angle (mLDFA)
- JLCA
- Medial proximal tibial angle (MPTA)
- Lateral distal tibial angle (LDTA)
- Plafond talus angle (PTA)

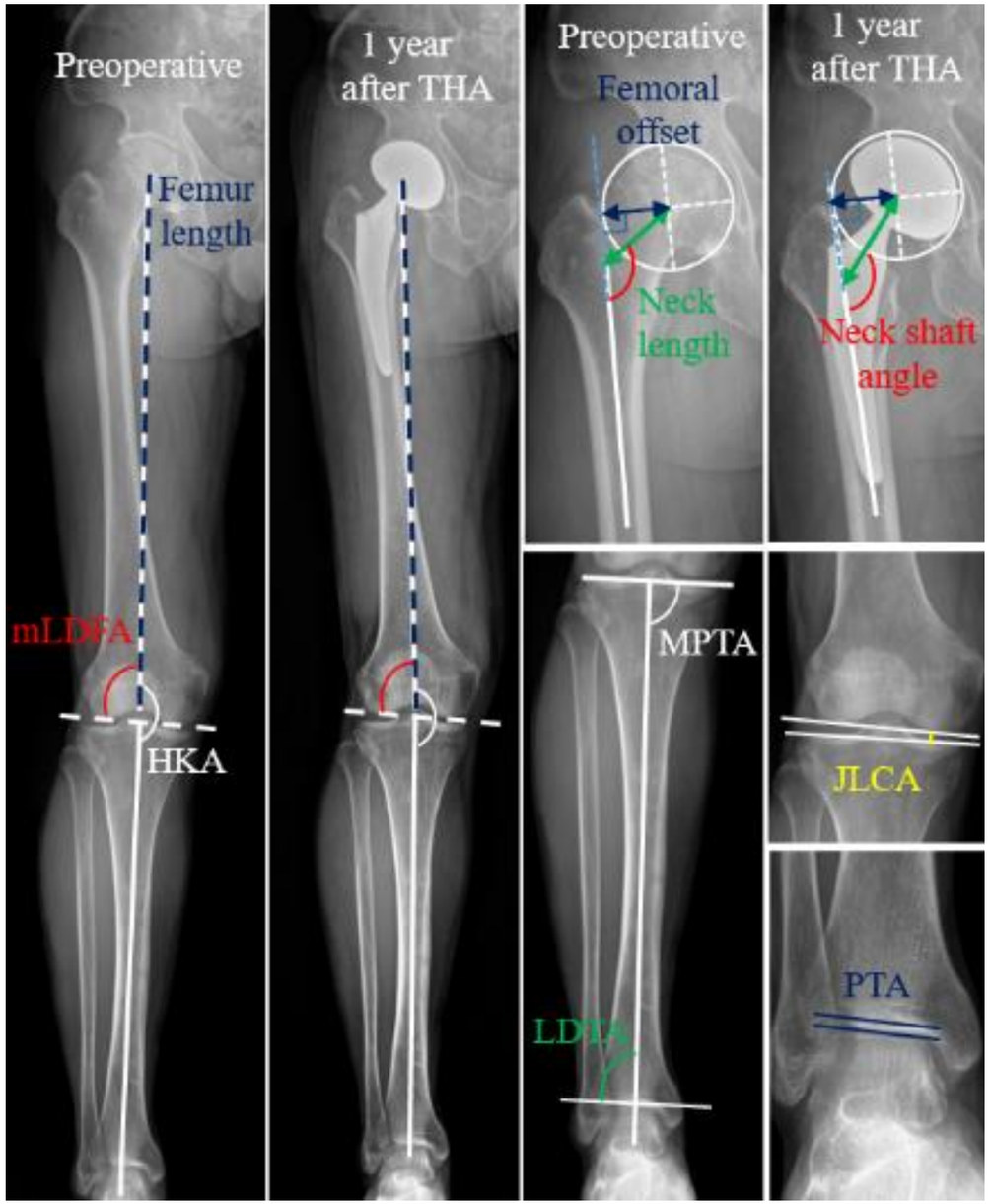

Data analysis

- **To determine unloading effect of THA on ipsilateral knee joint**
  - JLCA (Preoperative vs 1 year after TJA)

- **To determine changes in other coronal radiographic parameters after THA**
  - NSA, femoral offset, neck length, HKA, femur length, mLDFA, MPTA, LDTA, and PTA (Preoperative vs 1 year after TJA)

- **To evaluate the sensitivity of JLCA**
  - Amount of changes in each radiographic parameter was standardized
  - Standardized changes (Δ) (all hip vs coronal alignment parameters)

Results ; *change of radiographic parameters after THA*

Table 2. Changes in radiographic parameters of the operative and non-operative sides after THA

Radiographic parameter	Operative side			Non-operative side		
	Preoperative	1 year after THA	*P* value	Preoperative	1 year after THA	*P* value
Hip parameter						
NSA(°)	129.39 ± 5.46	133.54 ± 4.63	<0.001	128.41 ± 3.94	128.31 ± 4.04	0.599
Femoral offset(mm)	36.45 ± 7.00	39.85 ± 6.94	<0.001	39.94 ± 4.93	40.32 ± 5.68	0.296
Neck length(mm)	47.83 ± 9.34	55.06 ± 7.34	<0.001	51.45 ± 6.42	51.76 ± 7.08	0.485
lower extremity coronal alignment parameter						
HKA(°)	2.62 ± 3.41	1.53 ± 3.19	<0.001	2.80 ± 3.40	3.11 ± 3.31	0.070
Femur length(mm)	429.20 ± 29.48	436.33 ± 28.12	<0.001	432.89 ± 26.56	433.79 ± 27.64	0.124
mLDFA(°)	86.69 ± 2.32	85.91 ± 2.38	<0.001	87.06 ± 2.23	87.08 ± 2.05	0.904
JLCA(°)	1.81 ± 1.39	1.22 ± 1.19	<0.001	1.54 ± 1.35	1.57 ± 1.41	0.814
MPTA(°)	85.43 ± 2.39	86.73 ± 2.38	<0.001	86.21 ± 2.33	85.95 ± 2.35	0.073
LDTA(°)	87.50 ± 3.85	90.38 ± 3.19	<0.001	90.30 ± 3.17	89.84 ± 3.10	0.080
PTA(°)	0.47 ± 1.70	0.11 ± 1.42	0.046	0.22 ± 1.32	0.29 ± 1.56	0.697

THA, total hip arthroplasty; NSA, neck shaft angle; HKA, hip-knee-ankle angle; mLDFA, mechanical lateral distal femoral angle; JLCA, joint line convergence angle; MPTA, medial proximal tibial angle; LDTA, lateral distal tibial angle; PTA, plafond talus angle

❖**THA had an unloading effect on the medial compartment of ipsilateral knee joint!!**

Results ; *sensitivity of JLCA*

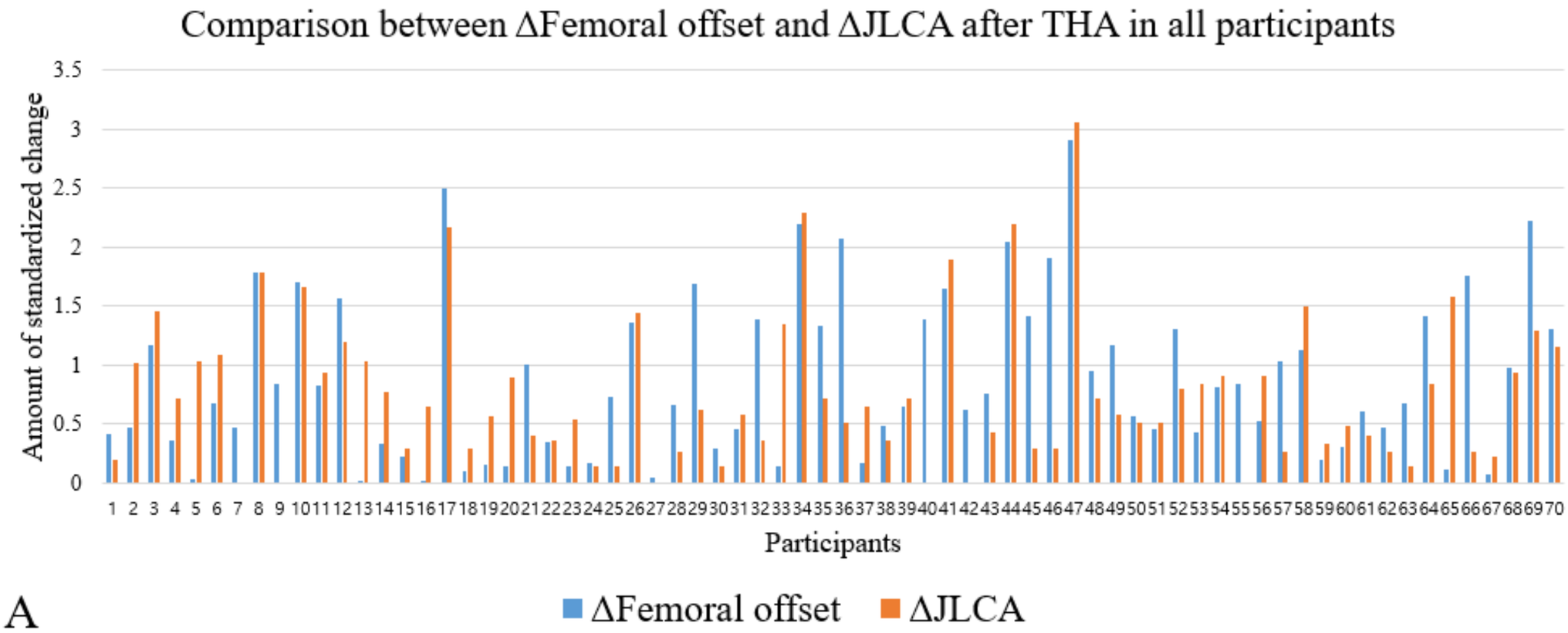

A

❖JLCA was more susceptible to change after THA than other coronal alignments

ISAKOS CONGRESS 2025 | MUNICH GERMANY June 8–11

Results ; *sensitivity of JLCA*

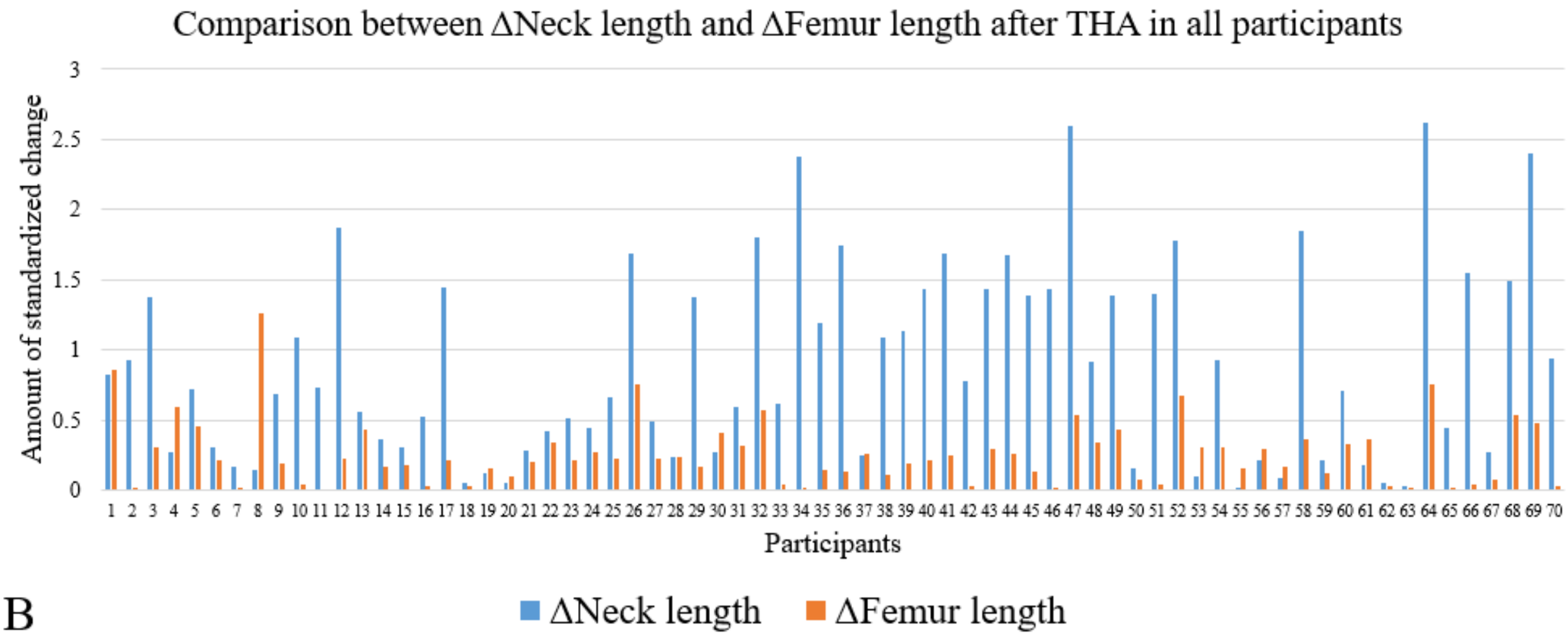

B

❖JLCA was more susceptible to change after THA than other coronal alignments

ISAKOS CONGRESS 2025 | MUNICH GERMANY June 8–11

Results ; *sensitivity of JLCA*

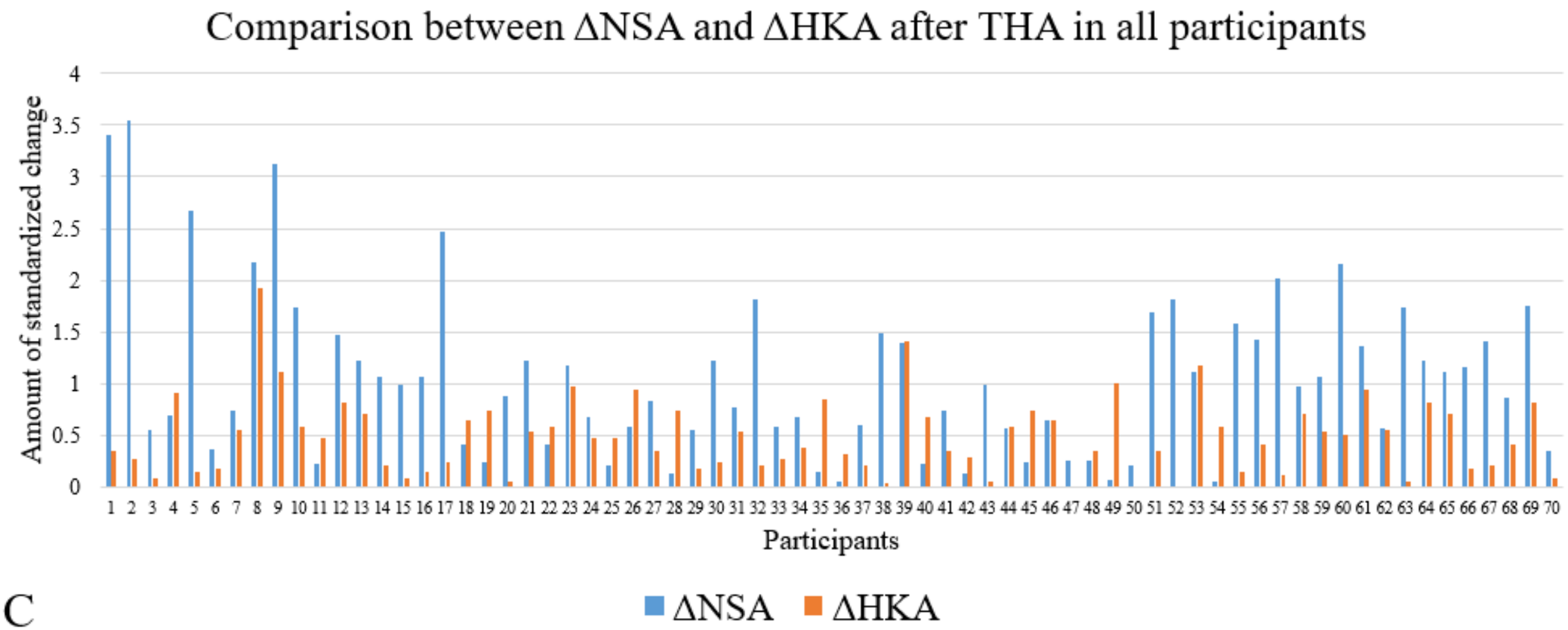

C

❖JLCA was more susceptible to change after THA than other coronal alignments

ISAKOS CONGRESS 2025 | MUNICH GERMANY June 8–11

Summary

- According to the cohort, THA had unloading effect on medial compartment of ipsilateral knee joint.
- All coronal radiographic parameters on the operative side changed significantly after THA.
- JLCA was more vulnerable to change than HKA, femur length, mLDFA, MPTA, and PTA.

Reference

- [1] Fujita T, Hamai S, Shiomoto K, Okazawa K, Nasu YK, Hara D, et al. Analysis of factors influencing patient satisfaction after total hip arthroplasty in a Japanese cohort: the significant effect of postoperative physical activity. J Phys Ther Sci 2022;34(2):76-84.
- [2] Merschin D, Häne R, Tohidnezhad M, Pufe T, Drescher W. Bone-preserving total hip arthroplasty in avascular necrosis of the hip-a matched-pairs analysis. Int Orthop 2018;42(7):1509-16.
- [3] Shon WY, Park BY, R RN, Park PS, Im JT, Yun HH. Total Hip Arthroplasty: Past, Present, and Future. What Has Been Achieved? Hip Pelvis 2019;31(4):179-89.
- [4] Dargel J, Oppermann J, Brüggemann GP, Eysel P. Dislocation following total hip replacement. Dtsch Arztebl Int 2014;111(51-52):884-90.
- [5] Kocabiyik A, Misir A, Kizkapan TB, Yildiz KI, Kaygusuz MA, Alpay Y, et al. Changes in Hip, Knee, and Ankle Coronal Alignments After Total Hip Arthroplasty With Transverse Femoral Shortening Osteotomy for Unilateral Crowe Type IV Developmental Dysplasia of the Hip. J Arthroplasty 2017;32(11):3449-56.
- [6] Ollivier M, Parratte S, Lecoz L, Flecher X, Argenson JN. Relation between lower extremity alignment and proximal femur anatomy. Parameters during total hip arthroplasty. Orthop Traumatol Surg Res 2013;99(5):493-500.
- [7] Ogawa H, Matsumoto K, Ogawa T, Takeuchi K, Akiyama H. Preoperative varus laxity correlates with overcorrection in medial opening wedge high tibial osteotomy. Arch Orthop Trauma Surg 2016;136(10):1337-42.
- [8] Oh KJ, Ko YB, Bae JH, Yoon ST, Kim JG. Analysis of Knee Joint Line Obliquity after High Tibial Osteotomy. J Knee Surg 2016;29(8):649-57.
- [9] Shin YS, Kim KH, Sim HB, Yoon JR. Comparison between two angular stable locking plates for medial opening-wedge high tibial osteotomy: Decisive wedge locking plate versus TomoFix™. J Orthop Sci 2016;21(6):791-7.
- [10] Umeda N, Miki H, Nishii T, Yoshikawa H, Sugano N. Progression of osteoarthritis of the knee after unilateral total hip arthroplasty: minimum 10-year follow-up study. Arch Orthop Trauma Surg 2009;129(2):149-54.
- [11] van Drongelen S, Kaldowski H, Tarhan T, Assi A, Meurer A, Stief F. Are changes in radiological leg alignment and femoral parameters after total hip replacement responsible for joint loading during gait? BMC Musculoskelet Disord 2019;20(1):526.
- [12] Choi YS, Park JW, Kim TW, Kang KS, Lee YK, Koo KH, et al. Effect of Total Hip Arthroplasty on Ipsilateral Lower Limb Alignment and Knee Joint Space Width: Minimum 5-Year Follow-up. J Korean Med Sci 2023;38(20):e148.
- [13] Heijens E, Kornherr P, Meister C. The coronal hypomochlion: a tipping point of clinical relevance when planning valgus producing high tibial osteotomies. Bone Joint J 2016;98-b(5):628-33.
- [14] Micicoi G, Khakha R, Kley K, Wilson A, Cerciello S, Ollivier M. Managing intra-articular deformity in high Tibial osteotomy: a narrative review. J Exp Orthop 2020;7(1):65.
- [15] Wei M, Kang H, Hao K, Fan C, Li S, Wang X, et al. Increased lower limb length ratio in patients with patellar instability. J Orthop Surg Res 2023;18(1):221.
- [16] Ramazanian T, Yan S, Rouzrokh P, Wyles CC, TJ OB, Taunton MJ, et al. Distribution and Correlates of Hip-Knee-Ankle Angle in Early Osteoarthritis and Preoperative Total Knee Arthroplasty Patients. J Arthroplasty 2022;37(6s):S170-s5.
- [17] Chang CB, Chung CY, Park MS, Choi JH, Kim JS, Lee KM. Aggravation of Ankle Varus Incongruency Following Total Knee Replacement Correcting ≥10° of Genu Varum Deformity: A Radiographic Assessment. J Arthroplasty 2020;35(11):3305-10.
- [18] Flandry F, Hommel G. Normal anatomy and biomechanics of the knee. Sports Med Arthrosc Rev 2011;19(2):82-92.
- [19] Brockett CL, Chapman GJ. Biomechanics of the ankle. Orthopaedics and trauma 2016;30(3):232-8.
- [20] Hendren L, Beeson P. A review of the differences between normal and osteoarthritis articular cartilage in human knee and ankle joints. Foot (Edinb) 2009;19(3):171-6.