Quantitative assessment of knee joint kinematics in patients with recurrent patellar dislocation – using a 3D-3D surface registration technique and 4-D CT analysis –

Kazuya Kaneda[1], Kengo Harato[1,2], Satoshi Oki[1], Yutaro Morishige[1], Shu Kobayashi[1], Yasuo Niki[1,3], Tatsuaki Matsumoto[1], Masaya Nakamura[1], Takeo Nagura[1]

1 Department of Orthopaedic Surgery, Keio University School Medicine

2 Sports Medicine Research Center, Keio University

3 Department of Orthopaedic Surgery, Fujita Medical Innovation Center

COI

Presenter : Kazuya Kaneda, M.D., Ph.D.

There are no companies or entities that the presenters need to disclose any COI relationships with, related to the content of the presentation.

Background

Four-dimensional computed tomography (4DCT)

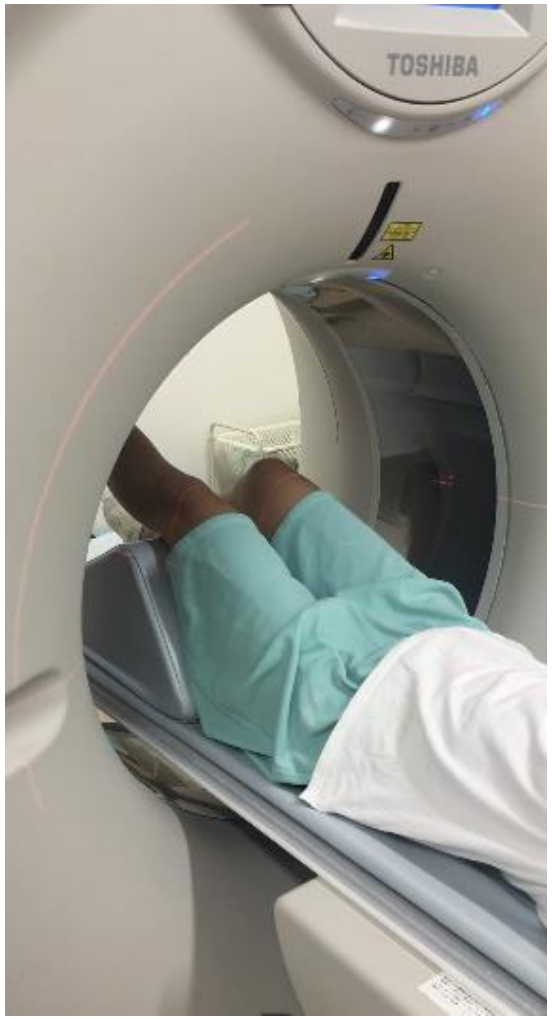

- **Type of CT scanning which records multiple images over time**

Capture the dynamic motion

FOV, Image quality

Purpose

Recurrent patellar dislocation (RPD)

- MPFL injury
- Dysplasia of trochlea groove
- Joint laxity
- Patella alta
- Malalignment (TT-TG↑)
- Etc.

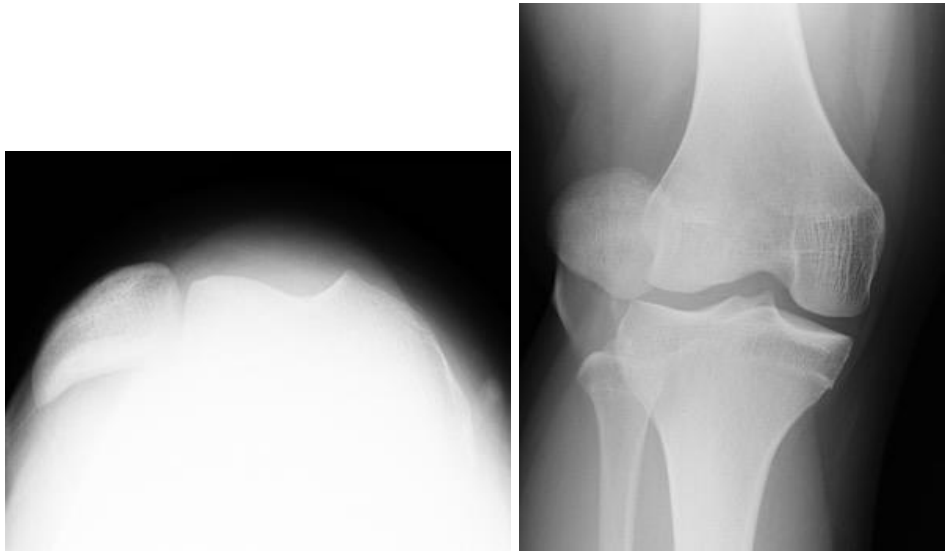

- Investigate the 3D knee kinematic changes in patients with RPD using 4DCT and surface registration technique

Materials & Method

Approved by our ethical committee (#20150127)

Materials

Recurrent patellar dislocation （Group D）

10 disease side knees of 9 RPD patients

(1 male, 9 female; mean age 25.8±10.5yrs)

Control （Group C）

7 intact side knees of 7 ACL injury patients

(2 males, 5 females; mean age 32.6±10.5yrs)

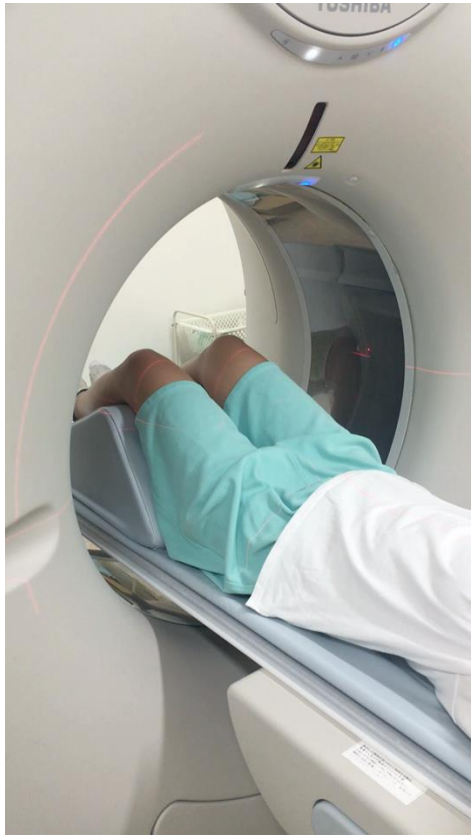

CT scan

①static whole legs CT

②knee joint 4 DCT

- ✓ Aquilion ONE 320-slice CT
- ✓ 5 frames/sec
- ✓ Extend knee joint 60 degrees to 0 degrees by themselves
- ✓ 10seconds 50 frames

Methods

3D-3DSurface registration

4 DCT

+



Static CT

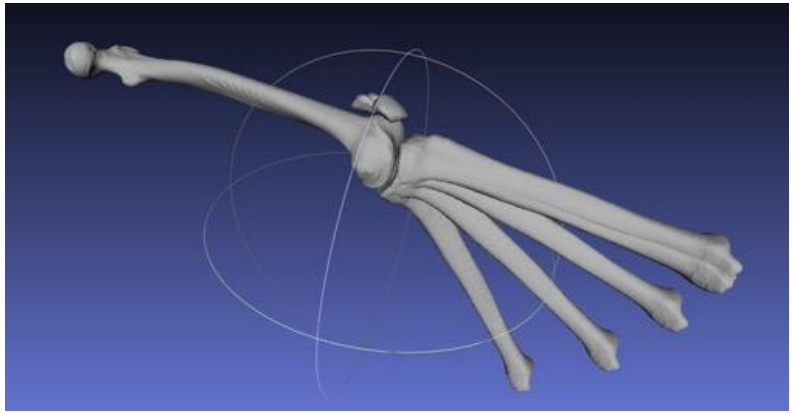

Whole leg 4 DCT

- Coordinating system
  femur and tibia T Sato, Y Koga et al. 2004 J Arthroplasty
  Patella Y Yamada, Y Toritsuka et al. 2017 AJSM
- Evaluate two below angles
  ①Patella tilting angle relative to the femur
  ②Tibia external rotation angle relative to the femur

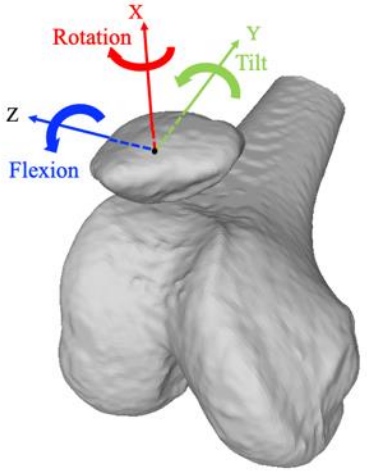

Result: Patellar rotation angle

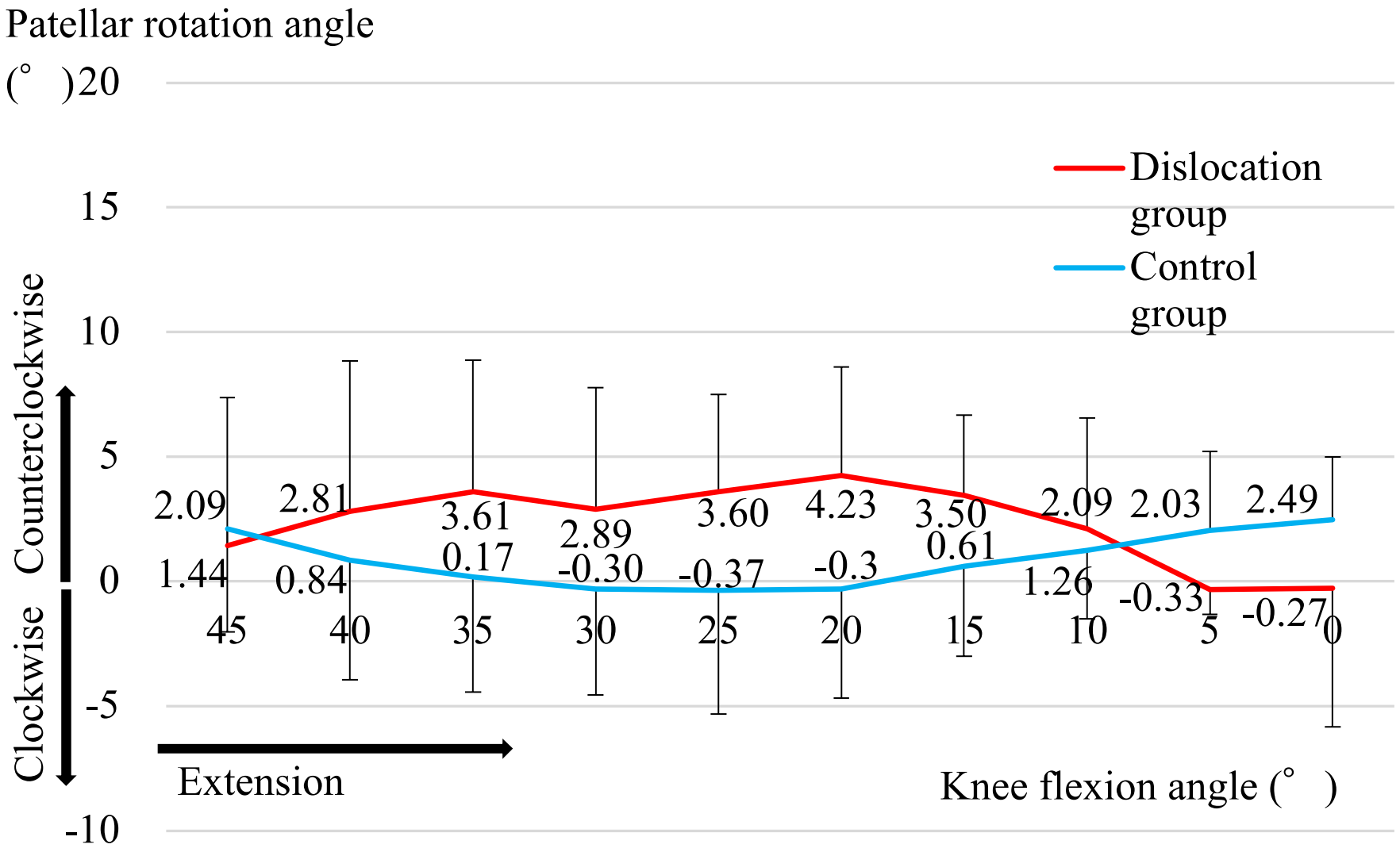

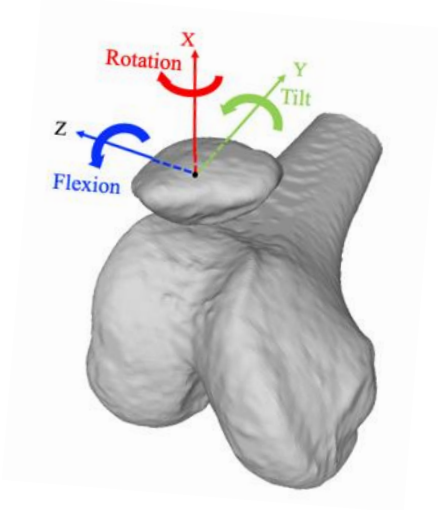

<Kaneda K, et al. Skeletal Radiol. 2024>

Result: Patellar titling angle

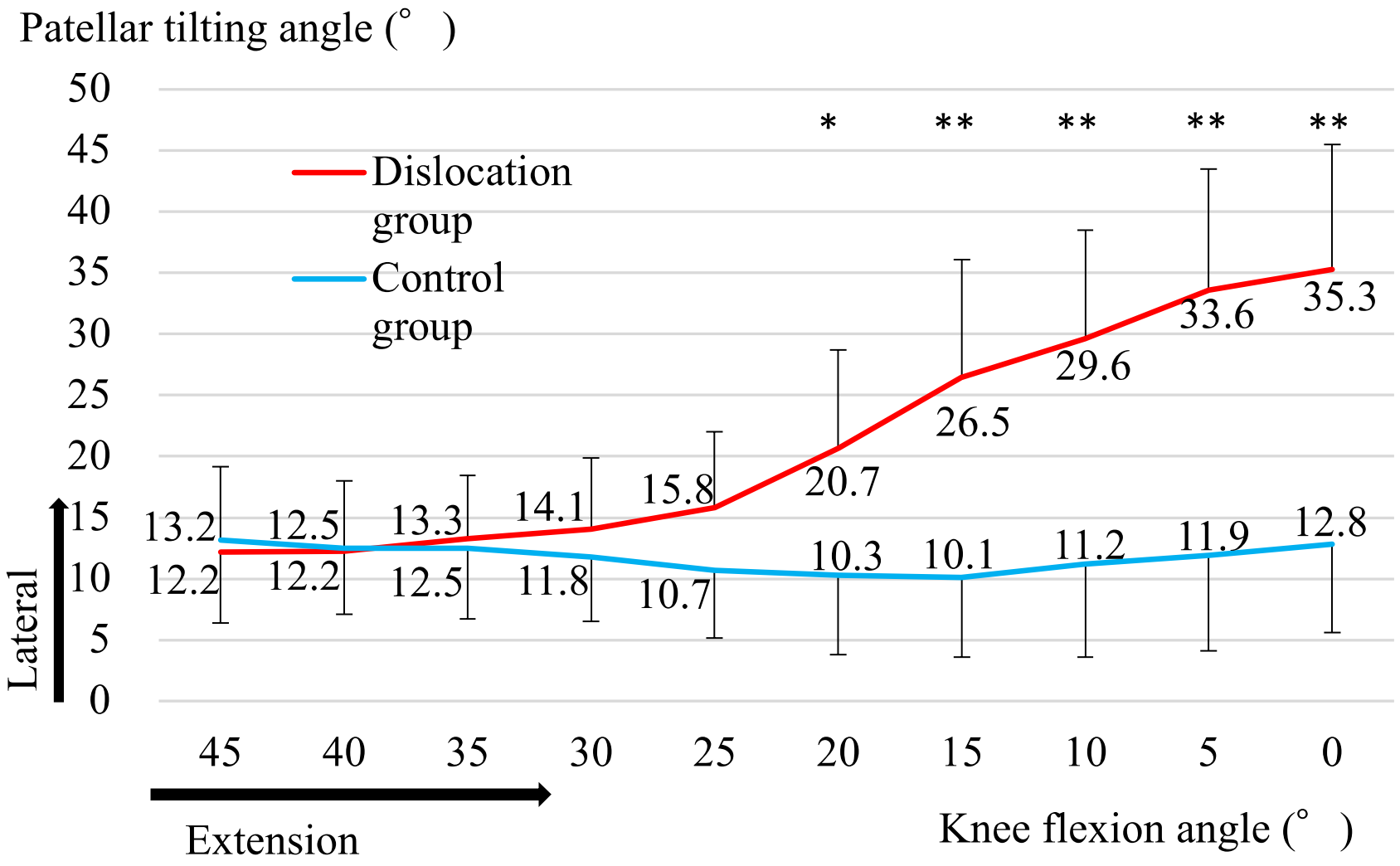

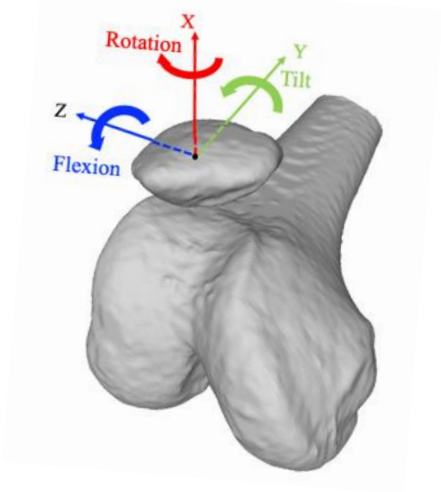

<Kaneda K, et al. Skeletal Radiol. 2024>

Result: Patellar flexion angle

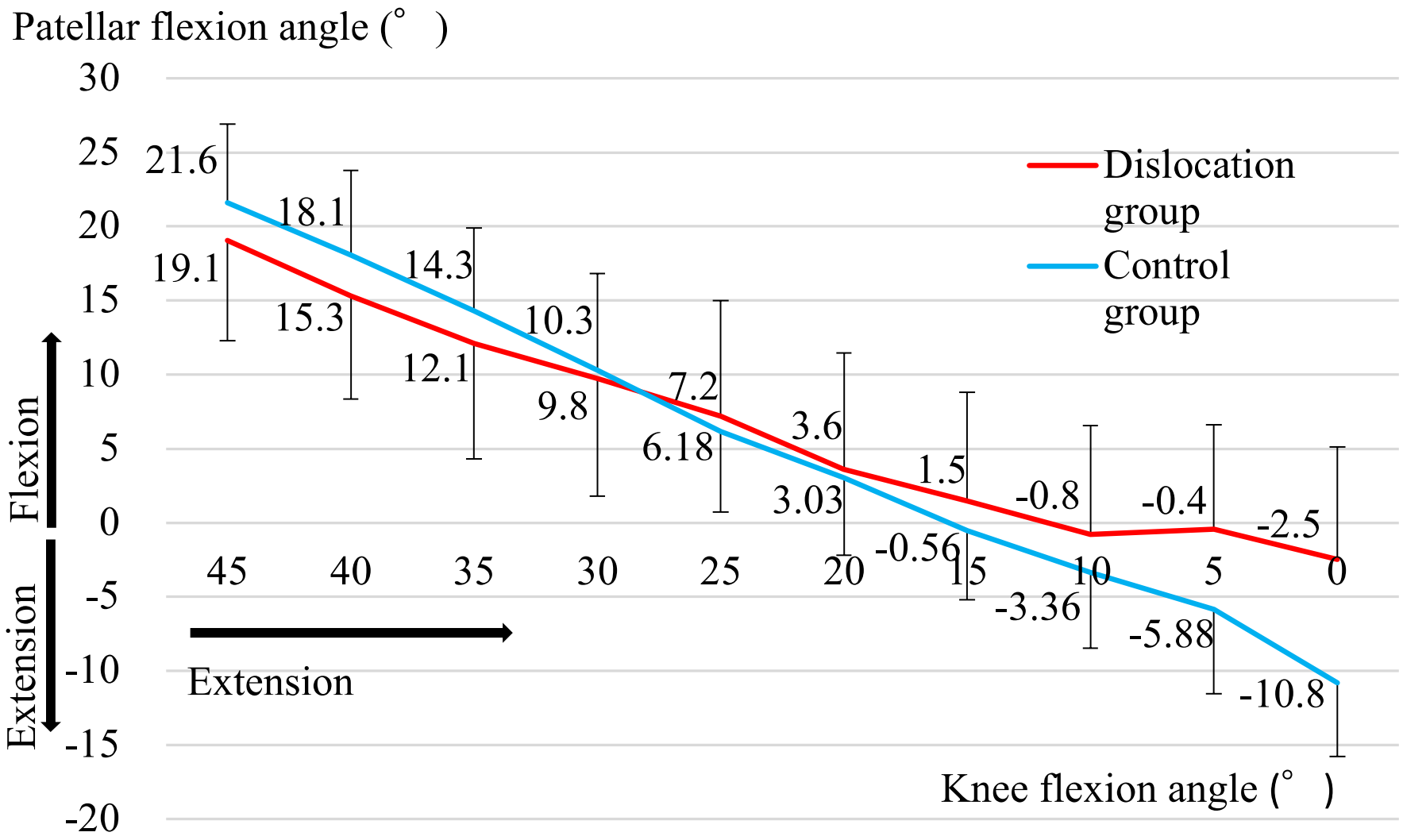

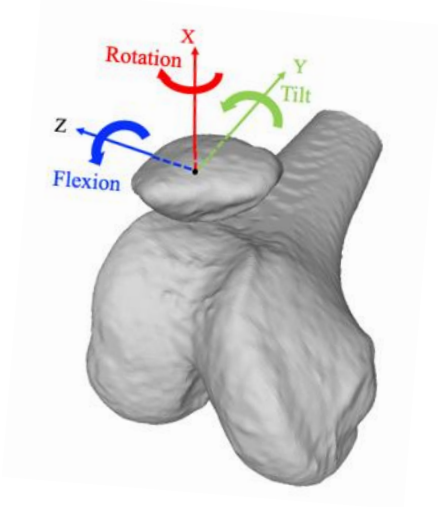

<Kaneda K, et al. Skeletal Radiol. 2024>

Result: Tibial rotation angle

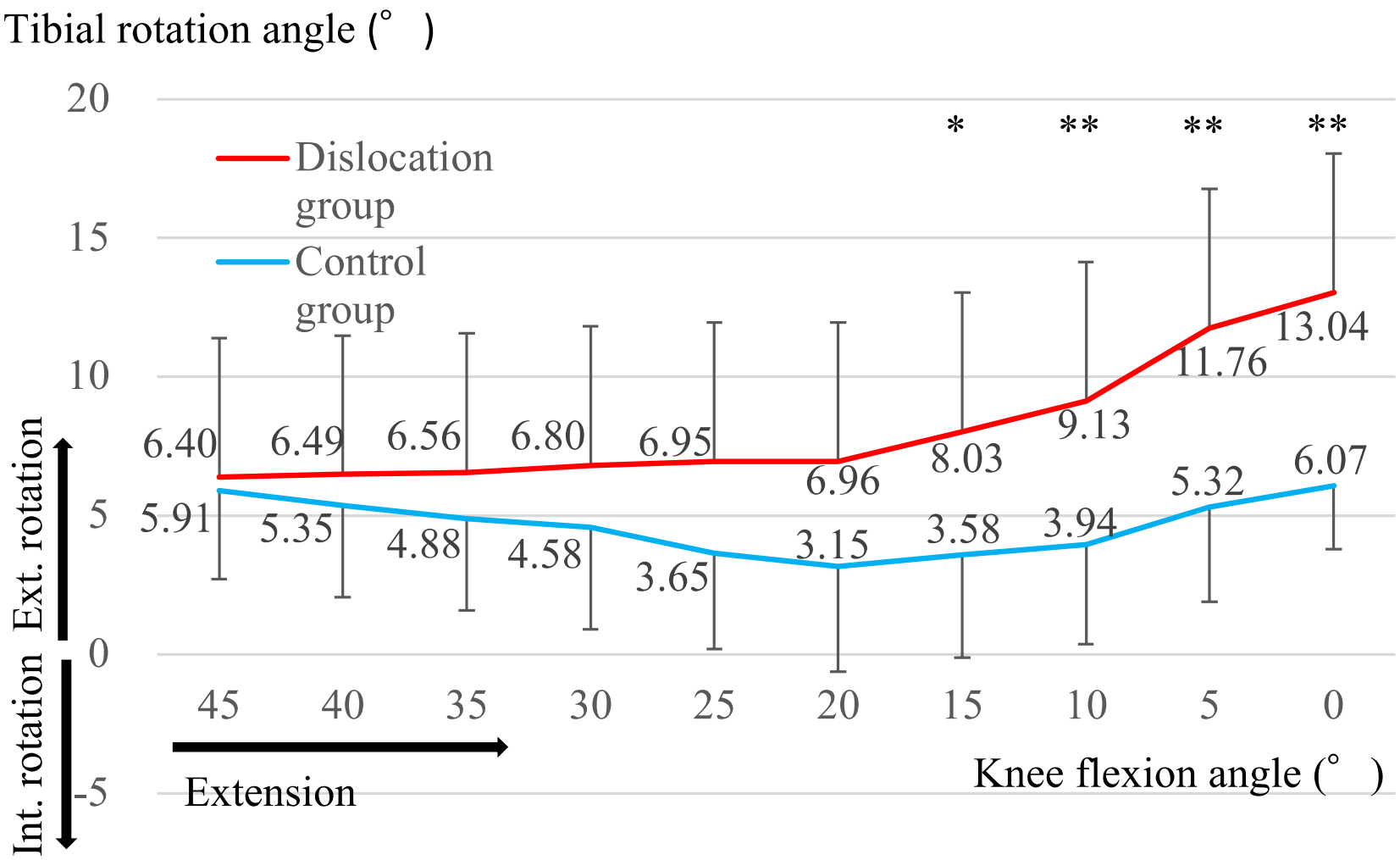

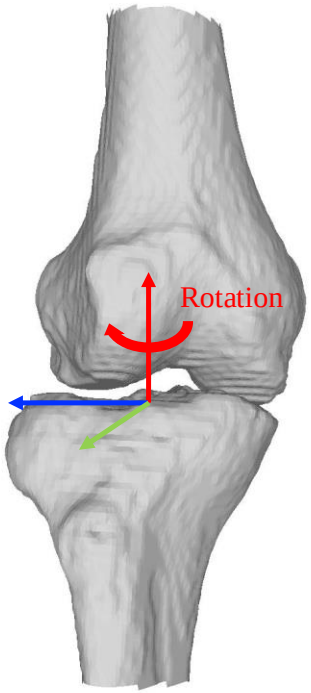

<Kaneda K, et al. Skeletal Radiol. 2024>

Past studies : Patella kinematics

Knee joint MRI every 10° ; 0°-50°
Evaluate patella motion on 3D model

3D Shift and 3D Tilt at 0° to 50° of Knee Flexion[a]

Static vs Dynamic

Patients	0°	10°	20°	30°	40°	50°	Range
				exion Angle			
RDP							
3D shift, %	20.5 ± 7.0				12.1 ± 9.6	11.9 ± 9.8	12.7 ± 6.3 (4.1-36.4)
3D tilt, deg	22.7 ± 8.8				14.1 ± 10.0	13.7 ± 10.3	13.1 ± 6.5 (1.3-33.9)
HV							
3D shift, %	9.5 ± 4.5				4.9 ± 4.9	5.4 ± 4.6	5.5 ± 2.8 (1.6-10.7)
3D tilt, deg	6.8 ± 6.6				4.2 ± 6.2	4.7 ± 5.9	4.5 ± 2.8 (1.4-12.4)

[a]For every column, $P < .01$ (Mann-Whitney U test). Values are presented as mean ± SD. HV, healthy volunteers; RDP, recurrent dislocation of the patella; 3D, 3-dimensional.

This study
RPD 35.3 ± 10.2°
Healthy 12.8 ± 7.2°

At all angles, the tilt in RPD patients was significantly greater than that in normal subjects.

<Yamada Y, Toritsuka Y, et al. AJSM 2017>

Patella tilt and tibia rotation

Patella dislocation

How the MPFL reconstruction affects?

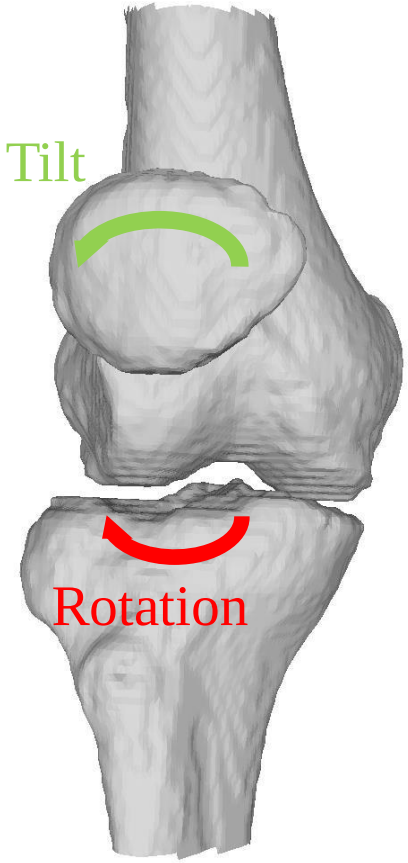

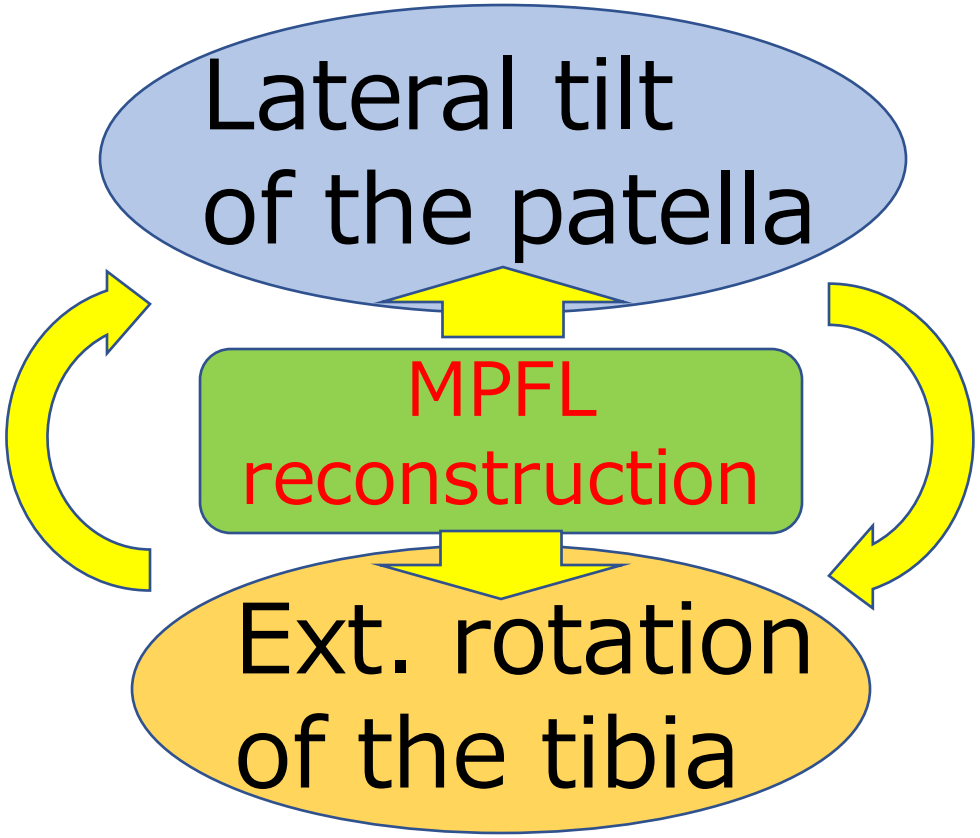

Conclusion

- We evaluated knee kinematics using 4DCT
- The lateral patellar tilt was greater in the dislocation group when the knee was in the extended position than when it was flexed at 20°.
- Tibial external rotation was greater in the dislocation group when the knee was in extension than when it was flexed at 15°.