ISAKOS CONGRESS 2025 | MUNICH GERMANY June 8–11

Pure Distalization Tibial Tubercle Osteotomy Does Not Result in Posteriorization of the Tibial Tubercle

Nathan H. Varady, MD/MBA, Nicolas Pascual-Leone, MD, Ava Neijna, BA, Andreas H. Gomoll, MD, Sabrina M. Strickland, MD

Department of Sports Medicine, Hospital for Special Surgery, New York, NY

Faculty Disclosure Information

- Our disclosure(s) are:
- A.H.G. has received speaking fees from Bio-ventus and Organogenesis; research support from Cartiheal, JRF, Moximed, Organogenesis, and Vericel; consulting fees from JRF, Moximed, Smith & Nephew, Flexion Therapeutics, and Vericel; nonconsulting fees from Linvatec and Pacira Pharmaceuticals; honoraria from Fidia Pharma; and royalties from Organogensis; he also holds stock or stock options in Engage and Stryker.

- S.M.S. has received consulting fees from Smith & Nephew, Miach, Vericel,and Flexion Therapeutics; research support from Miach and Vericel; and honoraria from JRF; she also holds stock or stock options in Engage and Stryker.

Pure Distalization Tibial Tubercle Osteotomy Does Not Result in Posteriorization of the Tibial Tubercle

Nathan H. Varady, MD/MBA, Nicolas Pascual-Leone, MD, Ava Neijna, BA, Andreas H. Gomoll, MD, Sabrina M. Strickland, MD

Department of Sports Medicine, Hospital for Special Surgery, New York, NY

No disclosures related to this work. Additional disclosures on the AAOS website.

Introduction

- ***Background:*** Pure distalization tibial tubercle osteotomy (TTO-d) may be beneficial for certain patients with recurrent patellar instability or chondral wear
- ***Problem:*** Theoretical concerns that TTO-d may posteriorize the tibial tubercle and thus increase patellofemoral contact pressures; whether this posteriorization actually occurs, however, has never been investigated
- ***Goal:*** Assess the relative amount of anteriorization or posteriorization that occurs following TTO-d

Methods

- ***Design***: Consecutive TTO-ds from two surgeons from 2015-2023 that had both pre- and postoperative lateral XRs
- ***Measurement*** Performed by two physician raters using a previously MRI-validated technique. In brief, the distance from the most anterior aspect of the tibial tubercle to the center of the anatomic axis of the tibia was measured pre- and postoperatively, with the difference in these values representing the amount of anteriorization or posteriorization (**Figure 1**)
- ***Statistics***: Pre- and postoperative measurements were compared with Student t-tests, and the average and median amount of anteriorization/posteriorization was calculated
- Change in Caton-Deschamps Index (CDI) and agreement (using Intraclass Correlation Coefficients [ICC]) were also assessed

Discussion / Conclusions

- Pure distalization TTOs can be performed without appreciable posteriorization of the tibial tubercle
- These results support the positive clinical outcomes seen with TTO-ds, including for chondral lesions, and may reduce concern about inadvertent posteriorization when performing TTO-ds
- While over distalization with creation of patella baja has been shown to increase patellofemoral contact pressures beyond native ranges, the current results suggest that restoration of normal patellar height may be less likely to do so

Measurement Technique

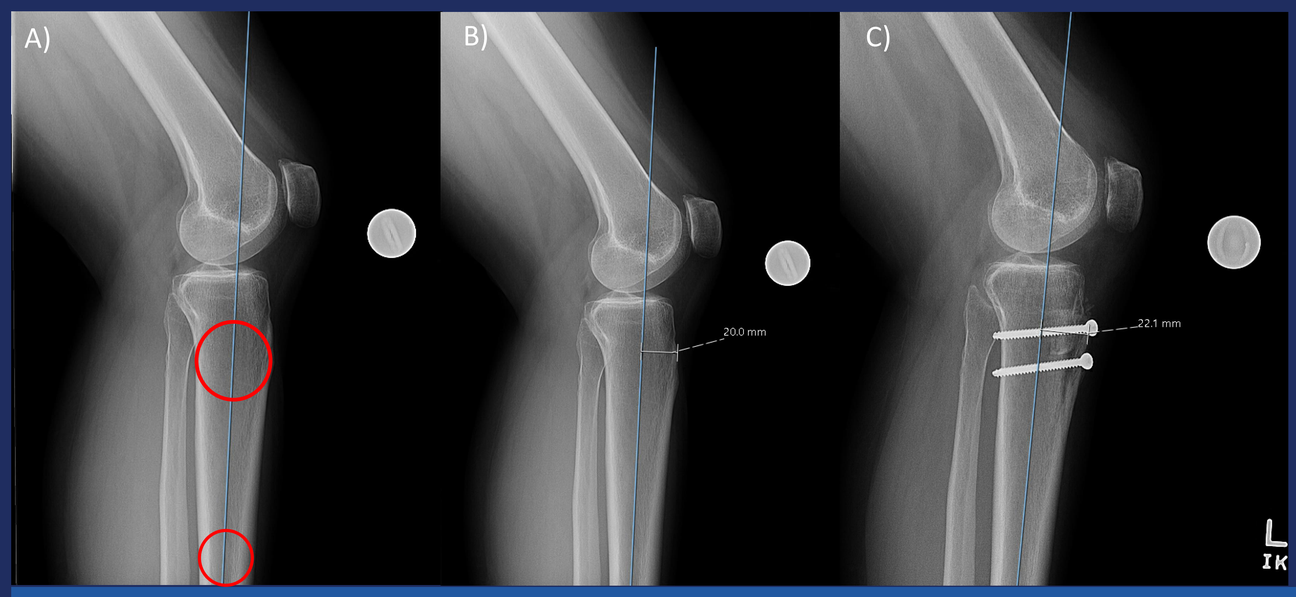

Figure 1. Radiographic measurement of change in sagittal tubercle position. A) Two circles, one at 5 cm from the tibial plateau and one 15 cm from the tibial plateau are drawn. A line that bisects the two circles is then used as the reference point. B) The anterior distance is measured as the distance from the line drawn in part A to the most anterior aspect of the tibial tubercle (20.0 mm). C) Utilizing the methods explained in A and B, the postoperative XR is similarly measured (22.1 mm). The preoperative distance is then subtracted from the postoperative distance. The anteriorization amount for this example is 22.1 – 20.0 = 2.1 mm.

Results

- 38 patients (33 [86.8%] women), mean ± SD age 29.3 ± 9.7 years
- Mean preoperative CDI was 1.32 ± 0.13, which significantly decreased to a mean of 1.02 ± 0.1 postoperatively ($p<0.001$)
- Mean operative distalization was 8.8 ± 1.1 mm
- **No significant change** in **sagittal tubercle position** (i.e., anteriorization/posteriorization) pre- (21.6 mm) to postoperatively (22.4 mm, $p=0.14$)
- Mean amount of relative anteriorization/posteriorization following TTO-d was 0.82 ± 1.4 mm anterior (median: 0.75 mm anterior; range: 1 mm posterior to 4 mm anterior)
- Thirty-one (81.6%) patients experienced no change or slight anteriorization of the tibial tubercle, while 7 patients (18.4%) experienced ≤1 mm of posteriorization
- No patient experienced more than 1 mm of posteriorization
- Excellent agreement between raters (ICC 0.93)

References

- Kaplan DJ, Mojica ES, Ortega PF, et al. Posterior tibial tubercle measured by the sagittal TT-TG distance correlates with increased risk for patellofemoral chondral lesions. *Knee Surg Sports Traumatol Arthrosc*. 2022;30(11):3733-3741.

- Lansdown DA, Christian D, Madden B, et al. The sagittal tibial tubercle-trochlear groove distance as a measurement of sagittal imbalance in patients with symptomatic patellofemoral chondral lesions. *Cartilage*. 2021;13(1 suppl):449S-455S.

- Namiri NK, Caliva F, Martinez AM, Pedoia V, Lansdown DA. A more posterior tibial tubercle (decreased sagittal tibial tubercle-trochlear groove distance) is significantly associated with patellofemoral joint degenerative cartilage change: a deep learning analysis. *Arthroscopy*. 2023;39(6):1493-1501 e1492.

ISAKOS CONGRESS 2025
MUNICH GERMANY
June 8-11