ISAKOS CONGRESS 2025 | MUNICH GERMANY June 8–11 | 医療法人社団 西宮回生病院 NISHINOMIYA KAISEI HOSPITAL

Double Level Osteotomy Provides Fairly Satisfactory Mid-term Outcomes in Patients with Symptomatic Severe Varus Osteoarthritic Knee.

Ryo Ueshima [1,3], M.D., Shintaro Onishi [2], M.D., Tomoya Iseki [2], M.D., Ryo Kanto [1], M.D., Ryuichi Gejo [3], M.D., Shinichi Yoshiya [1], M.D., Toshiya Tachibana [2], M.D., Hiroshi Nakayama [2], M.D.

1. Nishinomiya Kaisei Hospital, Japan, Dept. of Orthopaedic Surgery
2. Hyogo Medical University, Japan, Dept. of Orthopaedic Surgery
3. University of Toyama, Japan, Dept. of Orthopaedic Surgery

Disclosure Information

- Presenter : Ryo Ueshima, M.D.
- I have no conflict of interest to declare.

Double Level Osteotomy (DLO)

Deformity correction by high tibial osteotomy (HTO) alone may result in non-physiologic joint line obliquity in cases requiring a large amount of correction.

DLO was introduced to correct severe varus deformity while restoring physiologic bone and joint geometry.

Previous studies with short-term F/U evaluation have reported good outcomes after DLO.

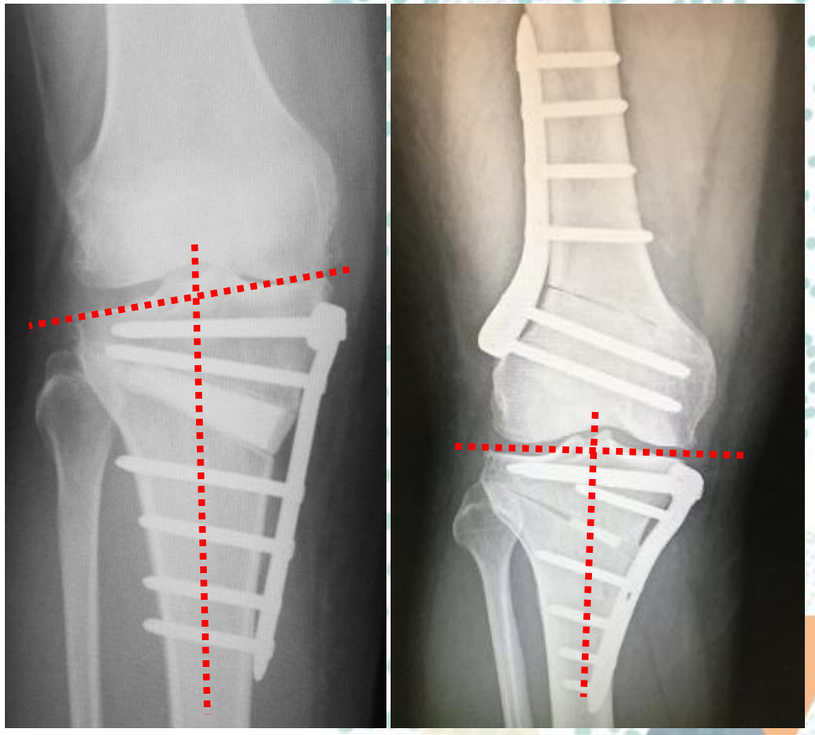

There is a paucity of information regarding the mid-term outcomes following DLO.

Purpose & Study Population

To examine the mid-term outcomes following DLO and analyze the relationship between the radiological and clinical outcomes.

DLO for symptomatic severe varus knee osteoarthritis

36 knees (26 patients)

Sex : male 3, female 23

Age : 62.4 ± 5.4 years

Minimum 5 years F/U

Kellgren-Lawrence classification :

grade 3 : 2 knees (5.6%) grade 4 : 34 knees (94.4%)

Surgical Planning & Procedure

Whole leg standing radiograph

Degital planning soft (mediCAD®)

- ➢ mLDFA : ≒ 85°
- ➢ mMPTA : ≒ 90°
- ➢ **HKA : 1°valgus**

S Schröter, H Nakayama, et al. Arch Orthop Trauma Surg 2018

- ✓ Arthroscopic intra-articular procedure
- ✓ Lateral closed-wedge distal femoral osteotomy (LCW-DFO)
- ✓ Medial opening-wedge high tibial osteotomy (MOW-HTO)

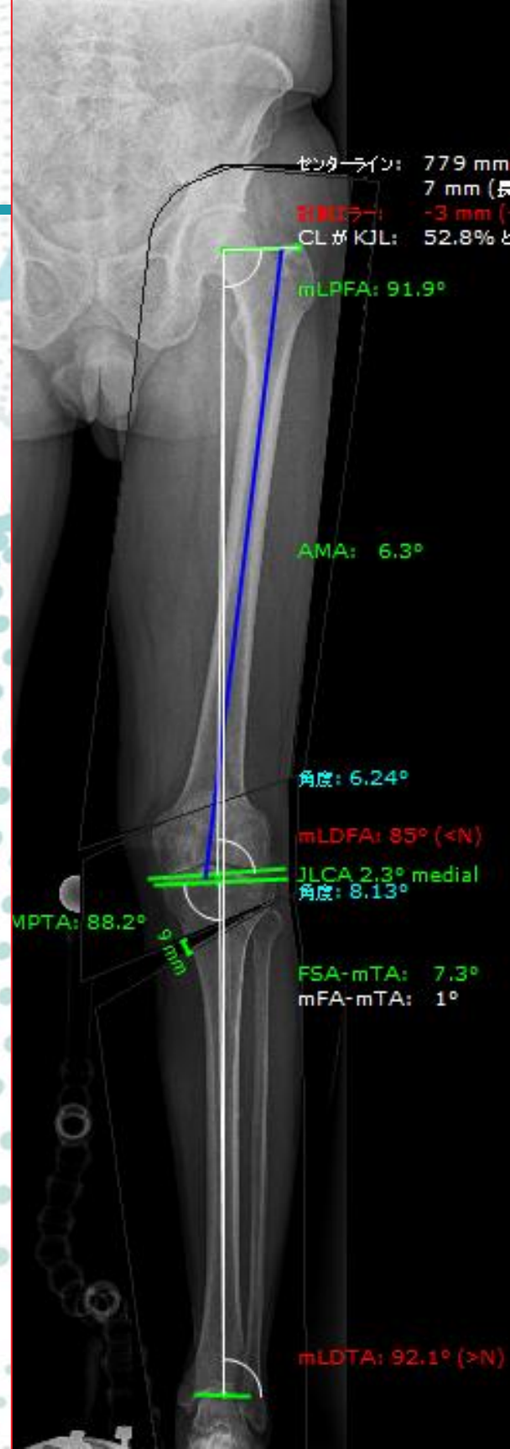

Definition of Under-correction Group and Acceptable Group

Intended postoperative HKA : 1°valgus

↓

Postoperative HKA ≧ 2°varus at 5 years

Yes ↓ | No ↓

Under-correction group	***Acceptable group***
≧ 2°residual varus	from 2°varus to valgus

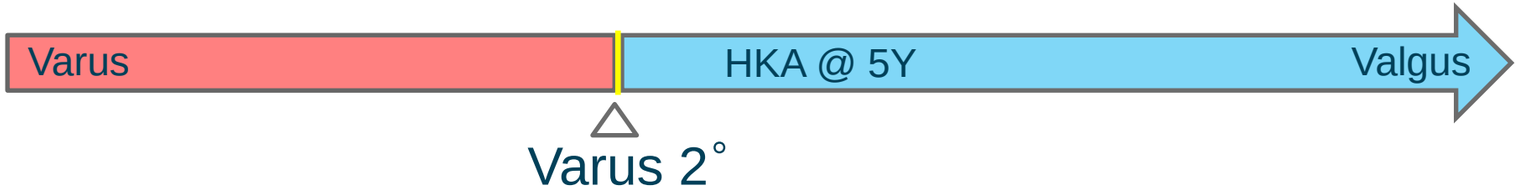

Clinical parameters

1.KOOS * total score

Radiographic parameters

1.HKA

2.mMPTA

3.mLDFA

4.Joint line convergence angle (JLCA)

- ✓ Before surgery
- ✓ 2 years after DLO
- ✓ 5 years after DLO

Results①

Pre- and Postoperative Radiological Parameters and Clinical Results

	Preoperative	2 years	5 years
KOOS	185.4 ± 74.2	393.2 ± 76.3	383.7 ± 77.1
HKA	-14.6 ± 2.7	-0.4 ± 3.0	-1.2 ± 3.6
mMPTA	82.2 ± 1.8	88.9 ± 2.3	89.2 ± 2.3
mLDFA	91.0 ± 2.0	85.8 ± 1.6	85.6 ± 1.5
JLCA	6.2 ± 2.4	3.7 ± 1.9	4.8 ± 2.0

One-way ANOVA Statistical significance : $p < 0.05$.

KOOS scores were significantly improved 2 years and maintained at 5 years.

Slight varus recurrence occurred at 5 years.

No significant changes in bony geometry were noted between 2 and 5 years.

JLCA decreased to 3.7° at 2 years but increased again to 4.8° at 5 years.

Results②

Comparison of Postoperative Parameters

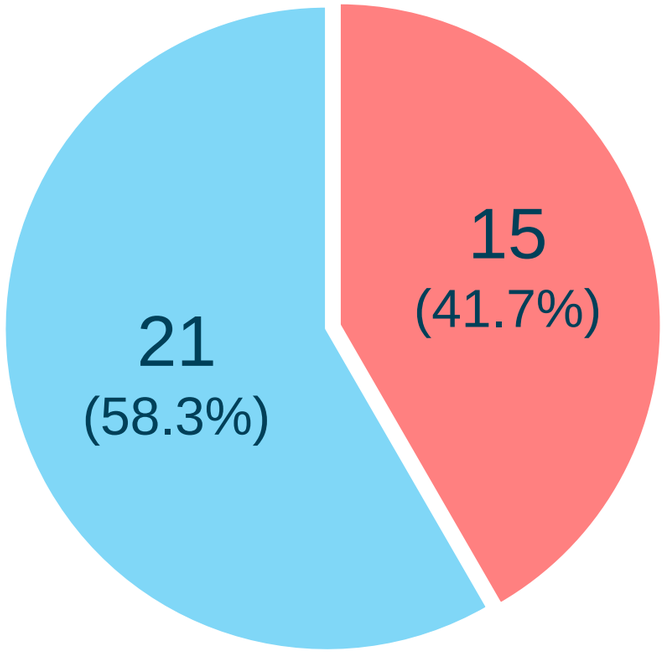

- HKA ≧ 2°varus (under-correction)
- HKA < 2° varus (acceptable)

Postoperative (5Y)	Under-correction	Acceptable	p value
HKA	4.0º ± 1.7º varus	0.8º ± 3.2º valgus	< 0.001
mLDFA	85.9º ± 1.5º	85.4º ± 1.4º	0.293
JLCA	6.2º ± 1.2º	3.8º ± 1.6º	< 0.001
mMPTA	88.1º ± 1.7º	90.0º ± 2.4º	0.009
KOOS	341.8 ± 88.3	413.6 ± 49.8	0.012

Student's t-test, Mann-Whitney U test
Statistical significance : $p < 0.05$.

KOOS in the under-correction group was significantly **lower** than the acceptable correction group.

Discussions

Present study：
5 years F/U
↓
good clinical outcomes comparable to those of previous papers.

Author	F/U		KOOS	HKA	JLCA
Saragaglia et al. 2012	46	Pre	N.A	–12.3 ± 3.5	N.A.
		Post	N.A	1.8 ± 1.8	N.A.
Akamatsu et al. 2021	24	Pre	212.1	–10.1 ± 2.4	5.4 ± 2.0
		Post	351.2	4.4 ± 3.4	3.6 ± 2.2
Nakayama et al. 2021	42.7	Pre	199.5 ± 74.2	–13.7 ± 3.1	5.8 ± 2.3
		Post	399.6 ± 67.4	–0.8 ± 2.7	4.2 ± 2.2
Present study	**60**	**Pre**	**185.4 ± 74.2**	**-14.6 ± 2.7**	**6.2 ± 2.4**
		Post	**383.7 ± 77.1**	**-1.2 ± 3.6**	**4.8 ± 2.0**

Discussions

Recurrence of varus deformity and increased JLCA were observed in the study raise concerns for future OA progression.

We aimed at 1˚valgus in DLO performed for advanced OA during the study period. Considering the results of study, residual varus can be associated with unfavorable outcomes and should be avoided.

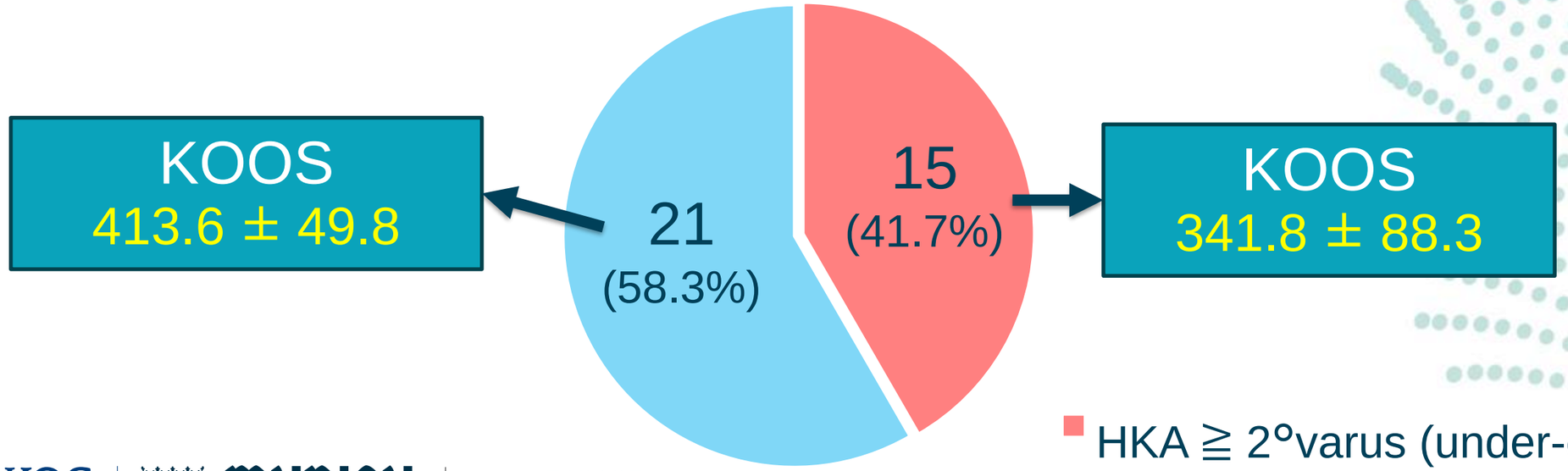

HKA ≧ 2°varus (under-correction)
HKA < 2° varus (acceptable)

Limitaions

- ✓ Retrospective study with small number of subjects.
- ✓ Factors related to residual varus alignment were not evaluated.
- ✓ Patients with unintended over-correction were not subjected to the analysis.

Conclusions

- The present study for DLO patients showed slight under-correction and a small amount of recurrence of bone/joint deformity over time; however, postoperative clinical improvement was maintained through 5 years.

- The clinical outcomes at 5 years were significantly inferior in the under-correction group.

References

- S Schröter, H Nakayama, S Yoshiya, et al.
  Development of the double level osteotomy in severe varus osteoarthritis showed good outcome by preventing oblique joint line.
  Arch Orthop Trauma Surg. 2019 Apr;139(4):519-527. doi: 10.1007/s00402-018-3068-9.

- D Saragaglia, M Blaysat, N Mercier, et al.
  Results of forty two computer-assisted double level osteotomies for severe genu varum deformity.
  Int Orthop. 2012 May;36(5):999-1003. doi: 10.1007/s00264-011-1363-y.

- Y Akamatsu, S Nejima, M Tsuji, et al.
  Joint line obliquity was maintained after double-level osteotomy, but was increased after open-wedge high tibial osteotomy
  Knee Surg Sports Traumatol Arthrosc. 2022 Feb;30(2):688-697. doi: 10.1007/s00167-020-06430-6.

- H Nakayama, R Kanto, S Onishi, et al.
  Cartilage repair examined by second-look arthroscopy following double-level osteotomy performed for osteoarthritic knees with severe varus deformity
  Knee. 2021 Mar:29:411-417. doi: 10.1016/j.knee.2021.02.024.