Association between humeral tray protrusion and proximal humeral osteolysis after reverse shoulder arthroplasty

Shuhei Matsumura[1)], Yohei Harada[1)], Chikara Watanabe[1)], Shin Yokoya[2)], Nobuo Adachi[1)]

1)Hiroshima University Hospital, Department of Orthopedic Surgery

2) Hiroshima Citizen Hospital, Department of Orthopedic Surgery

ISAKOS CONGRESS 2025

Faculty Disclosure Information

Presenter: Shuhei Matsumura

I have no financial relationship to disclose.

Introduction

- The postoperative complications of reverse shoulder arthroplasty (RSA) include osteolysis around the humeral stem, potentially leading to **peri-stem fractures** and **bone loss** at revision surgery.

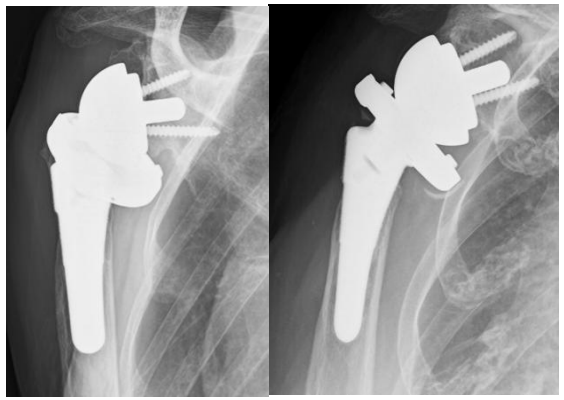

- **Proximal humeral osteolysis was significantly more frequent in cases with a large humeral tray diameter in our previous study.**[1)]

【Hypothesis】

Osteolysis around the proximal humerus would increase with greater tray protrusion.

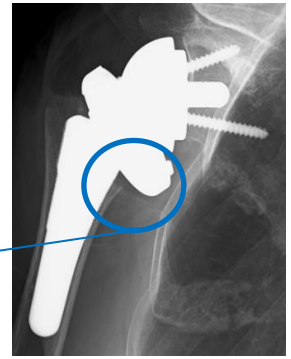

?

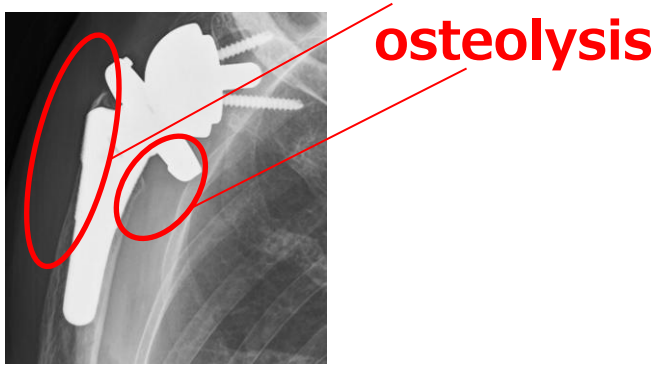

Objective

To investigate the relationship between osteolysis and the amount of tray protrusion and other factors

Materials and Methods①

【Patients】

・50 RSA shoulders ・At least 2 years follow-up ・Two institutions

【Disease】

・Massive rotator cuff tears ・Osteoarthritis ・Cuff tear arthropathy

【Prosthesis】

・Comprehensive® (Zimmer Biomet) ・Micro stem (Stem length 55mm)

【Factor】

・**Age, Sex, Tray diameter, Stem size**

・Plain radiograph evaluation
within two weeks after surgery

➢ **Tray protrusion**

➢ **Filling ratio**

【Objective variable】

・Plain radiograph evaluation
at the final follow-up

➢ **Osteolysis grade**

・**Greater tuberosity**

・**Calcar**

Materials and Methods②

➢ Tray protrusion

- Lateral protrusion (**LP**)(mm) : **tray diameter × B/A**
- Medial protrusion (**MP**)(mm) : **tray diameter × C/A**

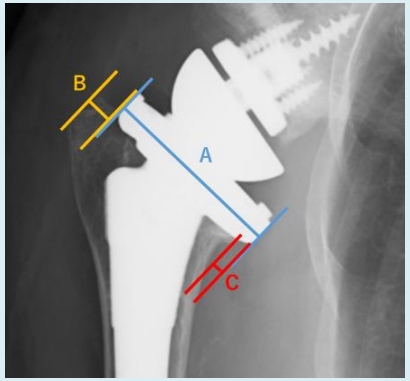

A : Tray width

B : Tray lateral protrusion

C : Tray medial protrusion

➢ Filling ratio

- metaphyseal filling ratio (**FRmet**) : **D/E**
- distal filling ratio (**FRdia**) : **F/G**

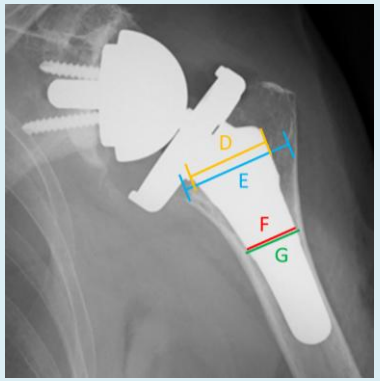

D : Stem width of metaphyseal

E : Inner cortex distance of metaphyseal

F : Stem width of distal 1/2stem

G : Inner cortex distance of distal 1/2stem

➢ Osteolysis grade

【grade classification】[2)]

Grade0 : None

Grade1 : Decrease in the cortical bone density

Grade2 : <1/2 osteolysis

Grade3 : ≧1/2 osteolysis

Grade4 : Complete disappearance

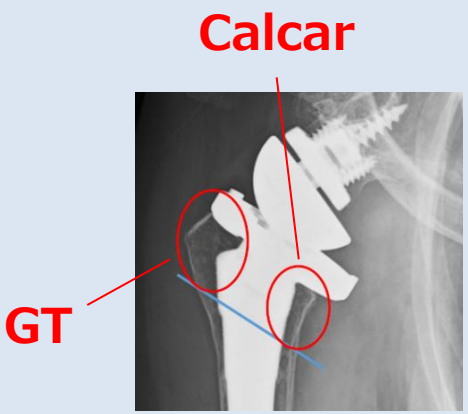

GT: grade 1

Calcar: grade 1

GT: grade 2

Calcar: grade 2

GT: grade 3

Calcar: grade 3

GT: grade 4

Calcar: grade 4

Materials and Methods③

【Statistics】

- Univariate analysis for each factor

  Spearman's rank correlation coefficient (continuous variable)

  Mann-Whitney U test (dichotomous variable)

- Multivariate logistic regression analysis (Age, Sex, FRdia, MP, LP)
- P＜0.05 as statistically significant difference

Results

【Patients】

- Sex : Male 16, Female 34
- Age(Y) : **78.5**±5.4
- Observation period(M) : **48.9**±10.5



Univariate analysis(Osteolysis of GT)

Age

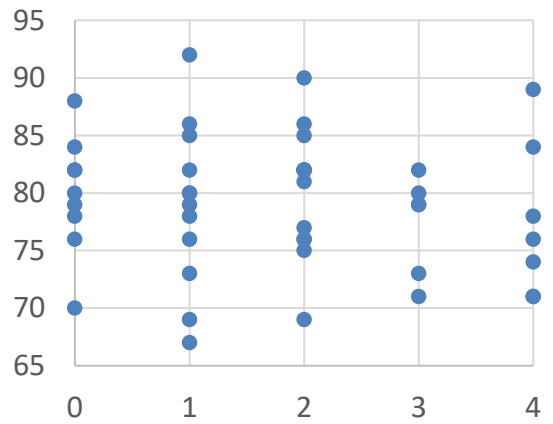

R=-0.07 P=0.81

Sex

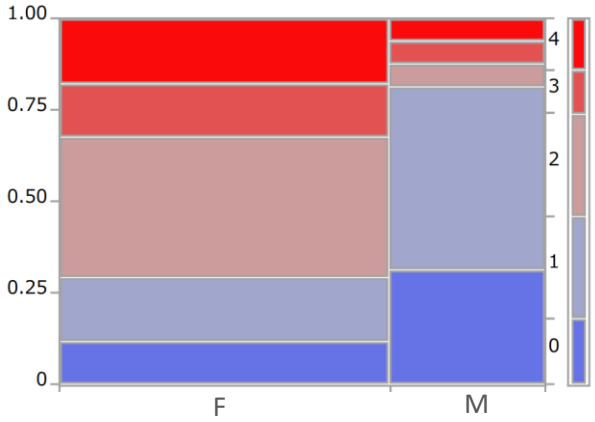

P=0.01

Stem size

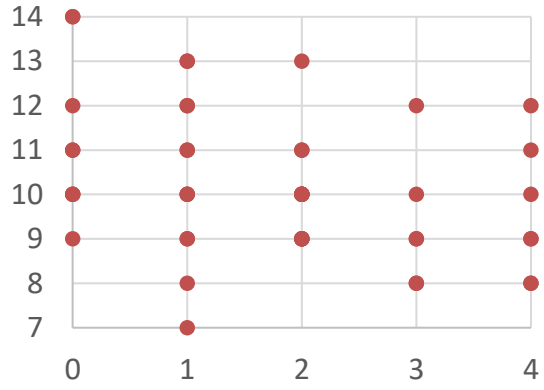

R=-0.36 P=0.009

Tray diameter

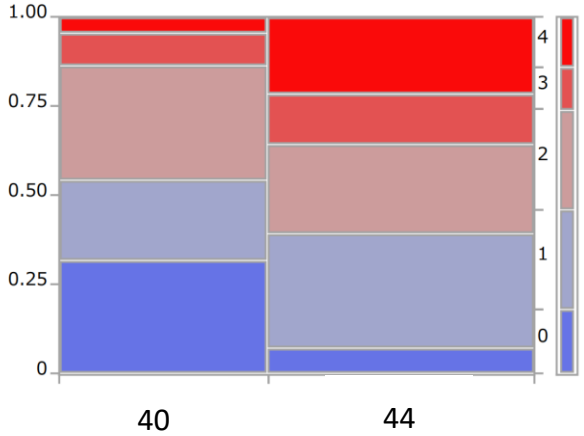

P=0.09

FRmet

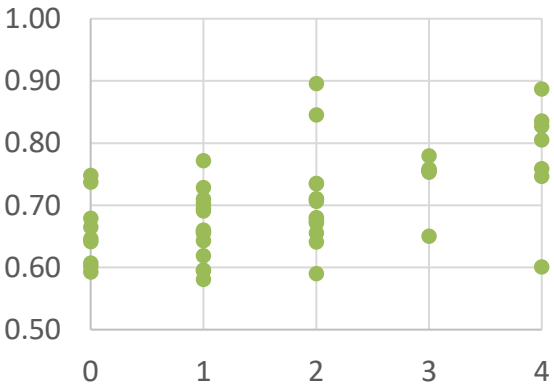

R=+0.53 P<0.001

FRdia

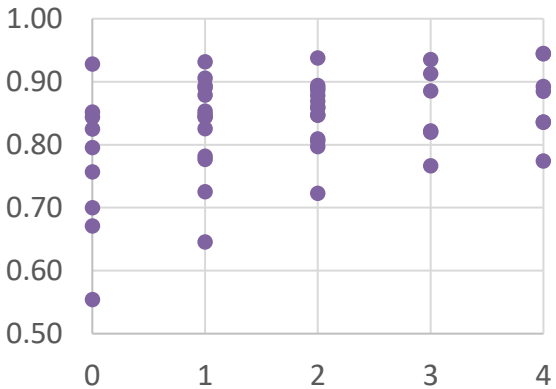

R=+0.32 P=0.005

MP

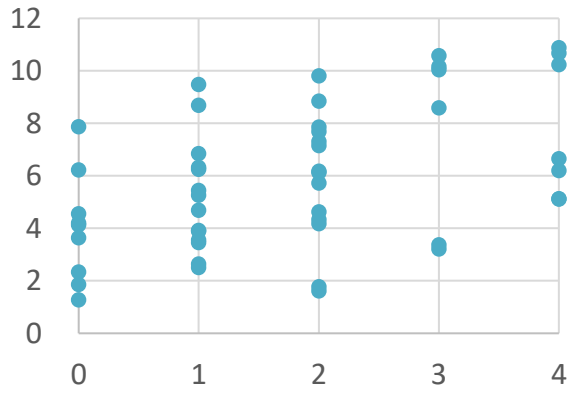

R=+0.45 P=0.0006

LP

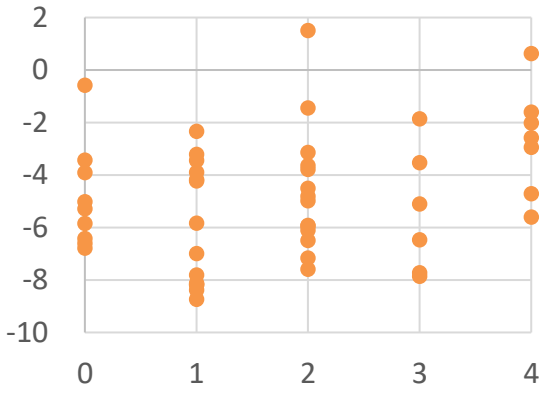

R=+0.31 P=0.01

Significant difference in Sex, Stem size, FRmet, FRdia, MP, LP

Univariate analysis(Osteolysis of Calcar)

Age

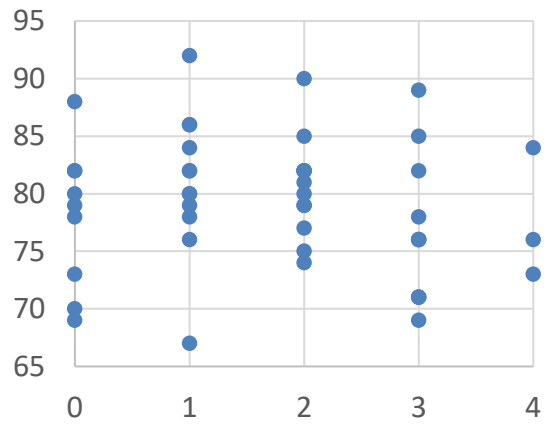

R=-0.10 P=0.57

Sex

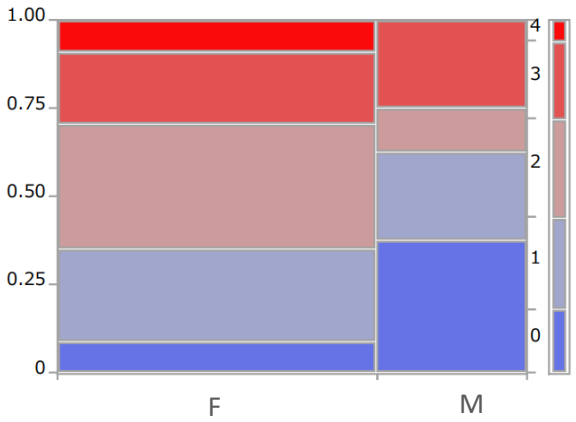

P=0.07

Stem size

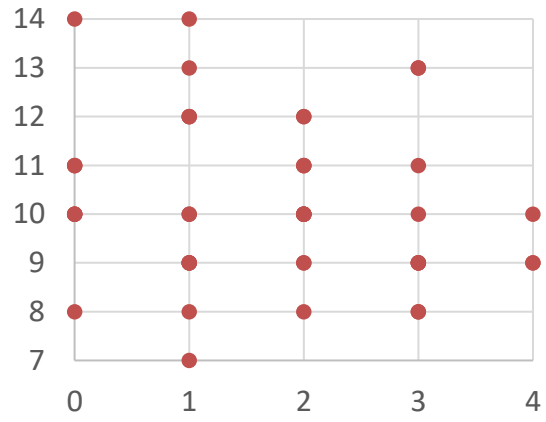

R=-0.20 P=0.23

Tray diameter

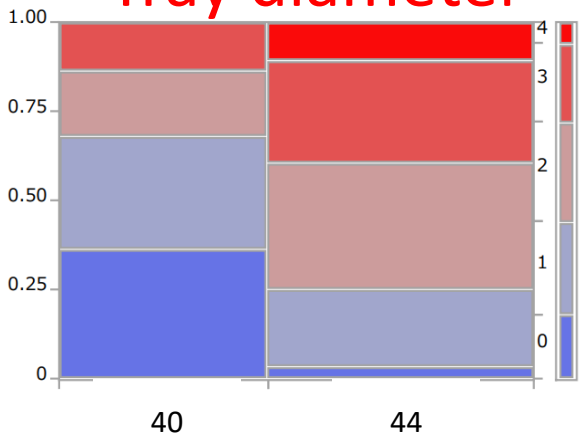

P=0.005

FRmet

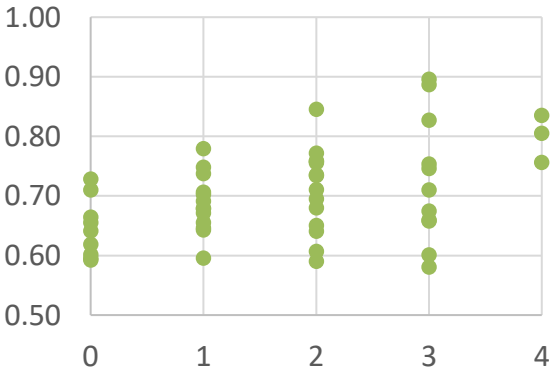

R=+0.42 P=0.006

FRdia

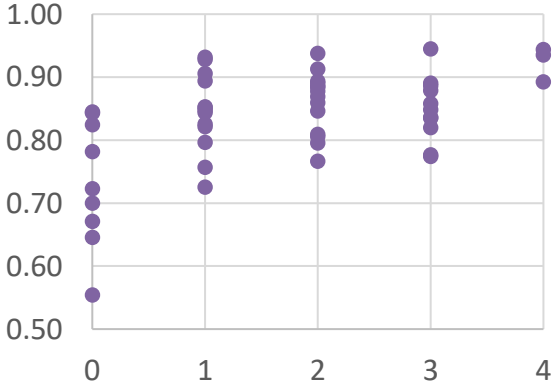

R=+0.45 P<0.001

(mm)

MP

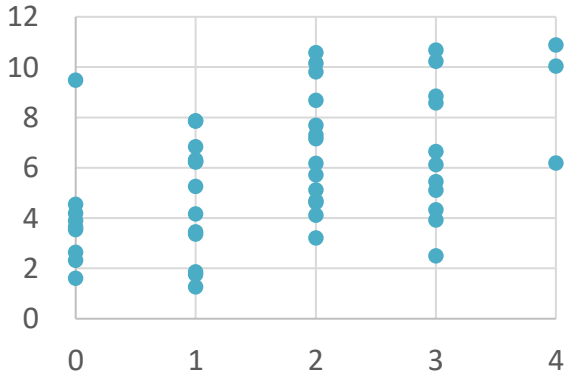

R=+0.47 P<0.001

(mm)

LP

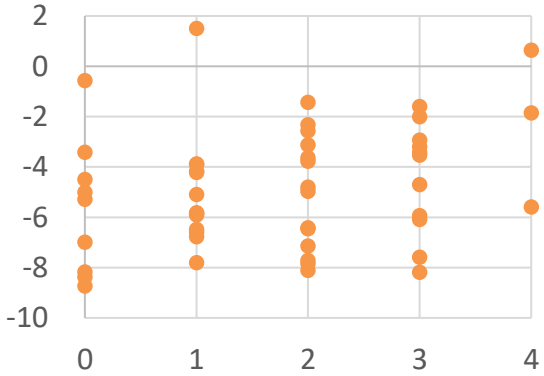

R=+0.30 P=0.027

Significant difference in Tray diameter, FRmet, FRdia, MP, LP

Multivariate analysis

Osteolysis of GT

	P value
Age	0.13
Sex	0.29
FRdia	0.15
MP	※0.008
LP	※ 0.02

Significant difference in MP, LP

Osteolysis of Calcar

	P value
Age	0.13
Sex	0.29
FRdia	※ 0.001
MP	※ 0.03
LP	※ 0.004

Significant difference in FRdia, MP, LP

※Significant

Report of osteolysis risk

- **High Filling Ratio (FR)**

  High FR is risk factor of osteolysis[3)]

<

FR ≦0.64	FR ≧0.75
6.0%	**35.8%**

- **Long stem length**

  Long stem(>100mm) is more risky than short stem[4)5)6)]

- **Tray protrusion**

  There is no report in the past ⇒ Our study is the first to report that tray protrusion is a risk factor for osteolysis.

- **Stem design, Onlay or Inlay, Neck-shaft angle**

  ⇒ These factors are no obvious risk factors in updated review[7)]

Mechanism of osteolysis

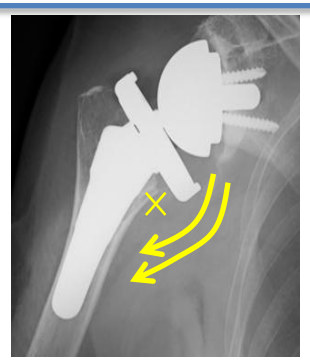

① **Stress shielding**

Tray protrusion

→ Reduction of stress in proximal humerus [1)]

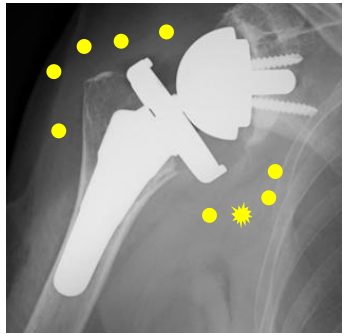

② **Wear debris**

Tray protrusion

→ Scapular notching → Polyethylene particles [8)]

Prevention of osteolysis

✓ **Prevalence rate of stress shielding/osteolysis**

In previous study : 7.8～39% [7)]

In our study : 82%

Small patient ⇨ **Large tray & Tray protrusion** ⇨ **Osteolysis**

Small tray and **appropriate offset option** would be recommended for small patients

Limitation

- Retrospective study
- Small number of cases
- Evaluation errors in plain radiographs
- One specific prosthetic design

Conclusion

- **The tray protrusion was associated with osteolysis in the proximal humerus both medially and laterally.**
- **To prevent osteolysis, small trays should be selected for small patients, and an appropriate offset option should be selected to avoid protrusion of the tray.**

Reference

1) Yokoya S, et al. Factors affecting stress shielding and osteolysis after reverse shoulder arthroplasty: A multicenter study in a Japanese population. J Orthop Sci. 2024

2) Inoue K, et al. Humeral bone resorption after reverse shoulder arthroplasty using uncemented stem. JSES Int. 2020

3) Kim SC, et al. Humeral stem with low filling ratio reduces stress shielding in primary reverse shoulder arthroplasty. Int Orthop. 2022

4) Merolla G et al. JSES Grammont humeral design versus onlay curved-stem reverse shoulder arthroplasty: comparison of clinical and radiographic outcomes with minimum 2-year follow-up. J Shoulder Elbow Surg. 2018

5) Giordano MC, et al. Comparative study of 145° onlay curved stem versus 155° inlay straight stem reverse shoulder arthroplasty: clinical and radiographic results with a minimum 2-year follow-up. J Shoulder Elbow Surg. 2022

6) Nourissat G, et al. Specific design of a press fit humeral stem provides low stress shielding in reverse shoulder arthroplasty at minimum 5 years FU. J Shoulder Elb Arthroplast. 2022

7) Vasiliadis AV, et al. Stress shielding in stemmed reverse shoulder arthroplasty: an updated review. SICOT J. 2024

8) Mazaleyrat M, et al. Humeral osteolysis after reverse shoulder arthroplasty using cemented or cementless stems comparative retrospective study with a mean follow-up of 9 years. Orthop Traumatol Surg Res. 2021