Visible fluid motion on manipulation as the new threshold for intraoperatively-determined knee arthroplasty component loosening

A Delphi study

George S. Buijs[1], Arhur J. Kievit[1], Alex B. Walinga[1], Matthias U. Schafroth[1], Michael T. Hirschmann[2,3] , Leendert Blankevoort[1]

and

International Consensus Panel

[1]Department of Orthopedic Surgery and Sports Medicine, Amsterdam UMC, Amsterdam Movement Sciences, Universiteit van Amsterdam, The Netherlands
[2]Department of Orthopaedic Surgery and Traumatology, Kantonsspital Baselland (Bruderholz, Liestal, Laufen), Bruderholz, Switzerland
[3]Department of Clinical Research, Research Group Michael T. Hirschmann, Regenerative Medicine & Biomechanics, University of Basel, Basel, Switzerland

ISAKOS CONGRESS 2025
MUNICH GERMANY June 8–11

ORTHOPEDIC SURGERY AND SPORTS MEDICINE

Amsterdam UMC

Faculty Disclosure Information

- Leendert Blankevoort, Arthur J. Kievit and Matthias T. Schafroth are listed as inventors on a patent for a loading device and method to be used to quantify and visualise implant displacement
- The remaining authors declare no conflict of interest
- This study was funded by an internal TKI-PPP grant from the Amsterdam University Medical Center. Allowance made available by Health-Holland, Top Sector Life Sciences & Health, to stimulate public private partnerships.

NL Health~Holland
SHARED CHALLENGES, SMART SOLUTIONS

The problem

- Knee arthroplasty
  - Total knee arthroplasty (TKA)
  - Revision total knee arthroplasty (rTKA)
  - Unicondylar knee arthroplasty (UKA)
- Aseptic loosening is an indication for revision surgery[1]
- Imaging modalities are used in the diagnostic process[2,3]
- To determine sensitivity & specificity of the imaging modalities the intraoperative outcome is required[2]
- There is great variation of reported criteria to decide that an arthroplasty component is loose[2]
- There is no consensus on the criteria for intraoperatively determining a loose knee arthroplasty component

Questions

- Among highly specialized knee revision surgeons
  - Is there consensus regarding the definition of intraoperatively determined loosening of TKA or UKA components?
  - What is the extent of variability when a TKA or UKA component should be considered loose when intraoperatively determined?

Methods

- Delphi method to reach consensus[4,5]
- International expert panel
- Three rounds
  - Survey with open questions → Statements
  - Propositions derived from statements → Agreements
  - Final set of propositions → Final definition

Expert panel

- 69 invited → 38 (55%) responded
- Of the 38 responders 34 (89%) completed all Delphi rounds
  - More than 10 revision per year: 91%
  - More than 10 years experience: 82%

Results

Open questions

37 responders

Distinctive statements
TKA: 29
rTKA: 32
UKA: 28

34 responders

Edited distinctive statements

Tibia component: 31

Femur component: 29

> 70% agreement
Tibia component: 18
Femur component: 16
High variability: 22

34 reponders

4 consecutive definitions of component loosening

Consensus

1

2

3

Delphi rounds

Consecutive definitions of component loosening

A tibial and/or femoral component is considered loose if there is

(1) complete detachment at the interface, which is indicated by the easy removal of the prosthesis without the need for additional force or tools.

(2) macroscopic mobility of the implant observed during specific movements such as flexion, extension, varus or valgus stress or when applying direct gentle force with a finger or instrument (e.g., probe or osteotome).

(3) visible fluid motion at the interface (without macroscopic mobility of the implant) observed during specific movements such as flexion, extension, varus or valgus stress or when gently applying a direct force with a finger or instrument (e.g., probe or osteotome).

(4) macroscopic mobility of the implant after single impaction (e.g., with a hammer).

Visible fluid motion at the interface when gently applying a direct force with a finger

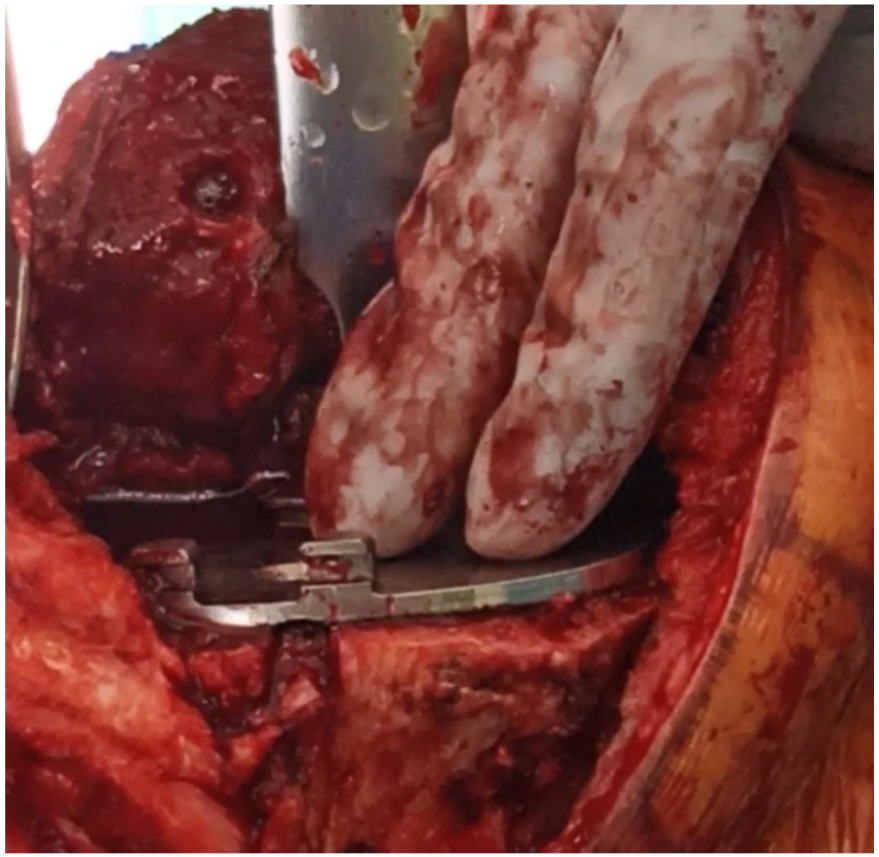

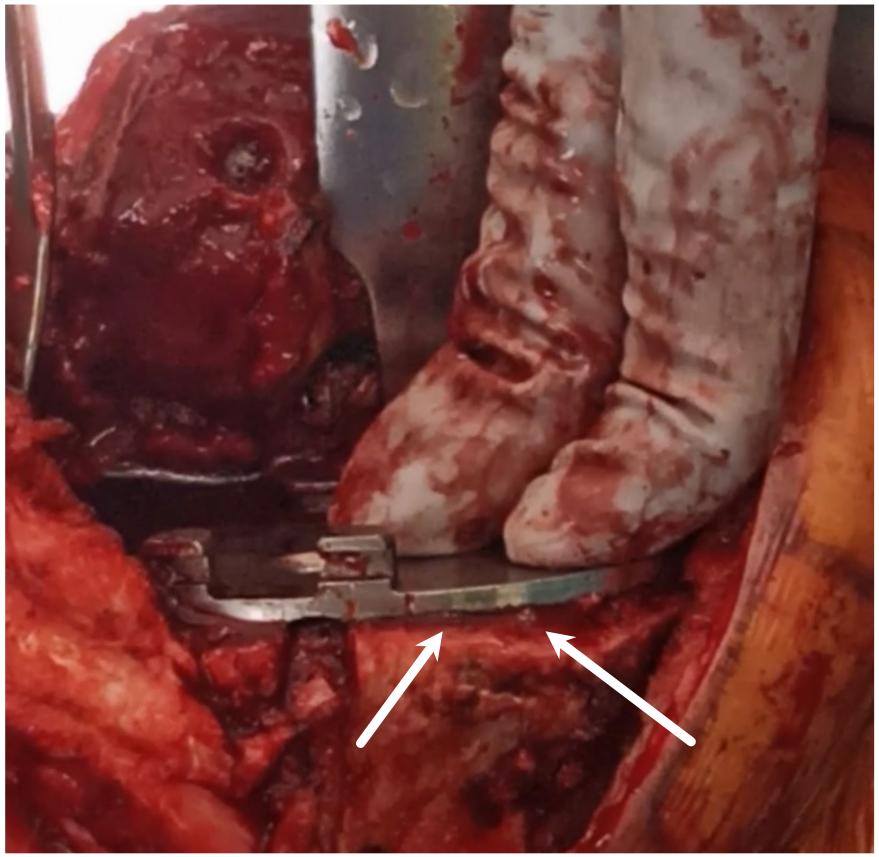

Scan the QR-code for the video

Conclusions

- High variability

  in factors contributing to the determination that a TKA or UKA component should be judged as loose
- Consensus
  - on the visibility of fluid motion at the interface between the arthroplasty component and/or cement and the bone during specific movements, such as flexion, extension, varus or valgus stress or when gently applying direct force with a finger or instrument, as definition for intraoperatively determined knee arthroplasty component loosening
- Implication
  - This new definition should be used as a threshold in diagnostic test studies where intraoperatively determination of component loosening is employed as reference test

International Consensus Panel

- Claudia Arias
- Johannes Beckmann
- Lennard van den Boom
- Bert Boonen
- Benjamin V. Bloch
- Nicolaas C. Budhiparama
- Antonia F. Chen
- Rüdiger von Eisenhart-Rothe
- Rutger van Geenen
- Enrique Gómez-Barrena
- Heiko Graichen
- James A. Harty
- Roel Hendrick,
- Michael T. Hirschmann
- Arthur J. Kievit
- Lucien Keijser
- Robin W. T. M. van Kempen
- Jean-Yves Jenny
- Sébastien Lustig
- Hermes H. Miozzari
- Arun Mullaji
- Sam I. S. Oussedik
- Kailash Patil
- Carsten Perka
- Matthias U. Schafroth
- Reha N. Tandogan
- Emmanuel Thienpont
- Peter C. M. Verdonk
- Jonathan Vigdorchik
- Daniel C. Wascher
- Phil Walmsley
- Jan Victor
- Adolph Joseph Yates Jr
- Simon van Laarhoven

References

1. Robertsson, O., Ranstam, J., Sundberg, M., W-Dahl, A. & Lidgren, L. (2014) The Swedish Knee Arthroplasty Register: a review. Bone Joint Res 3, 217–222.
2. Buijs, G.S., Kooijenga, A.C., Rikken, R.G.H., Schafroth, M.U., Kievit, A.J. & Blankevoort, L. (2024) MRI and SPECT/CT demonstrate, with low certainty of evidence, the highest diagnostic accuracy for aseptic knee arthroplasty loosening; a systematic comparative diagnostic test review and metaanalysis. Knee Surg Sports Traumatol Arthrosc 32, 2061-2074.
3. Buijs, G.S., Kievit, A.J., Schafroth, M.U., Hirschmann, M.T. & Blankevoort, L. (2025) Weight-bearing pain and implant migration progressive radiolucencies, radiolucencies (>2 mm) and subsidence on X-ray and CT are generally accepted criteria fitting knee arthroplasty loosening—an international Delphi consensus study. Knee Surg Sports Traumatol Arthrosc 33, 935-943.
4. Diamond, I.R., Grant, R.C., Feldman, B.M., Pencharz, P.B., Ling, S.C., Moore, A.M. et al. (2014) Defining consensus: a systematic review recommends methodologic criteria for reporting of Delphi studies. J Clin Epidemiol 67, 401–409.
5. Jünger, S., Payne, S.A., Brine, J., Radbruch, L. & Brearley, S.G. (2017) Guidance on Conducting and REporting DElphi Studies (CREDES) in palliative care: recommendations based on a methodological systematic review. Palliative Medicine 31, 684–706.

Full-text publication

Fluid motion at the interface with manual loading

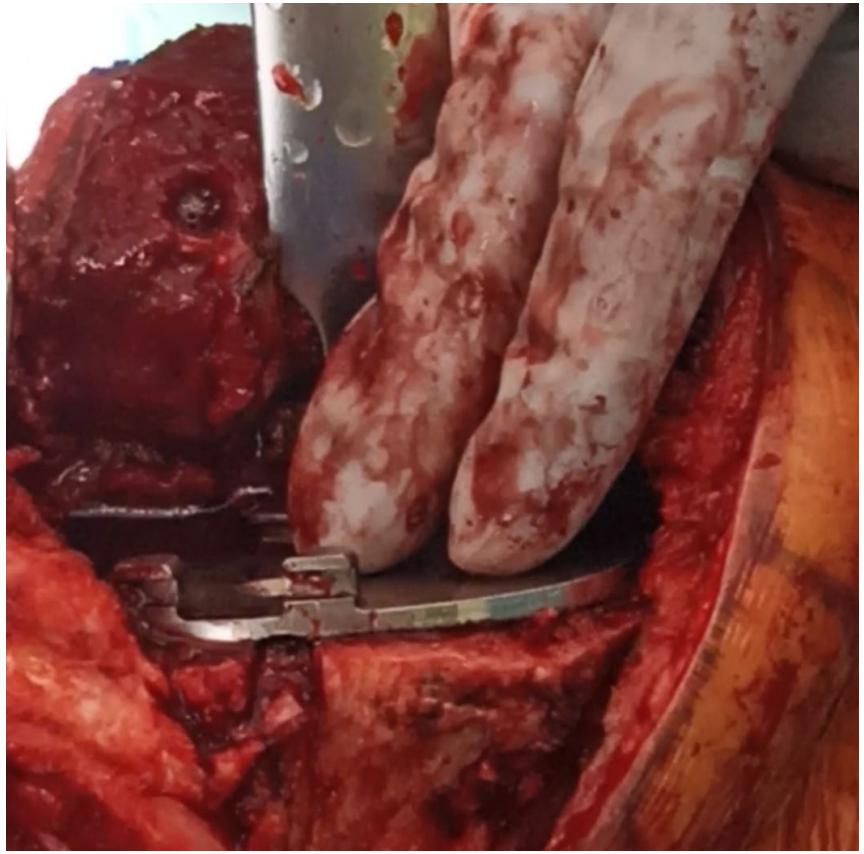

Scan the QR-code
for the video

Fluid motion at the interface with manual loading

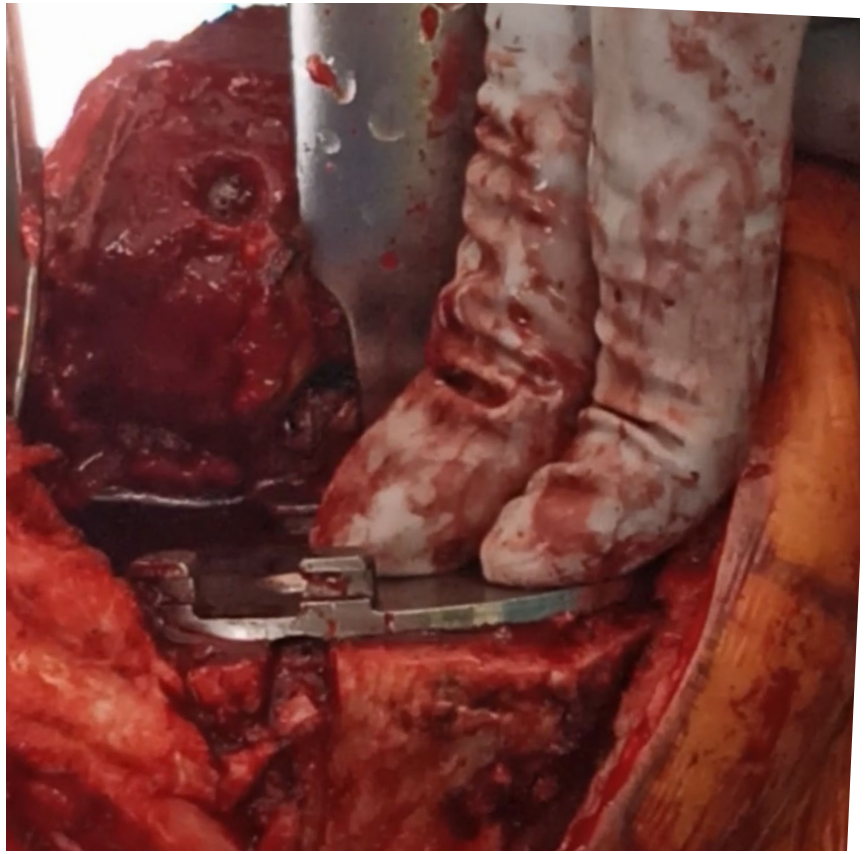

Scan the QR-code
for the video