ISAKOS CONGRESS 2025 | MUNICH GERMANY June 8–11

Evaluation Of Clinico-Radiological Outcomes Of Arthroscopic Repair Of Rotator Cuff Tear With Bioaugmentation Using Autologous Platelet Rich Plasma

Vinod Kumar, MBBS, MS, DNB, MNAMS, New Delhi, New Delhi INDIA

Rohan Goel, MBBS, MS (Ortho), Ghaziabad, UP INDIA (Presenter)

Faculty Disclosure Information

- Nothing to disclose.

Introduction

- **Overview:**

✓ Shoulder joint has high degree of motion due to humeral head–glenoid cavity disproportion.

✓ Rotator cuff provides dynamic stabilization of the gleno-humeral joint and also contributes to shoulder movements.

- **Pathophysiology:**

✓ Rotator cuff tears range from impingement to full-thickness tear.

✓ Incidence increases with age and repetitive microtrauma.

✓ Tears can be degenerative (most common) or traumatic.

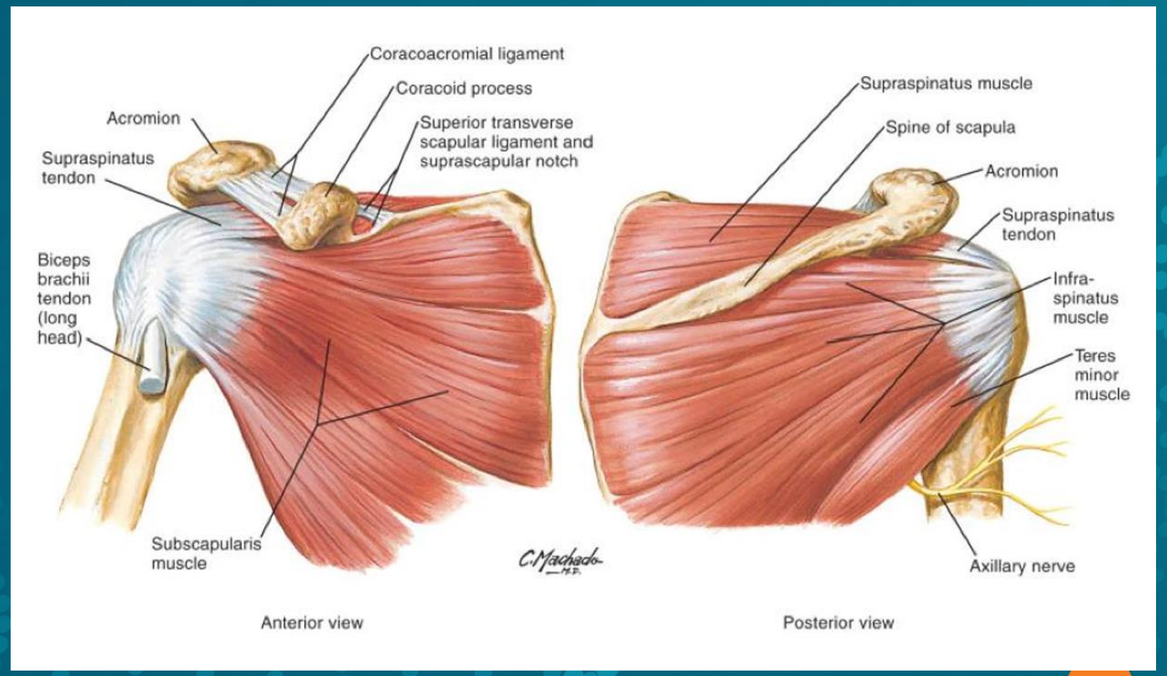

Introduction

- **Clinical Challenges:**

✓ Loss of dynamic stabilization results in pain, limited function, and compromised activities of daily living.

✓ Failure to generate a normal tendon-to-bone interface and replacement with reactive fibrous scar tissue after repair is a well-known documented factor that can consequently lead to re-tears.

- **Role of PRP:**

✓ Autologous platelet concentrate rich in growth factors aims to enhance cellular proliferation, angiogenesis, and tissue healing at the repair interface.

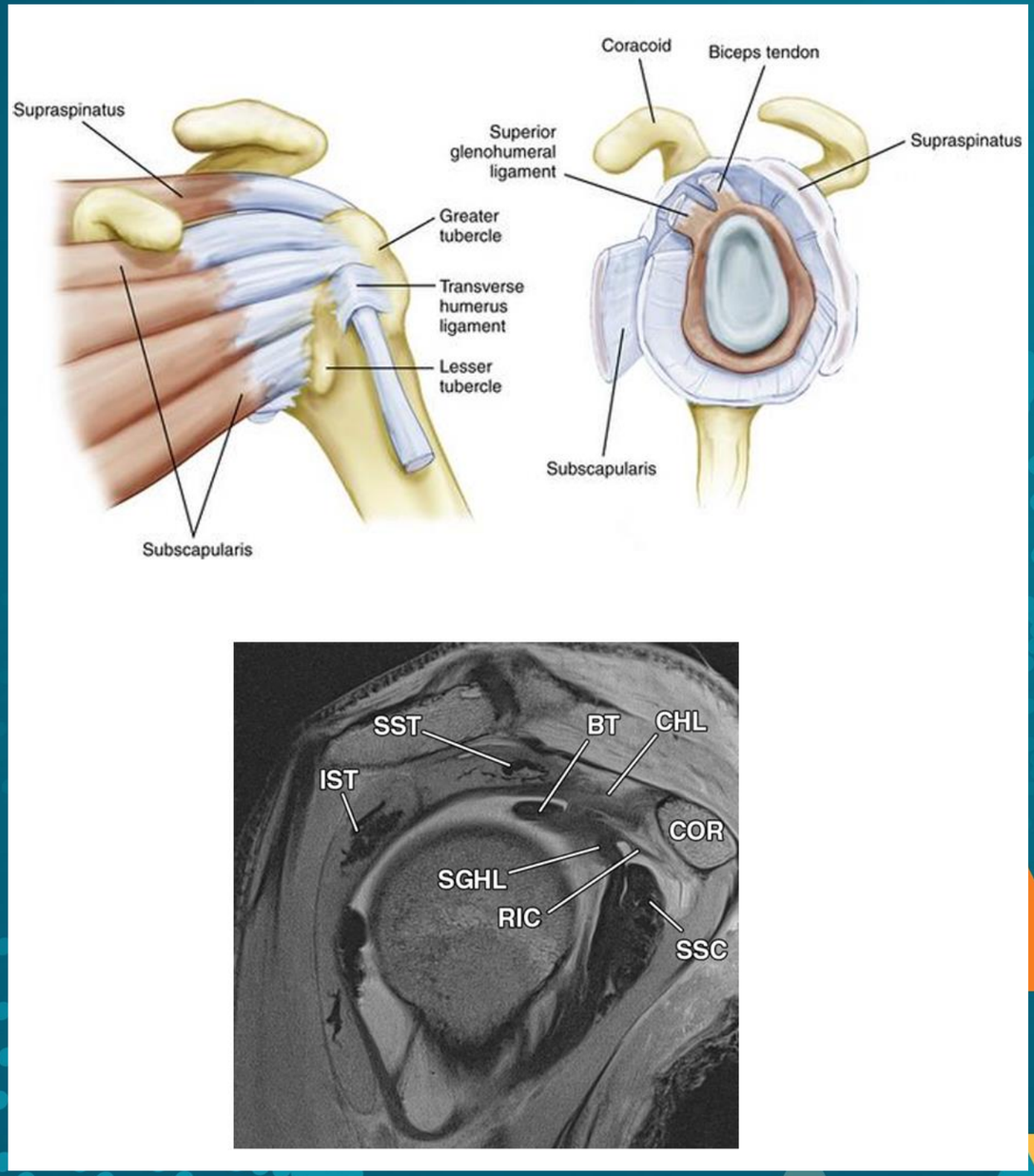

Aims and Objectives

- **Primary Aim:**

✓ To evaluate the effect of PRP on the clinico-radiological outcomes of arthroscopic rotator cuff repair.

- **Key Objectives:**

✓ To evaluate clinical and functional outcomes (VAS score, DASH score, Constant-Murley Score, UCLA score).

✓ To assess postoperative tendon healing using MRI (MRI healing index, Sugaya classification).

Methodology (Study Design & Patient Selection)

- **Study Design:**

✓ Prospective interventional study at Department of Orthopedic Surgery, Maulana Azad Medical College and associated Lok Nayak Hospital, New Delhi, India.

- **Patient Selection:**

✓ **Inclusion:** All patients with symptomatic rotator cuff tears (age between 35 and 75 years of either sex).

✓ **Exclusion:** Patients with contraindications to surgery or significant comorbidities.

✓ The sample size for the study was 20 patients.

Methodology (Surgical Technique & PRP Preparation)

- **Surgical Technique:**

✓ The technique of repair in our study was either Arthroscopic single row or double row technique.

✓ 5.5 mm titanium/bio absorbable double loaded screw suture anchor were used in either single row or double row fashion.

- **PRP Preparation & Application:**

✓ Autologous blood centrifugation (3000 RPM for 10 minutes) in an anticoagulant coated syringe (Acid Citrate Dextrose) to obtain 3-6 times concentration of platelets.

✓ PRP administered intraoperatively at the repair site.

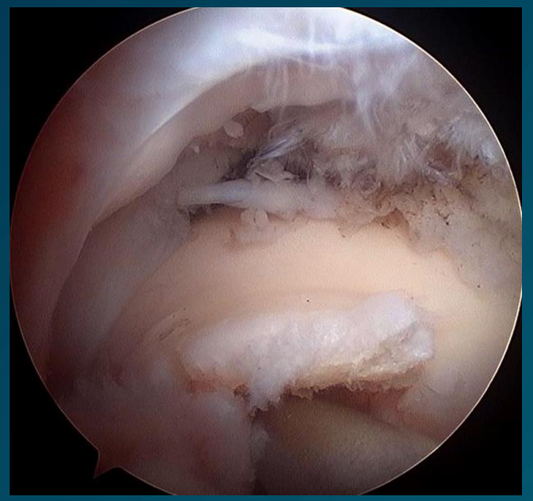

Intraoperative visualisation of Supraspinatus tendon tear

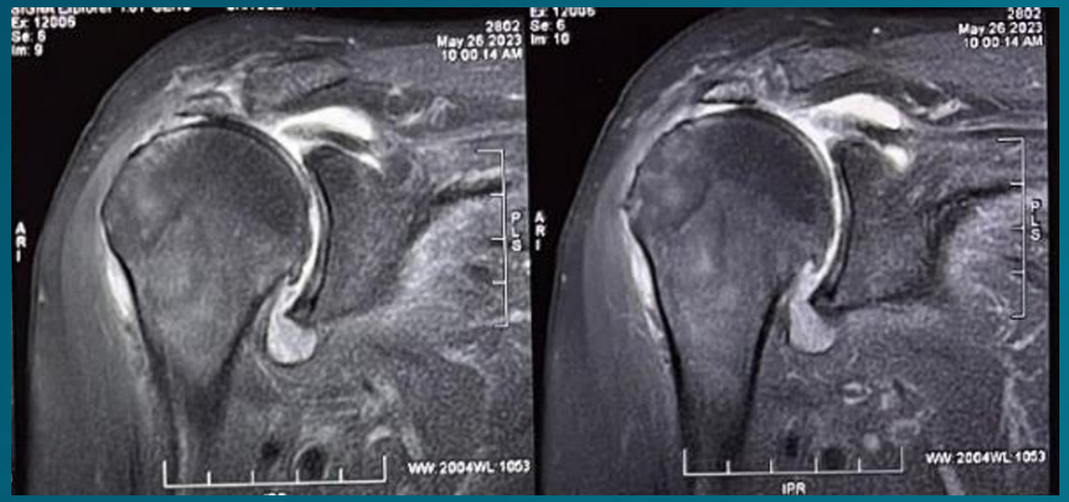

Preoperative MRI showing full thickness tear of Supraspinatus tendon

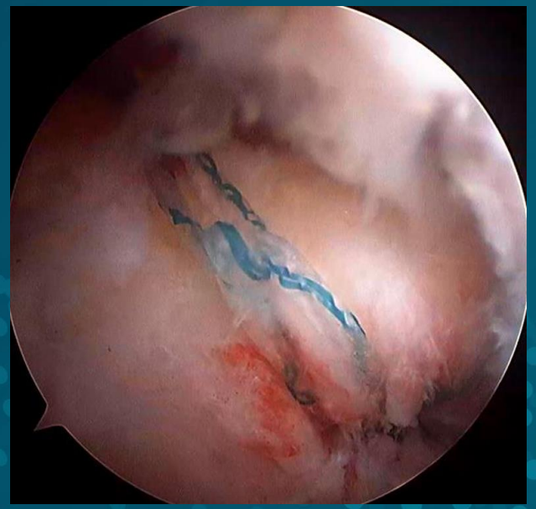

Intraoperative picture after tendon repair

Postoperative MRI at 6 months showing good integrity of repaired tendon with PRP bioaugmentation

Observations and Results

- The results demonstrated a significant improvement in clinical outcomes, with reduced pain scores (VAS) and improved functional scores (CMS, UCLA and DASH).

- The **VAS score** improved from a pre-operative value of 5.65 ± 0.81 to 1.40 ± 0.50 at 1-year post-operatively. The **CMS** improved from 17.60 ± 2.83 to 59.00 ± 6.48, **UCLA** score improved from 7.25 ± 1.44 to 26.30 ± 3.33 and **DASH score** improved from 77.175 ± 5.27 to 21.23 ± 2.46 at 1-year post-operatively.

- There was evidence of re-tear in 10% of patients (Sugaya Classification) in the 6-month post-operative MRI (Retear in conventional group in literature is 20%- Joe et al).

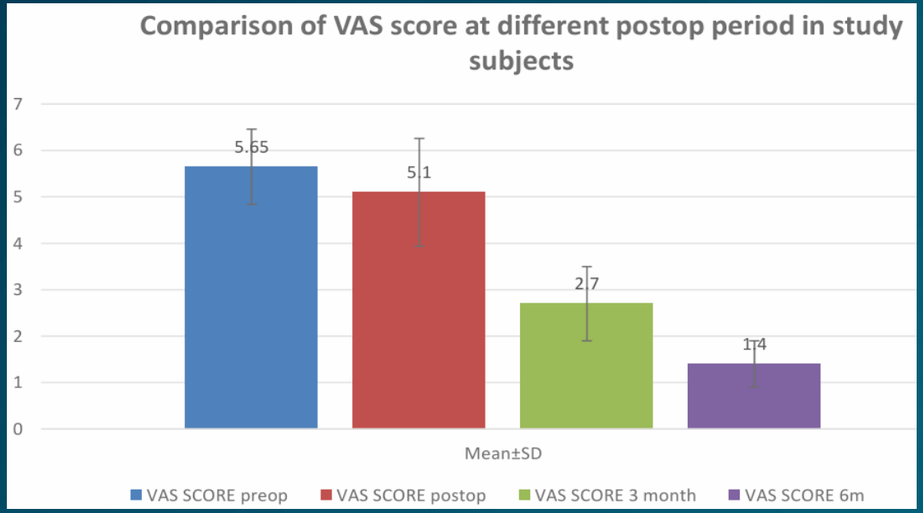
Comparison of VAS score at different postop period in study subjects
7
6
5
4
3
2
1
0
5.65
5.1
2.7
1.4
Mean±SD
VAS SCORE preop
VAS SCORE postop
VAS SCORE 3 month
VAS SCORE 6m

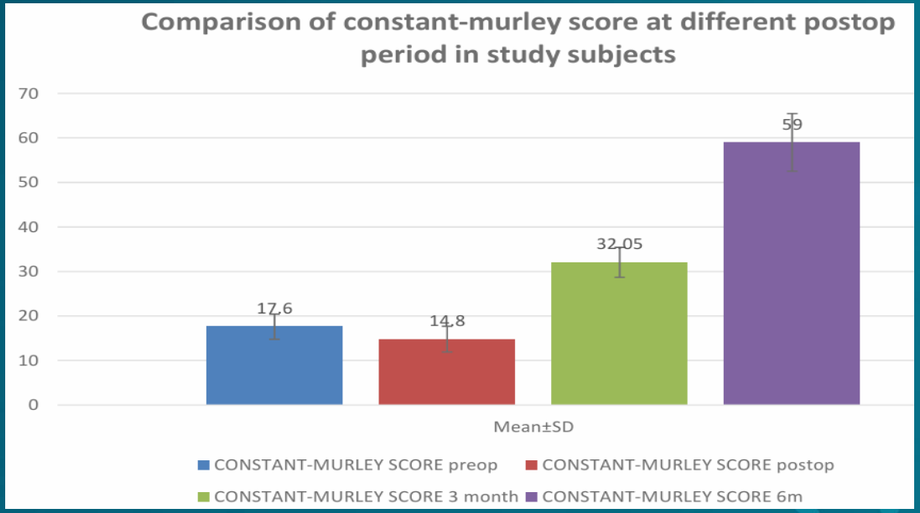
Comparison of constant-murley score at different postop period in study subjects
70
60
50
40
30
20
10
0
17.6
14.8
32.05
59
Mean±SD
CONSTANT-MURLEY SCORE preop
CONSTANT-MURLEY SCORE postop
CONSTANT-MURLEY SCORE 3 month
CONSTANT-MURLEY SCORE 6m

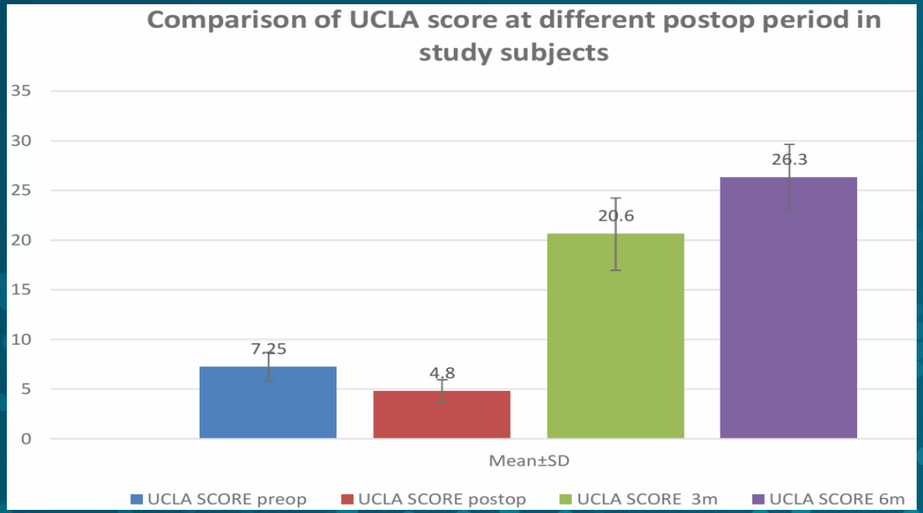
Comparison of UCLA score at different postop period in study subjects
35
30
25
20
15
10
5
0
7.25
4.8
20.6
26.3
Mean±SD
UCLA SCORE preop
UCLA SCORE postop
UCLA SCORE 3m
UCLA SCORE 6m

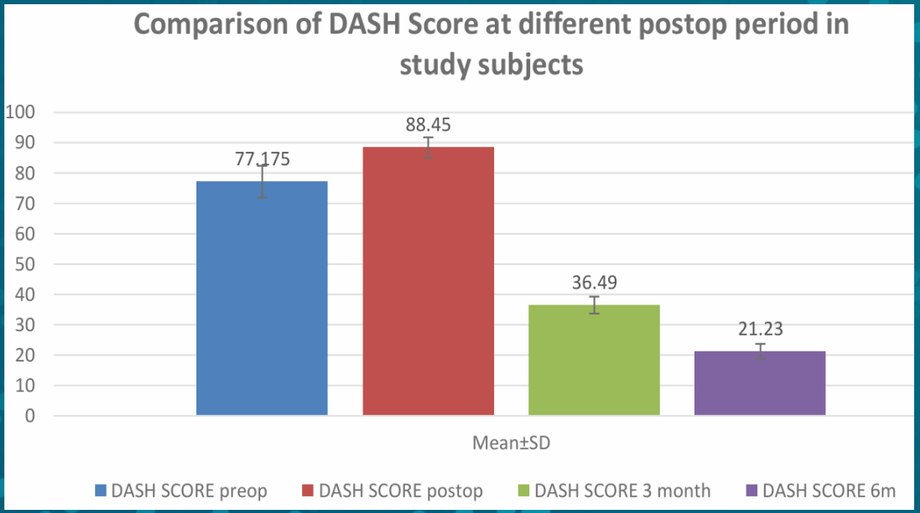
Comparison of DASH Score at different postop period in study subjects
100
90
80
70
60
50
40
30
20
10
0
77.175
88.45
36.49
21.23
Mean±SD
DASH SCORE preop
DASH SCORE postop
DASH SCORE 3 month
DASH SCORE 6m

Discussion and Critical Analysis

- **Interpretation of Results:**

✓ PRP augmentation appears to enhance the biological healing environment by providing growth factors that support tendon repair.

✓ The technique may offer a reduction in re-tear rates and improved clinico-radiological outcomes.

- **Comparisons with Literature:**

✓ Findings are consistent with several studies indicating improved tendon healing with PRP, though some studies report controversial results.

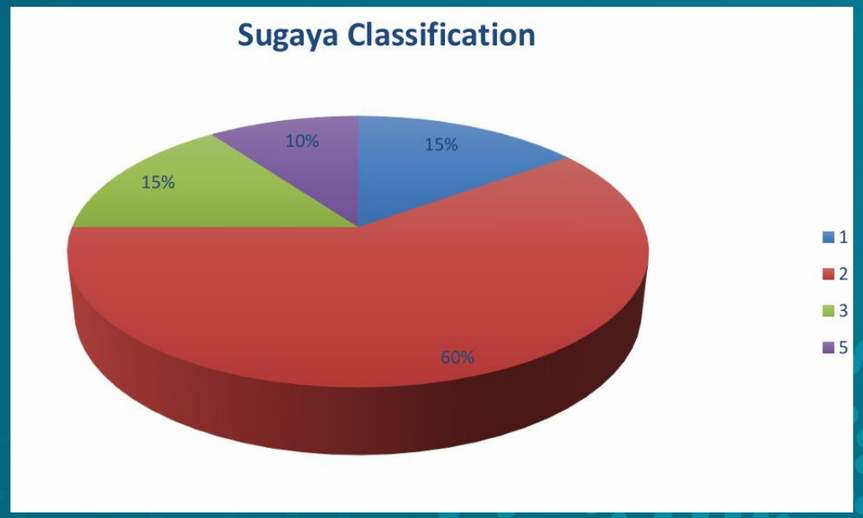

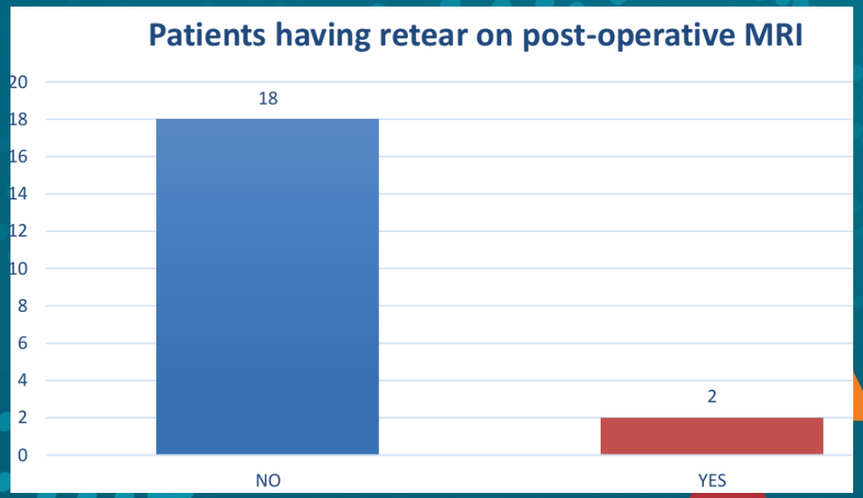

Conclusion & Clinical Implications

- **Conclusion:**

✓ The positive functional outcomes, pain relief, and improved tendon healing observed in the study support the potential benefits of PRP as an adjuvant therapy in rotator cuff repair.

✓ PRP may reduce the risk of re-tears and accelerate the healing process in rotator cuff repair.

- **Clinical Implications:**

✓ Potential adoption of PRP as an adjuvant therapy for Arthroscopic rotator cuff repair.

✓ Enhanced patient satisfaction and quicker rehabilitation are key benefits.

References

- Cofield RH. Rotator cuff disease of the shoulder. *J Bone Joint Surg.* 1985;67(6):974-9.
- Dang A, Davies M. Rotator cuff disease: treatment options and considerations. *Sports Med Arthrosc Rev.* 2018;26(3):129-33.
- Lang S, Loibl M, Herrmann M. Platelet-rich plasma in tissue engineering: hype and hope. *Eur Surg Res.* 2018;59(3-4):265-75.
- Poff, G.; Spencer, E.; Scott, B.; Sleadd, R.; Broyles, J. Comparison of Clinical Outcomes after Platelet-Rich Plasma and Rotator Cuff Repair in High-Grade Intrasubstance Partial Rotator Cuff Tears. *J Clin Med.* 2023, 12, 5554.
- Trantos, I.A.; Vasiliadis, E.S.; Giannoulis, F.S.; Pappa, E.; Kakridonis, F.; Pneumaticos, S.G. The Effect of PRP Augmentation of Arthroscopic Repairs of Shoulder Rotator Cuff Tears on Postoperative Clinical Scores and Retear Rates: A Systematic Review and Meta-Analysis. *J Clin Med.* 2023, 12, 581.
- Poff, G.; Spencer, E.; Scott, B.; Sleadd, R.; Broyles, J. Comparison of Clinical Outcomes after Platelet-Rich Plasma and Rotator Cuff Repair in High-Grade Intrasubstance Partial Rotator Cuff Tears. *J Clin Med.* 2023, 12, 5554.
- Yao L, Pang L, Zhang C, et al. Platelet-Rich Plasma for Arthroscopic Rotator Cuff Repair: A 3-Arm Randomized Controlled Trial. *Am J Sports Med.* 2024;52(14):3495-3504.