The Effectiveness of Hindfoot Endoscopic Surgery for Posterior Ankle Impingement Syndrome due to Os Trigonum in High-level Athletes

Suzuki N[1,3], Matsumae Y[1], Morimoto S[2], Morio F[1]
Nakamura M[1], Nakayama H[2], Tachibana T[3], Iseki T[2]

1. Graduate School, Hyogo medical University
2. Hyogo Medical University Dept. Of Orthopaedic Surgery
3. Osaka Kaisei Hospital

COI

Nobuyoshi Suzuki, MD

I have no financial conflicts to disclose

E-mail : nobuyoshi.suzuki0719@gmail.com

Hyogo medical University
Dept. of Orthopaedic Surgery
TEL : 0798-45-6111
FAX : 0798-45-6932

Posterior Ankle Impingement Syndrome (PAIS)

- ✓ Common among ballet dancers and soccer players.
- ✓ A condition characterized by posterior ankle pain in plantarflexion.
- ✓ Causes include osseous lesions and soft tissue lesions.

Yasui Y World J Orthop. 2016

Hindfoot Endoscopic Surgery for PAIS

- ✓ Low risk of complications.
- ✓ Early return to sports（RTS）.

  Georgiannos D Am J Sports Med. 2017

- ✓ Common surgical treatment for PAIS in Athletes.

Purpose

To evaluate the clinical outcomes of hindfoot endoscopic surgery for PAIS due to Os Trigonum in High-level Athletes.

Material-Method

- ✓ March 2018 ～ May 2023
- ✓ Athletes underwent hindfoot endoscopic surgery for PAIS due to Os Trigonum.
- ✓ Tegner activity score ≧ 7
- ✓ Postoperative follow-up ≧ 6months

↓

16 case

↓

To evaluate the effect of Os Trigonum size, the subjects were categorized into two groups.

Material-Method

✓ Surgical technique

- All cases operated using the technique with two posterior portals.

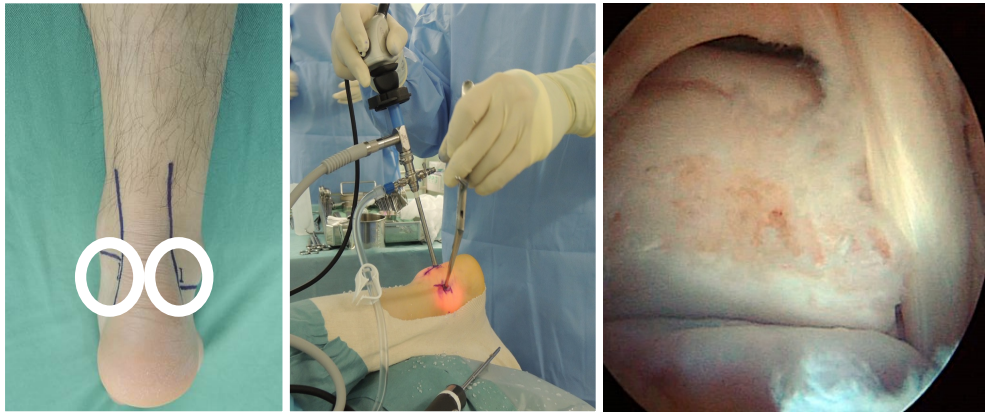

van Dijk CN. Arthroscopy 2000

✓ Postoperative Rehabilitation Protocol

- Postoperative external fixation was not used.
- Ankle range of motion (ROM) training was started from the day after surgery.
- Full weight-bearing was allowed according to pain tolerance.
- Jogging was started at 4 weeks postoperatively.
- RTS was permitted after 6 weeks if pain and function had improved.

Material-Method

✓ Clinical Evaluation

- Visual Analogue Scale (VAS)
- JSSF scale

} @ Pre-operation, Final follow-up

- Period of RTS at pre-injury level
- Complications

✓ Comparison of clinical outcomes between the two groups

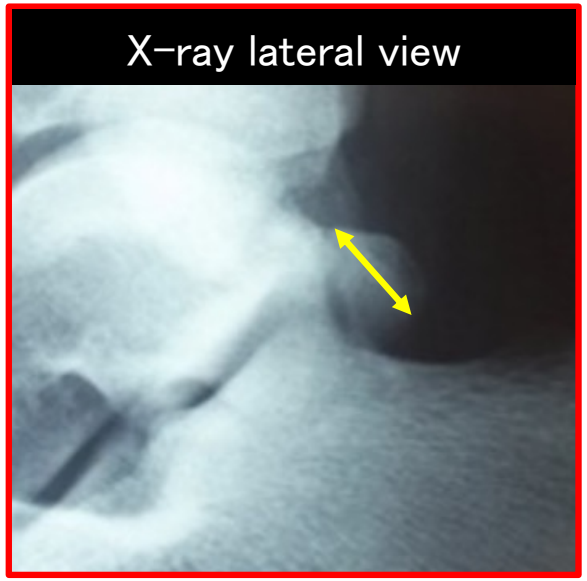

- Size ≧ 10mm → L Group
- Size < 10mm → S Group

Size
||
maximum diameter (mm)

Result

Patient demographics

	L Group (8 case)	S Group (8 case)	*P* value
Age (years)	33.4±5.0	27.2±5.0	0.40
Sex, male/female (n)	6/2	6/2	1.0
Side, right/left (n)	3/5	5/3	0.62
BMI (kg/m^2)	25.6±6.4	24.5±5.4	0.73
Tegner activity score	8.4±1.2	8.3±1.0	0.82
Follow-up (months)	28.6±21.3	36.0±24.1	0.52
Size of Os Trigonum (mm)	12.2±1.5	6.2±1.4	<0.05

Result

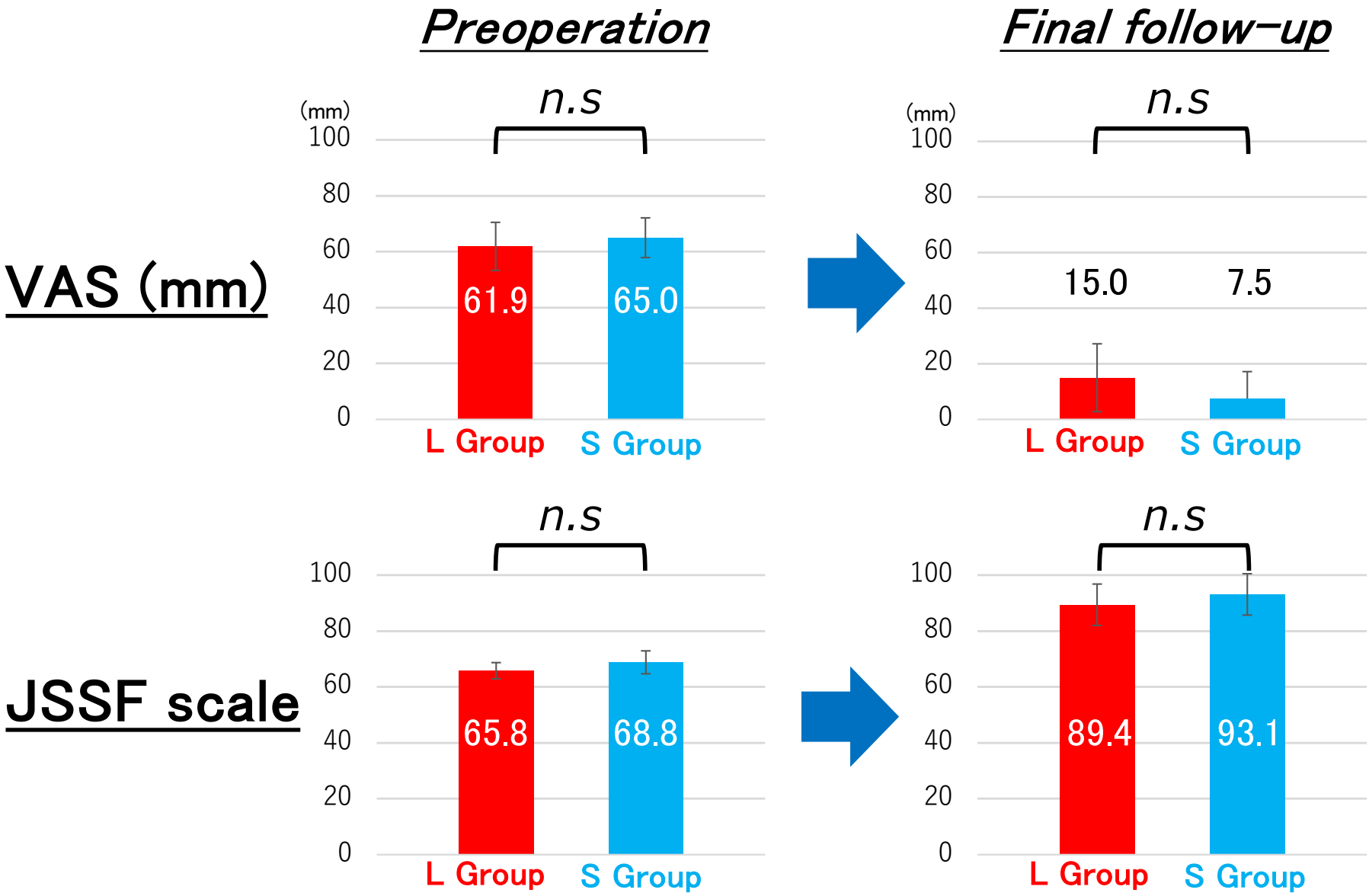
Preoperation
Final follow-up
VAS (mm)
JSSF scale
(mm)
n.s
100
80
60
40
20
0
61.9
65.0
15.0
7.5
65.8
68.8
89.4
93.1
L Group
S Group

Result

Time to RTS

Average:

13.6±3.5 week

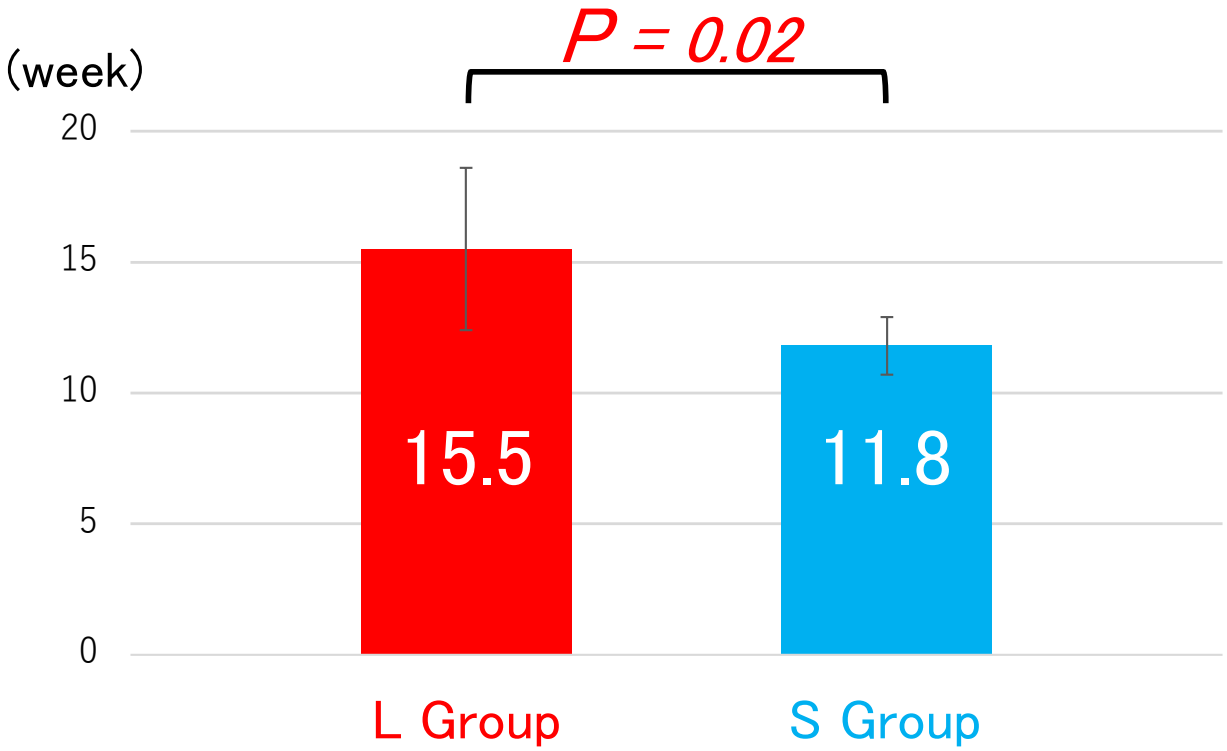

Complications

0/16 case

Conclusion

- ✓The clinical outcomes of hindfoot endoscopic surgery for PAIS with Os Trigonum in athletes were good.

- ✓A larger Os Trigonum might delay the return to sports.

References

1. Yasui Y., et al.: Posterior ankle impingement syndrome: A systematic four-stage approach. World J Orthop. 2016 Oct 18;7(10):657-663.

2. Giannini S., et al.: Posterior ankle impingement. Foot Ankle Int. 2013 Mar;34(3):459-65.

3. Georgiannos D., et al.: Endoscopic Versus Open Excision of Os Trigonum for the Treatment of Posterior Ankle Impingement Syndrome in an Athletic Population: A Randomized Controlled Study With 5-Year Follow-up. Am J Sports Med. 2017 May;45(6):1388-1394.

4. van Dijk CN., et al.: A 2-portal endoscopic approach for diagnosis and treatment of posterior ankle pathology. Arthroscopy. 2000 Nov;16(8):871-6.

5. Anastasio AT., et al.: The Utilization of Minimally Invasive Surgery for Os Trigonum Syndrome: A Systematic Review. Am J Sports Med. 2024 Jul;52(8):2168-2177.