ISAKOS
15th Biennial Congress 2025

RADIOLOGICAL EVALUATION OF GLENOID BONE REACTIONS FOLLOWING ARTHROSCOPIC BANKART REPAIR USING ALL-SOFT SUTURE ANCHORS

(ABSTRACT ID: 25171)

Presenting Author: Dr. Vinod Kumar

Co-Author: Dr. Nagendra V

Department of Orthopaedics,
Maulana Azad Medical College, New Delhi, India

ISAKOS 15th Biennial Congress 2025

Presenters Financial Disclosure

- I (or a member of my immediate family) **do not** have a financial interest or other relationship with a commercial company related directly or indirectly with the ***ISAKOS 15th Biennial Congress 2025.***

Introduction

- The Glenohumeral joint instability is one of the most common orthopaedic problem encountered in the current population especially among young, males, athletes and those involved in contact sports.
- **Anterior dislocation** is the most frequent type of shoulder instability accounting to about 90% of the total case.
- Arthroscopic Bankart repair with suture anchors has been the gold standard in the management of glenohumeral instability since the recent few decades.
- There have been many developments and advances in the structure of these suture anchors starting from metallic anchors to bio-composite to the recent all soft suture anchors.

ALL SOFT SUTURE ANCHORS

- Reduced bone resection due to smaller drill hole compared to classical suture anchors (1.4mm vs 3mm)
- Good mechanical resistance
- Ultimate load-to-failure equivalent to that of solid anchor systems
- Equivalent clinical results

Aim of the Study

- Qualitative and quantitative evaluation of the glenoid bone reactions following the usage of all soft suture anchors technique in arthroscopic Bankart repair, at different post-operative time periods using Non Contrast enhanced Computed Tomography scans

Methodology

➢ **STUDY DESIGN:** Longitudinal study

➢ INCLUSION CRITERIA

- Post traumatic recurrent anterior shoulder dislocation with Bankart lesion treated with arthroscopic Bankart repair using all soft suture anchors with a minimum of six months follow-up post surgery
- Age group: 15 to 60 years of either sex at the time of surgery

➢ EXCLUSION CRITERIA

All those patients with Bankart lesion treated with arthroscopic Bankart repair using all-soft suture anchors in whom

- Revision surgery was done in the post-operative follow-up period
- Infection (or) Inflammation at the operated site post-surgery
- Re-trauma (or) Fracture of (or) near the operated site post-surgery during the follow-up period
- Refrained from giving their consent to the proposed study

- All patients underwent CT scan of the operated Gleno-humeral region using 128 slice MDCT Scanner.
- CT scan was limited to 6-8 centimetres distance spanning the glenohumeral joint with 1 mm slice thickness.
- Obtained images were anonymized and imported to DICOM viewer and then evaluated for the presence (or) absence of glenoid bone reactions and if present, the dimensions of the lesions were measured and further quantified.
- The patient were asked to follow-up at **six months and twelve months post-operatively** in order to obtain sequential CT images of his/her operated shoulder.

- Glenoid bone reactions encompass the spectrum of various clinical and radiological changes that occur following arthroscopic Bankart repair. It includes changes like *partial bony erosions, tunnel expansions, cystic changes, etc.*

- *Quantification of glenoid bone reactions were graded as Grade 0 being complete resolution of the drilled tunnel, Partial defects or erosions (grade 1), Tunnel dilation (grade 2) and peri-anchor cystic changes (grade 3).*

- **Tunnel expansion** will be defined as "a cylindrical increase in the diameter along the length of the drilled tunnel"

- **Cystic changes** will be defined as "a non-uniform change at any point along the drilled path".

- Any tunnel not visualized on CT scan will be presumed to have undergone complete ossification.

- **Tunnel diameter** is defined as *"the greatest width of the hole along the suture anchors among axial, sagittal and oblique coronal plane.*
- In axial and oblique coronal plane, the longest distance between the two points based on intersection of the axis and line perpendicular to the axis will be regarded as the width of the hole.
- In sagittal plane, the width will be defined as the largest diameter of the hole measured in the circle that was in contact with the border of the anchor tunnel.

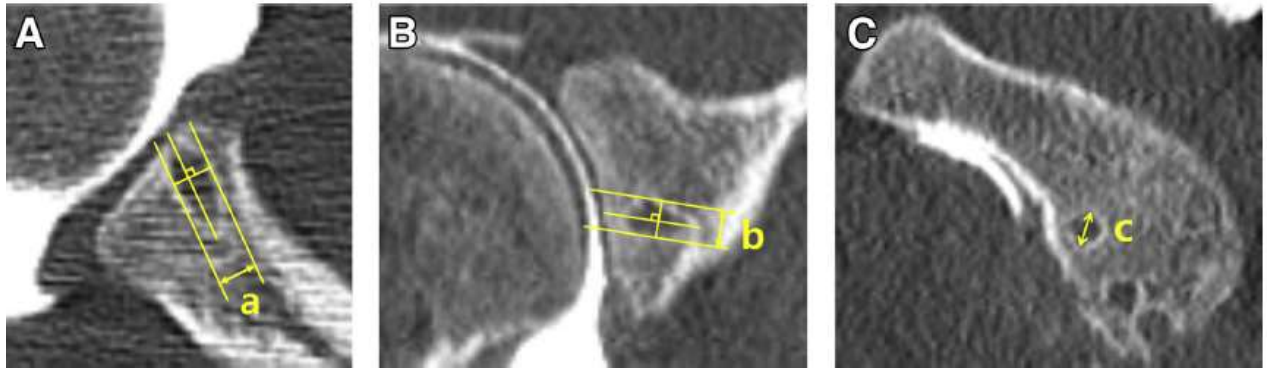

RESULTS

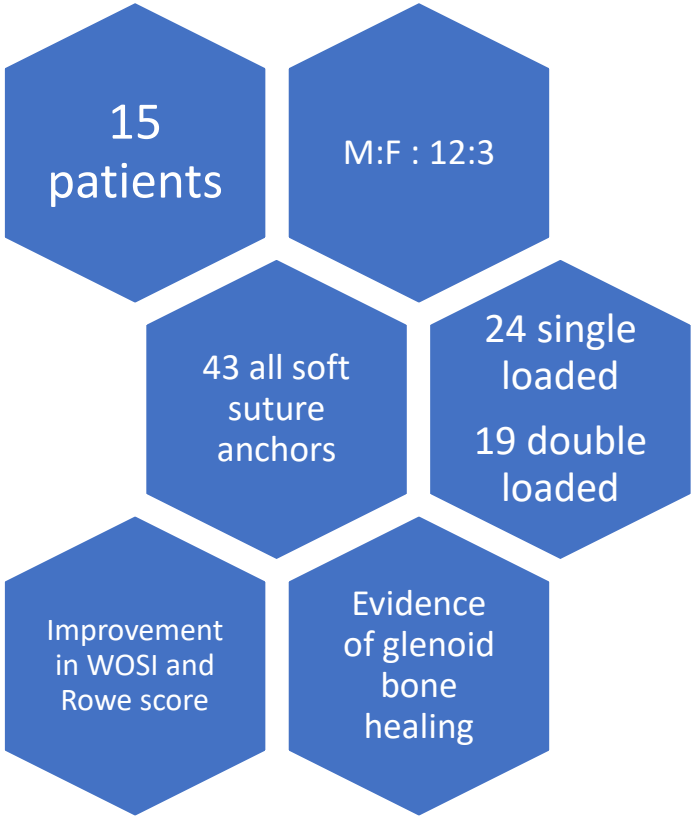
15 patients
M:F : 12:3
43 all soft suture anchors
24 single loaded
19 double loaded
Improvement in WOSI and Rowe score
Evidence of glenoid bone healing

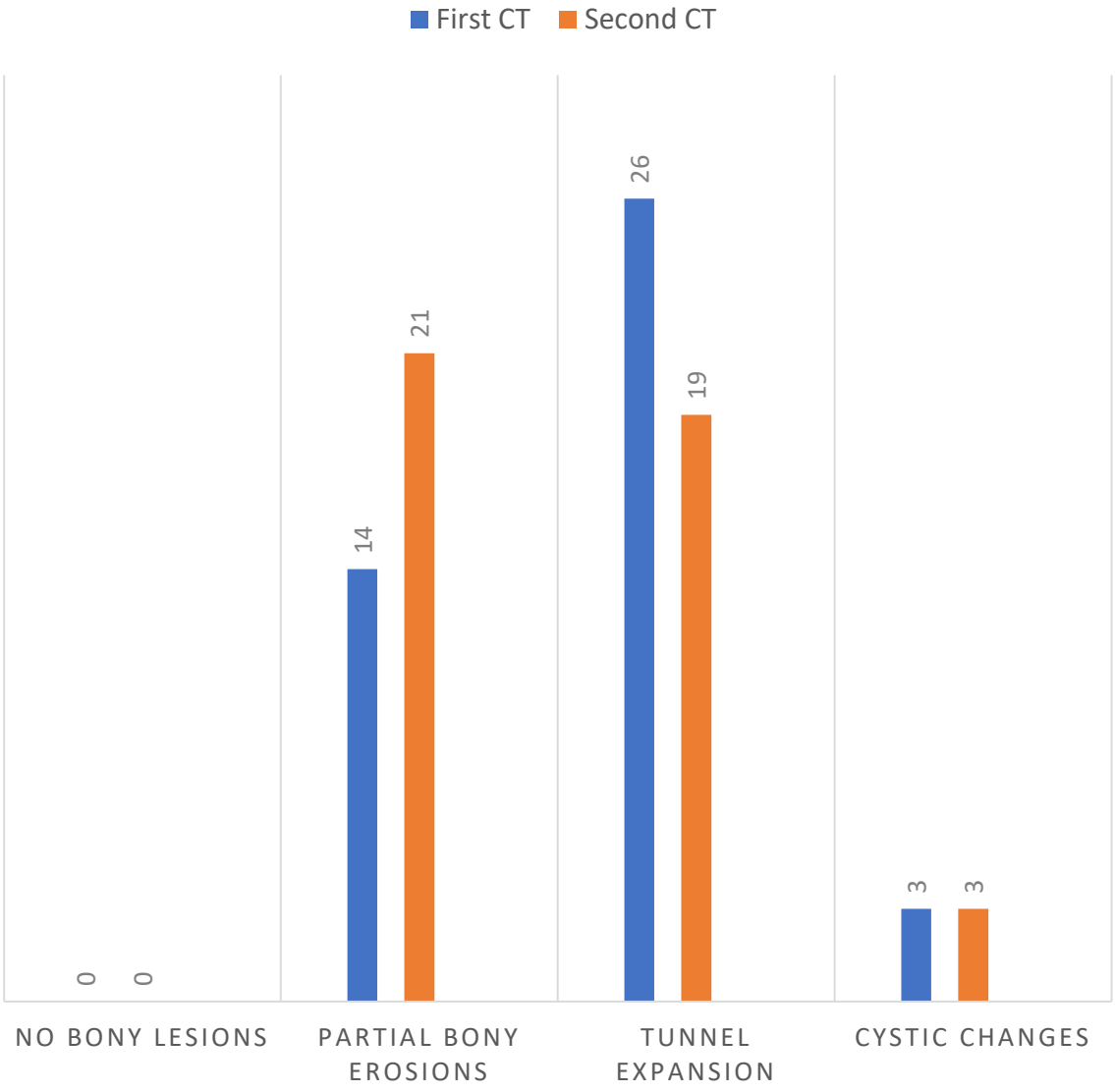
First CT
Second CT
0
0
14
21
26
19
3
3
NO BONY LESIONS
PARTIAL BONY EROSIONS
TUNNEL EXPANSION
CYSTIC CHANGES

DISCUSSION

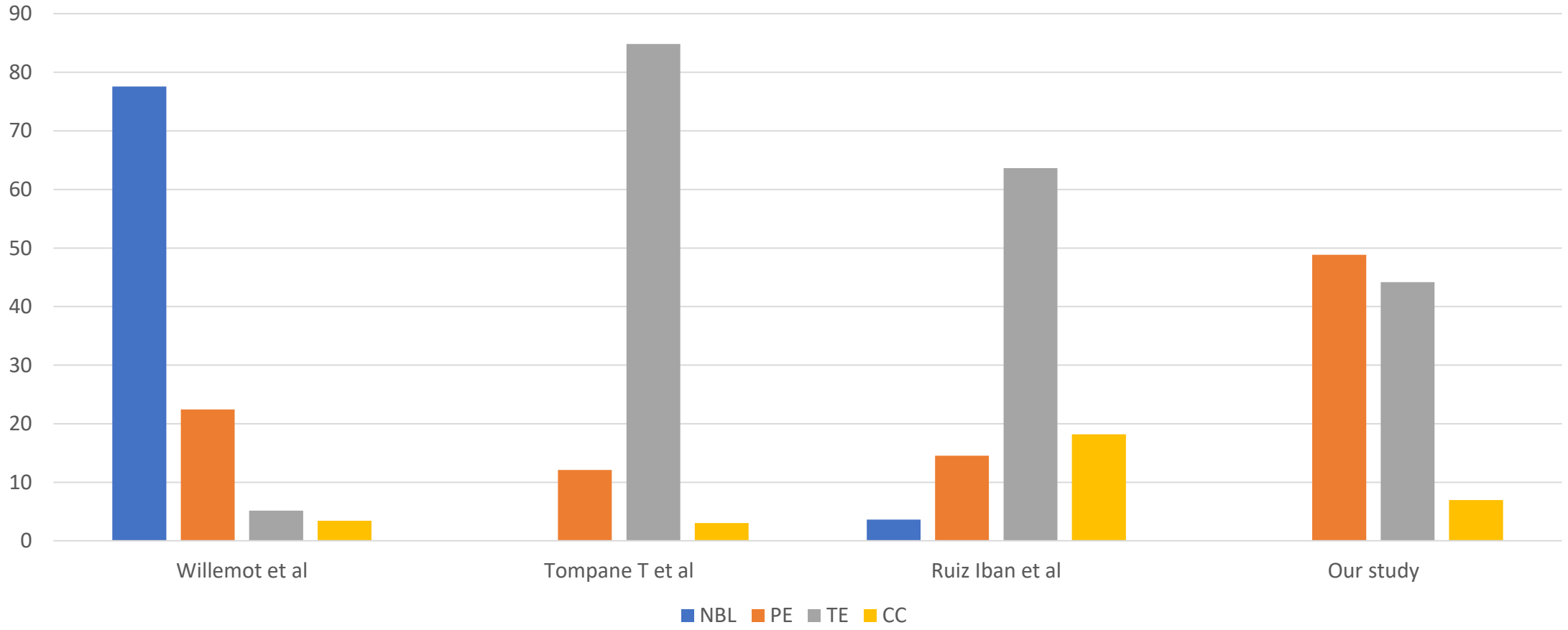
90
80
70
60
50
40
30
20
10
0
Willemot et al
Tompane T et al
Ruiz Iban et al
Our study
NBL
PE
TE
CC

CONCLUSION

- Each of the patients having All soft suture anchors were associated with some changes in the glenoid bone following insertion. However there is no uniformity in pattern of glenoid bone reactions on subsequent follow-ups.
- Number of patients having Grade 2 changes have a tendency to decrease over time which is suggestive of healing response. (60.46% at 6 months to 44.19% patients at 1-year follow-up)
- The grade 3 changes does not show any healing response and remained constant throughout follow-up.
- We would advocate further long-term studies to evaluate the long –term healing potential of glenoid bone reactions.

References

1. RuizIban MA, Rodriguez RV, Heredia JD, Exposito RP, Diaz RR, Paredes IZ. Arthroscopic Bankart repair with all-suture anchors does not cause important glenoid bone osteolysis: a volumetric CT study of 143 anchors. Springer. 2020.

2. Lee JH, Park I, Hyun HS, Kim SW, Shin SJ. Comparison of clinical outcomes and CT analysis for Tunnel diameter after arthroscopic Bankart repair with the all-suture anchor and the biodegradable suture anchor. Arthroscopy. 2019;35(5):1351-9.

3. Tompane T, Carney J, Wu WW, Nguyen-Ta K, Dewing C, Provencher M et al. Glenoid bone reaction to all-soft suture anchors used for shoulder labral repairs. Am J Bone Joint Surg. 2018;100(14):1223-9.

4. Park YJ, Lee SJ, Lhee SH, Lee SH. Follow up computed tomography arthrographic evaluation of bony Bankart lesion after arthroscopic repair. Arthroscopy. 2012;28(4):465-73.

5. Willemot L, Elfadalli R, Jaspars KC, Ahw MH, Peeters J, Jansen N et al. Radiological and clinical outcome of arthroscopic labral repair with all-suture anchors. Acta Orthop Belg. 2016 Aug 1;82(2):174-8.