ACL graft elongation during downhill running over a 10-year follow-up

Koji Nukuto[1,2], Tom Gale[1], Anja M. Wackerle[1,3], James J. Irrgang[4], Stephen Rabuck[1], Volker Musahl[1], William Anderst[1]

1. Department of Orthopaedic Surgery, University of Pittsburgh Medical Center
2. Department of Orthopaedic Surgery, Kobe University Graduate School of Medicine
3. Department of Sports Orthopaedics, Klinikum Rechts der Isar, Technical University of Munich
4. Department of Physical Therapy, University of Pittsburgh

UPMC LIFE CHANGING MEDICINE

Department of Orthopaedic Surgery

BDL BIODYNAMICS LABORATORY

University of Pittsburgh

Disclosures

- V. M. reports educational grants, consulting fees and speaking fees from Smith & Nephew plc and educational grants from Arthrex and DePuy/Synthes, is a board member of the International Society of Arthroscopy, Knee Surgery and Orthopaedic Sports Medicine (ISAKOS) and deputy editor-in-chief of Knee Surgery, Sports Traumatology, Arthroscopy (KSSTA).

- J.J.I. is a board of directors for Movement Sciences Media/Journal of Orthopaedic and Sports Physical Therapy (JOSPT).

Background

- Anterior cruciate ligament reconstruction (ACLR) is the gold standard for treatment of ACL injuries, but residual instability is one of the postoperative issues after ACLR [1].

- The association between *in vivo* ACL elongation and kinematics/bone morphology has been reported over the short term (2 years) [2,3].

There is a lack of evidence on the change in ACL graft length at long-term follow-ups.

Study Aim

- Evaluate long-term changes in ACL graft length during downhill running

Hypothesis

- ACL graft length does not change over time, and it is not different compared to the contralateral native ACL at ≥10-year follow-up after ACLR.

Data collection

- Five patients (4 male, 1 female)
- Anatomic double-bundle ACLR at least 10 years ago with a quadriceps tendon autograft [4,5,6]
- Biplane radiographs during downhill running (10° slope) at 6, 24 months, and ≥10 years after ACLR (Fig A, B)
- Bilateral CT scans (Fig C, D)
- 3T MRI of the knees

Patient demographic

Number (male)	5 (4)
Age (years)	22.8±6.6
BMI (kg/m^2)	26.7±1.0
Follow-up (years)	12.9±0.3

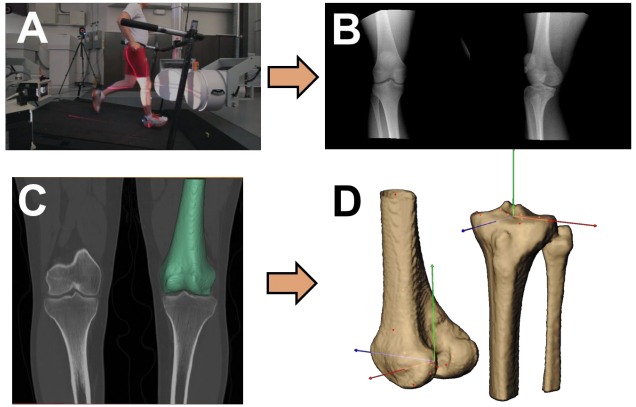

Data processing

- Tibiofemoral motion was tracked by a previously validated volumetric model-based tracking process [6] (Fig E).

- Knee kinematics during the stance phase of the gait cycle were calculated following standard conventions [7] (Fig F).

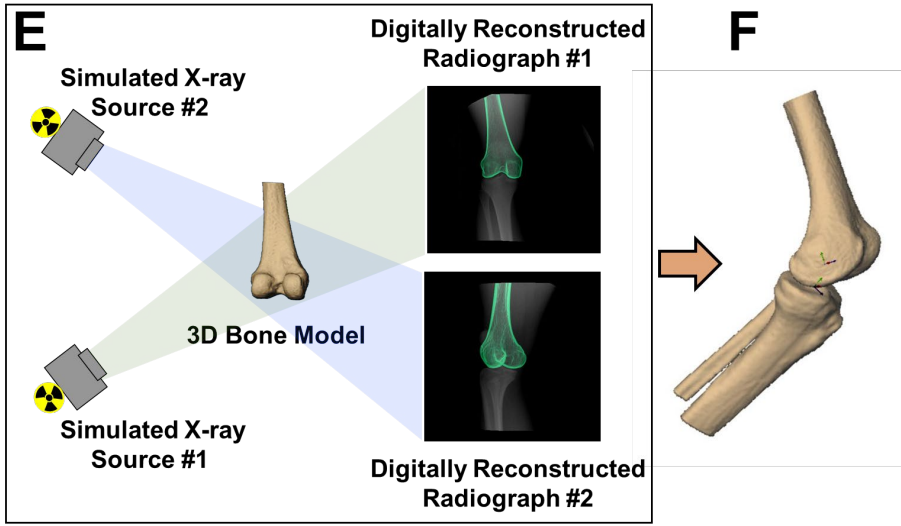

ACL length

- Surgical side ACL length
  - ➢ The distance between the femoral and tibial apertures of the bone tunnels
- Contralateral side ACL length
  - ➢ The distance between the femoral and tibial ACL insertions [8]
  - ➢ The AM and PL bundle (AMB and PLB) at the midpoint of the ACL insertion [2,9] (Fig A,B)
- ACL lengths were normalized to their respective MRI lengths (Relative elongation).

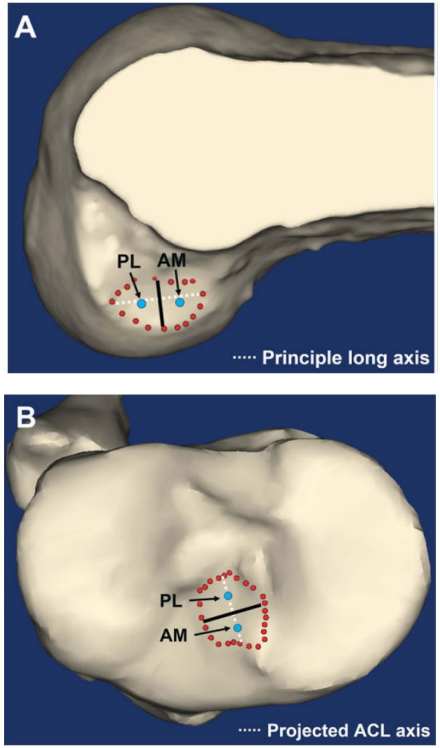

[9]

Statistical Analysis

- ACL graft length in the surgical side at ≥10-year follow-up
  - ➢ vs 6 and 24 months after ACLR (Change over time)
  - ➢ vs The contralateral side at ≥ 10-year follow-up (5° increments of tibiofemoral flexion)

✓ Linear mixed effects models
✓ Significance set at $p<0.05$.

Results (Change over time)

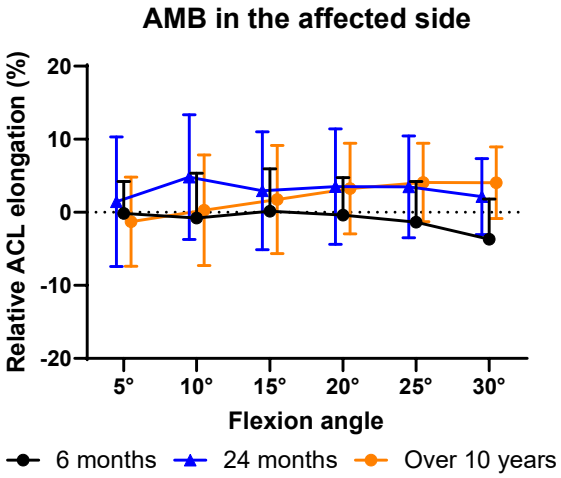

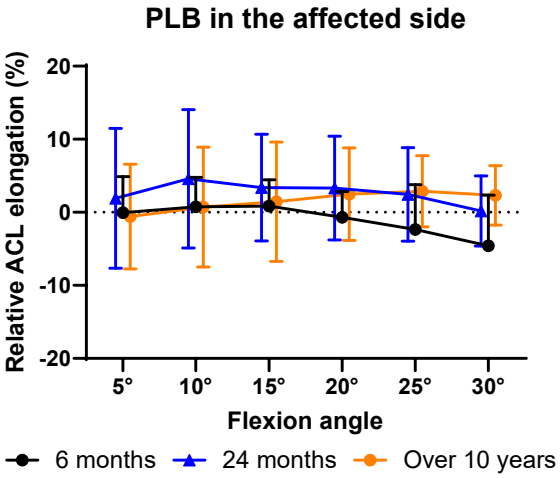

- The mean relative elongation at 6 months was consistently less than at 24 months and ≥10 years
- However, no statistically significant differences were found.

Results (Surgical vs Contralateral)

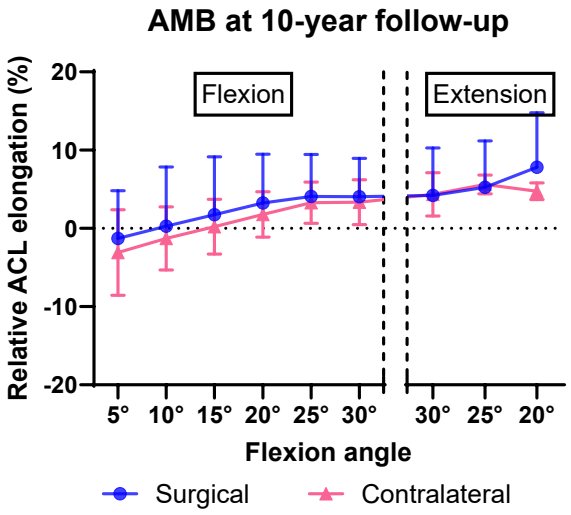

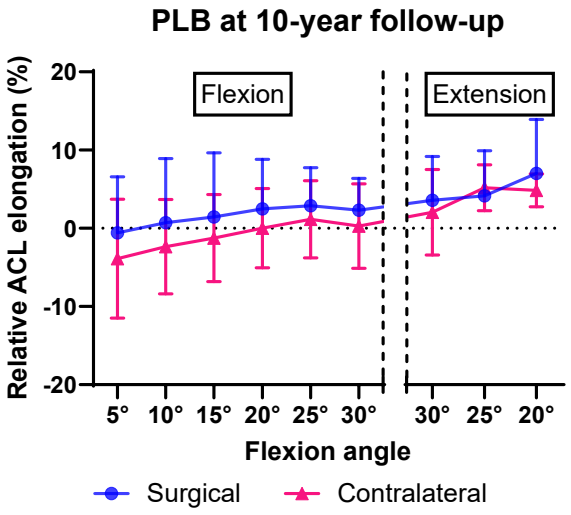

- At ≥10-year follow-up, both bundles showed similar relative elongation patterns on the surgical and contralateral side

Discussion

- In this study, no difference in ACL relative elongation could be detected between 6 month, 24 months or 10-years after ACLR
- There was no difference between the surgical and contralateral side for both bundles at ≥10-year follow-up.

➢ ACL graft tension might be still preserved more than 10 years after DB ACLR.

➢ The tension in both bundles was maintained at the same level as on the contralateral side.

Clinical significance

- During downhill running, anatomic DB ACL graft elongation does not change even at 10-year follow-up
- AMB and PLB graft elongations closely replicate contralateral native AMB and PLB elongation 10 years after ACLR.

References

[1] Loucas, et al., OJSM, 2021. [2] Nishida, et al., JOR. 2022.
[3] Nukuto, et al., JOR. 2024. [4] Tashman, et al., KSSTA. 2021.
[5] Irrgang, et al., KSSTA. 2021. [6] Anderst, et al., Med Eng Phys, 2009.
[7] Grood and Suntay, J. Biomech. Eng., 1983.
[8] Araki, et al., KSSTA. 2018. [9] Nagai, et al., JOR. 2019.

This work was supported by NIH Grant R01 AR056630.