ISAKOS CONGRESS 2025 | MUNICH GERMANY June 8–11

Successful Outcomes in Combined Unicompartmental Knee Arthroplasty and Anterior Cruciate Ligament Reconstruction : A Clinical Study

Theodore Balfousias [1] , MD, MSc, FEBOT, Thessaloniki GREECE

Ilias Fanourgiakis [1], MD, MSc, FEBOT, Melissia, Athens GREECE

Rainer Siebold [1], Prof. Dr. med., Heidelberg GERMANY

1 International Center for Orthopedics, ATOS Clinic, Heidelberg, Germany

Faculty Disclosure Information

- Conflicts of Interest:
  - None declared by any of the authors

Objectives

The management of advanced osteoarthritis, which is isolated to a single knee compartment and accompanied by anterior cruciate ligament (ACL) deficiency, continues to be a subject of ongoing discussion among orthopedic surgeons. UKA is a common method of treatment for osteoarthritis (OA) of a single compartment of the knee, while the reconstruction of the cruciate ligament can restore the knee kinematics close to an ACL-intact knee. A combination of UKA and ACLR, either staged or simultaneously, seems like a promising treatment option. The purpose of this study is to evaluate the clinical outcomes and the patient satisfaction after combined UKA and ACLR.

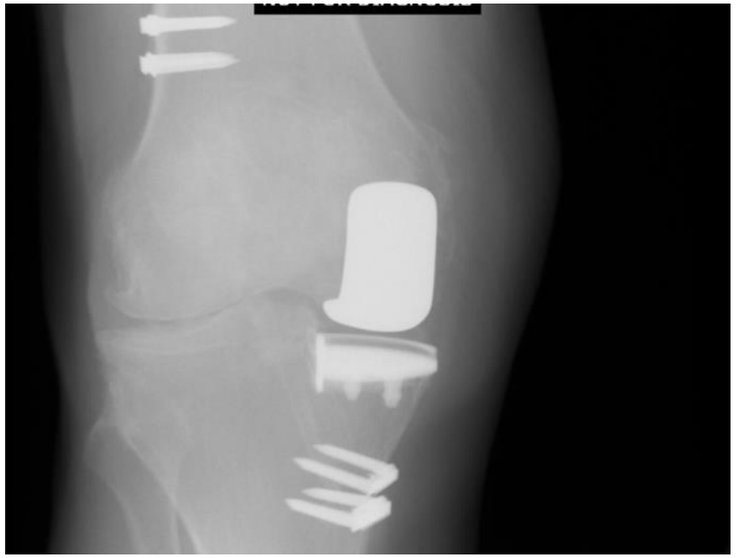

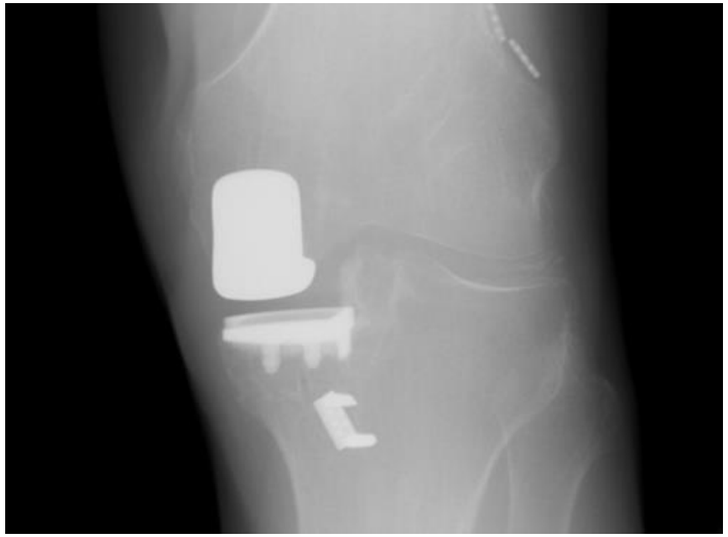

Methods

Twenty-two patients with ACL deficiency and concomitant medial or lateral knee OA were treated from 2011 to 2022 with a combined UKA (Journey Unilateral Knee System) and ACLR using tendon autograft (Semi-T, Quadriceps-, Patella-Tendon). The follow-up assessment included Lysholm score, Knee Injury and Osteoarthritis Outcome Score - KOOS (symptoms, pain, Sports, ADL: activities of daily living, QoL: quality of life, Total), International Knee Documentation Committee (IKDC 2000), Tegner activity scale and VAS score for pain and satisfaction. Revisions to total knee arthroplasty (TKA) were documented. Survivorship analysis was performed using the Kaplan–Meier method.

Results

Average follow-up was 6 ± 3.1 years (1.2-11.5). The mean age was 57.9 ± 8.1 years (40-72) with 5 female and 17 male patients. Twenty-one medial, one lateral, and 18 single bundle, 4 double bundle procedures were performed. Fourteen of 22 procedures were carried out simultaneously. Staged procedures were performed with a maximum time interval of 12 months (1-12). All scores improved significantly, with exception of the Tegner activity score. Implant survivorship was 76.2% at 11.5 years. Three revisions with conversion to total knee arthroplasty were performed at 5, 5.2 and 6.8 years postoperatively. Reasons for revisions were loosening of the femoral component, posterior polyethylene wear and OA progression at the other condyle. In the remaining 19 knees there were no observations of radiological component loosening or clinical signs of ACL instability.

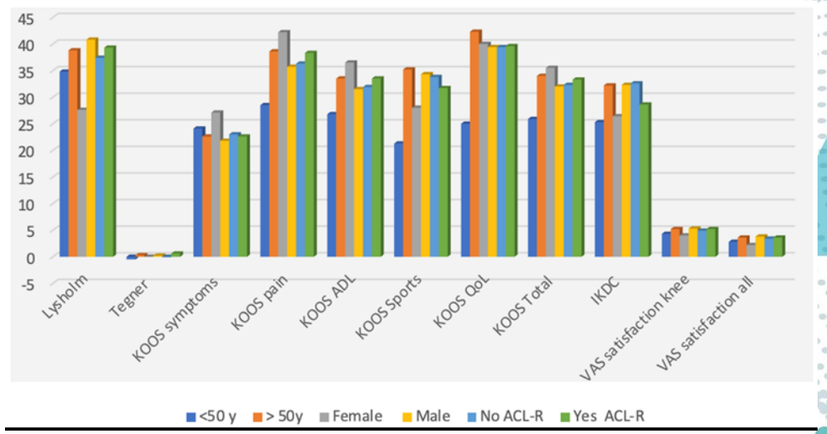

Difference of pre- and postoperatively measured outcome scores.

Improvement in postoperatively measured outcomes

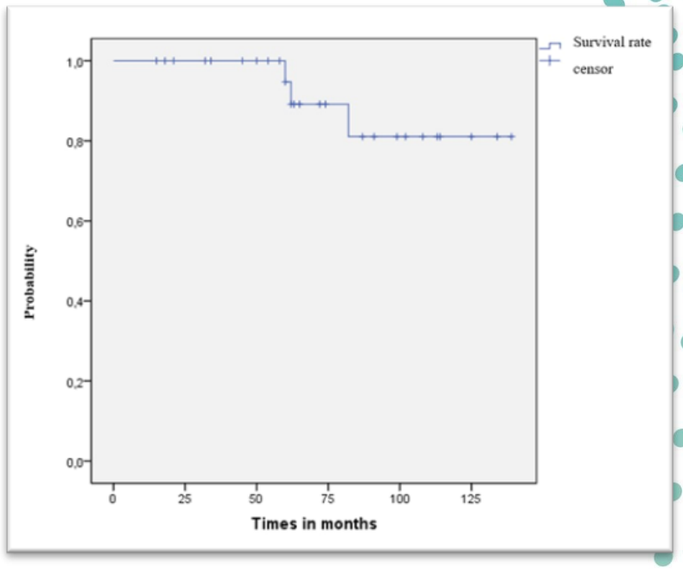

Kaplan-Meier curve displaying the survival rate of primary implants {95% Confidence Interval [CI]}

Conclusion

- UKA combined with ACL reconstruction can be a valid treatment option with good clinical results for selected patients in short to midterm follow-up. It can restore knee stability and address the advanced single compartment arthritis. It is though a technically challenging procedure and experience is required in both surgical techniques. Careful patient selection and meticulous surgical technique are essential to ensure successful outcomes.

References

- Demey, G.; Magnussen, R.A.; Lustig, S.; Servien, E.; Neyret, P. Total Knee Arthroplasty for Advanced Osteoarthritis in theAnterior Cruciate Ligament Deficient Knee. Int. Orthop. 2012, 36, 559–564.
- Mancuso F, Hamilton TW, Kumar V, Murray DW, Pandit H. Clinical outcomeafter UKA and HTO in ACL deficiency: a systematic review. Knee Surg SportsTraumatol Arthrosc. 2014.
- Aslan H, Çevik HB. Outcomes of Combined Unicondylar Knee Arthroplasty and Anterior Cruciate Ligament Reconstruction. J Knee Surg. 2022
- Kennedy JA, Molloy J, Mohammad HR, Mellon SJ, Dodd CAF, Murray DW. Mid- to long-term function and implant survival of ACL reconstruction and medial Oxford UKR. Knee. 2019
- Pandit H, Van Duren BH, Gallagher JA, Beard DJ, Dodd CA, Gill HS, Murray DW. Combined anterior cruciate reconstruction and Oxford unicompartmental knee arthroplasty: in vivo kinematics. Knee. 2008
- Tecame A, Savica R, Rosa MA, Adravanti P. Anterior cruciate ligament reconstruction in association with medial unicompartmental knee replacement: a retrospective study comparing clinical and radiological outcomes of two different implant design. Int Orthop. 2019