A randomized control study to evaluate the efficacy of intra-articular, subacromial steroid and PRP injection in Primary Adhesive Capsulitis

Dr Ankit Kataria

MBBS, MS (Orthopaedics), DNB, MNAMS, PGD-HM

Assistant Professor

Government Institute of Medical Sciences,

Greater Noida, Uttar Pradesh, India

ISAKOS CONGRESS 2025 | MUNICH GERMANY June 8–11

Faculty Disclosure Information

- Nothing to disclose

Acknowledgements

- Dr Ashok Kumar, Professor, Department of Orthopaedics, Government Institute of Medical Sciences, Greater Noida, Uttar Pradesh, India
- Dr Vikas Saxena, Professor, Department of Orthopaedics, Government Institute of Medical Sciences, Greater Noida, Uttar Pradesh, India

INTRODUCTION

- Adhesive capsulitis is characterized by painful and global restriction of both active and passive glenohumeral range of motion in at least two directions, most notably shoulder abduction and external rotation.
- It has an incidence of 3%–5% in the general population and up to 20% in those with diabetes.
- Cause ???

Published studies has revealed that it is a diffuse inflammatory process, affecting nearly all the periarticular soft tissue components, such as the joint capsule, subacromial bursae, coracohumeral ligament, rotator interval, axillary recess, and the biceps tendon sheath.

- Corticosteroid injection provide short term symptomatic relief and can be administered via intra-articular or subacromial technique.
- However, the efficacy of the steroid injection via the route of administration is a subject of contention.
- Platelet rich plasma contains growth factors that stimulate tissue repair and has the potential in prophylaxis and treatment of frozen shoulder.

Research Article

Intra-Articular versus Subacromial Corticosteroid Injection for the Treatment of Adhesive Capsulitis: A Meta-Analysis and Systematic Review

Xiaoke Shang,[1,2] Zhong Zhang,[2] Xuelin Pan,[2] Jian Li,[2] and Qi Li[2]

[1]Department of Orthopedic Surgery, People's Hospital of Ningxia Hui Autonomous Region, Yinchuan 750000, China
[2]Department of Orthopedic Surgery, West China Hospital of Sichuan University, Sichuan University, Chengdu, Sichuan 610041, China

???

J Shoulder Elbow Surg (2016) 25, 376–383

ELSEVIER

SHOULDER

Journal of Shoulder and Elbow Surgery

www.elsevier.com/locate/ymse

Intra-articular injection, subacromial injection, and hydrodilatation for primary frozen shoulder: a randomized clinical trial

Jong Pil Yoon, MD[a], Seok Won Chung, MD[b,*], Ju-Eun Kim, MD[a], Hyung Sup Kim, MD[a], Hyun-Joo Lee, MD[a], Won-Ju Jeong, MD[a], Kyung-Soo Oh, MD[b], Dong-Oh Lee, MD[b], Anna Seo, PhD[c], Youngjun Kim, PhD[c]

[a]Department of Orthopaedic Surgery, School of Medicine, Kyungpook National University, Daegu, South Korea
[b]Department of Orthopaedic Surgery, School of Medicine, Konkuk University, Seoul, South Korea
[c]Center for Bionics, Korea Institute of Science and Technology, Seoul, South Korea

Original Research Article

Original Article

Management of Adhesive Capsulitis of Shoulder Joint by Single Platelet Rich Plasma Injection

Alok Chandra Agrawal, Buddhadeb Nayak, Harshal Sakale

Department of Orthopaedics, All India Institute of Medical Sciences, Raipur, Chhattisgarh, India

Single Intra-articular Platelet-Rich Plasma Versus Corticosteroid Injections in the Treatment of Adhesive Capsulitis of the Shoulder

A Cohort Study

Apurba Barman, MD, Somnath Mukherjee, MD, Jagannatha Sahoo, DNB, Rituparna Maiti, MD, Parnandi Bhaskar Rao, MD, Mithilesh Kumar Sinha, MS, Dibyajyoti Sahoo, MD, Sujit Kumar Tripathy, MS, Binod Kumar Patro, MD, and Nerbadyswari Deep Bag, MD

AIMS

- To evaluate the efficacy of three injection methods {Intra-articular steroid, Subacromial steroid and Platelet-rich Plasma (PRP)} in primary adhesive capsulitis.
- To compare the adverse reactions among the three injection methods.

MATERIAL AND METHODS

- Study Design – Randomized control study
- All the patients previously diagnosed with primary adhesive capsulitis and willing to participate in the study after written informed consent were recruited. The study design and proposal was approved from GSRC and Ethical board.
- **Inclusion criteria**:

➢ Symptoms of pain or discomfort were present for 3 months to 1 year

➢ VAS score of <7 of 10 for pain (thus probably in the freezing stage rather than in the inflammatory stage)

➢ Unresponsive to conservative treatment consisting of medication or physical therapy for at least 3 months

- **Exclusion criteria**: Patients with secondary causes of frozen shoulder such as rotator cuff tear or calcific tendinitis, those with Glenohumeral arthritis, those with a history of surgery on the same shoulder, those who received a steroid injection within 6 months before enrolment, and those who refused to participate in the study were excluded.

- Patients were randomized using a computer-generated block randomization sequence (www.randomizer.org) by an independent researcher, and the group assignment was disclosed to the investigator at the time of intended treatment.
- A sample size of 30 patients in each group was required for a power of 90% at type I error level of 0.05, with an expected dropout rate of 20%.
- All patients underwent conservative treatment, including medication and a home-based physical therapy exercise program.
- The medication comprised of an oral nonsteroidal anti-inflammatory drug and muscle relaxant, which was administered for approximately 4 weeks.
- For physical therapy, active assisted ROM exercise, including stick exercise, were performed for approximately 10 weeks, depending on the recovery of ROM.
- Clinical symptoms were evaluated at 4 time points for all patients: before treatment and at 1 month, 3 months, and 6 months after treatment.
- The clinical outcomes were evaluated using the VAS score for pain (range, 0-10, with 10 indicating the worst pain), Constant shoulder score, passive shoulder ROM and Likert satisfaction scale.

Intended intervention, dosage of drug, route of administration, details of invasive procedures

- **Intra-articular steroid Injection (IAI) Group:** a mixture of 1 mL of triamcinolone (40 mg), 4 mL of 2% lidocaine, and 5 mL of normal saline was injected via anterior approach into the glenohumeral joint space slowly and with consistent pressure under fluoroscopic guidance.
- **Sub-acromial steroid Injection (SAI) Group:** a mixture of 1 mL of triamcinolone (40 mg), 4 mL of 2% lidocaine, and 5 mL of normal saline was injected via posterior approach into the subacromial joint space slowly and with consistent pressure under fluoroscopic guidance.
- **Platelet-rich Plasma (PRP) Group:** A volume of 35 ml of blood was drawn from the peripheral vein of the patient undergoing this procedure: centrifugation followed by buffy coat-based PRP harvesting. This yields about 4 ml of PRP, which was injected via posterior approach into the subacromial space slowly and with consistent pressure under fluoroscopic guidance.

PRP Preparation

- The PRP was prepared by the single centrifugation technique in accordance with standard operating procedure.
- 35 ml of venous blood was drawn from the patient's uninvolved arm with an 18-gauge needled syringe, with a single puncture, atraumatically to minimize tissue damage and platelet activation, during blood sampling.
- The blood sample was equally divided into three specially designed disposable bio-kit tubes (PRP Kit) of 12 ml capacity each, containing anticoagulant citrate dextrose-A of 1.5 ml to prevent the coagulation cascade.
- The tubes were centrifuged for 14 mins at 1800 rpm, yielding approximately 6 ml (2 ml in each tube) of PRP.
- Of this, 4 ml of PRP, without adding any buffering or activating agent, was aspirated aseptically from the three tubes.
- The rest of 2 ml PRP was sent for analysis of platelet count by automated cell counter.
- All procedures were performed under sterile conditions. Within 30 mins of preparation, PRP injection was given to the patients.

Fluoroscopic guided Subacromial Injection

ISAKOS CONGRESS 2025 | MUNICH GERMANY June 8–11

RESULTS

Parameters	PRP Group (n=30)	IAI Group (n=30)	SAI Group (n=30)
Sex (male:female)	20:10	11:19	18:12
Age (yr)	51.0 ± 4.62	49.1 ± 6.38	52.41 ± 4.91
Body mass index (Kg/m^2)	24.11 ± 2.43	25.13 ± 1.93	24.66 ± 2.47
Duration of disease (mean±SD); months	4.3 ± 1.1	4.9 ± 2.1	4.6 ± 2.3
Pain with activity (mean+SD)	72.1 ± 6.5	74.3 ± 4.1	70.6 ± 2.8
Range of motion (degree)			
Flexion	92.4 ± 8.4	95.5 ± 4.5	91.7 ± 4.6
Extension	30.5 ± 5.6	29.1 ± 3.9	31.1 ± 7.8
Abduction	80.3 ± 7.4	82.8 ± 4.8	81.1 ± 7.4
Internal Rotation	21.5 ± 4.5	26.8 ± 2.8	24.8 ± 4.8
External Rotation	25.5 ± 5.5	28.3 ± 3.6	29.3 ± 3.8
Constant score	58.6 ± 6.2	55.8 ± 8.4	58.8 ± 6.4

Comparison of changes from baseline in the VAS and Constant scores between PRP, SAI steroid and IAI steroid groups

	PRP (n=30)	SAI (n=30)	IAI (n=30)	P value
VAS				
4 weeks	36.8 (6.8)	31.5 (7.5)	34.4 (8.1)	0.71
12 weeks	51.1 (7.1)	43.5 (9.2)	41.9 (8.3)	0.10
24 weeks	58.8 (8.2)	46.4 (7.7)	43.9 (6.9)	0.09
Constant Score				
4 weeks	32.7 (8.6)	26.8 (9.4)	25.1 (7.4)	0.61
12 weeks	49.4 (7.1)	39.3 (8.1)	40.8 (6.4)	0.08
24 weeks	58.9 (3.5)	43.8 (7.4)	41.9 (8.1)	0.11

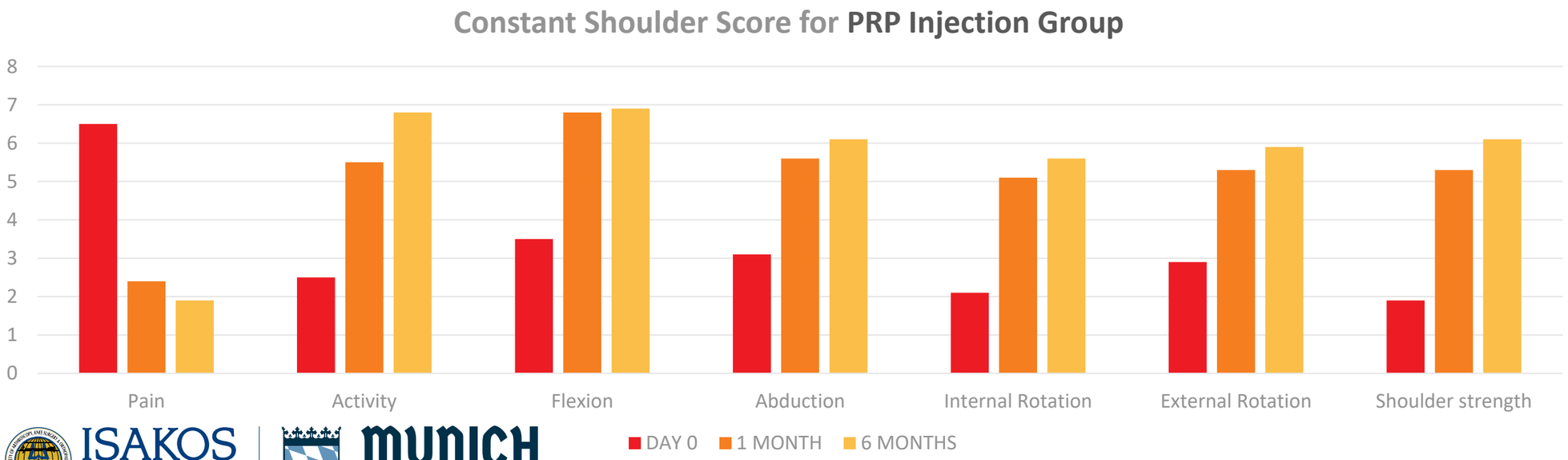

ISAKOS CONGRESS 2025 | MUNICH GERMANY June 8–11

Conclusion
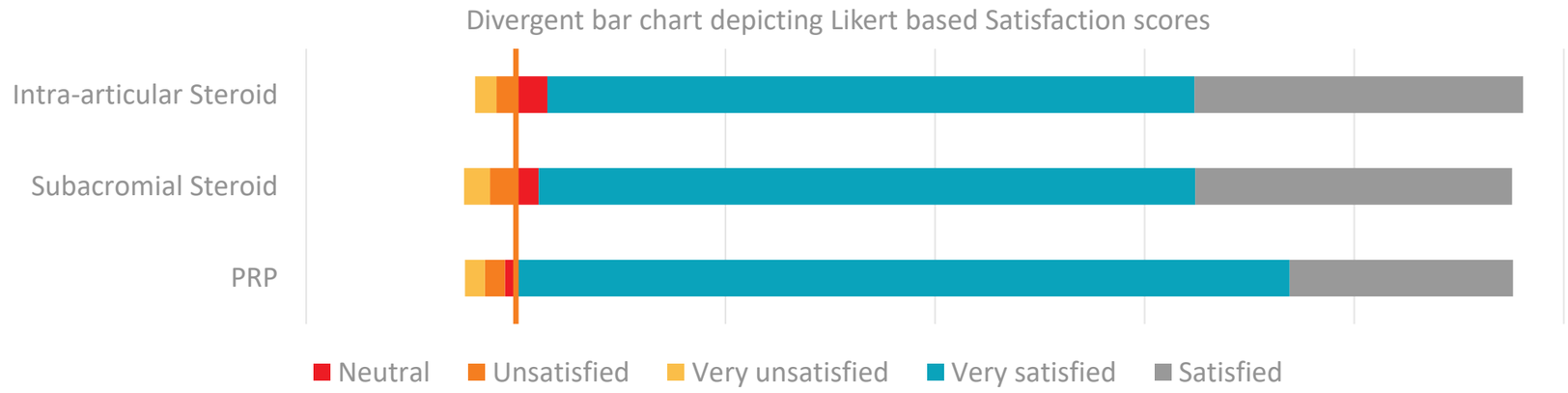
- In this study, PRP group showed significant improvements in pain relief, better functional outcomes in shoulder score at 6 months as compared to both Subacromial steroid and Intra-articular steroid injection groups.