ISAKOS CONGRESS 2025 | MUNICH GERMANY June 8–11

How Should I Measure Proximal Femoral Version In Torsional Deformities? A New, Easy And Reproducible Measurement Method Using Maximum Intensity Projection (MIP) Imaging On Ct Scan.

F. Rosso[1], M. Bechis[2], G. Governale[1], A. Cantivalli[3], F. Liberace[1], R. Rossi[1,4], D.E. Bonasia[1,4]

[1] AO Ordine Mauriziano, Torino, Italy
[2] Ospedale Maria Vittoria, Torino, Italy
[3] Ospedale Maggiore di Chieri, Chieri, Italy
[4] Università degli Studi di Torino, Torino, Italy

UNIVERSITAS STUDII TAURINENSIS 1404

DIPARTIMENTO di SCIENZE CHIRURGICHE

Faculty Disclosure Information

- M. Bechis, G. Governale, A. Cantivalli, F. Liberace

- F Rosso: research grant from Medacta
- R Rossi: Angelini Farmaceutica: Paid presenter or speaker; Arthrex, Inc: Paid presenter or speaker DePuy, A Johnson & Johnson Company: Paid presenter or speaker, Lima corporate: IP royalties Zimmer: Paid consultant; Paid presenter or speaker
- D.E. Bonasia: Arthrex, Inc: Paid presenter or speaker

INTRODUCTION

- **Excessive femoral anteversion** can be associated to patellofemoral (PF) instability

- **FEMORAL ANTEVERSION** → forward rotation of the femoral neck relative to the posterior surface of the femur at the knee joint

- Still **no consensus** about cut off for femoral version and measurement methods

Mathon, KSSTA 2021

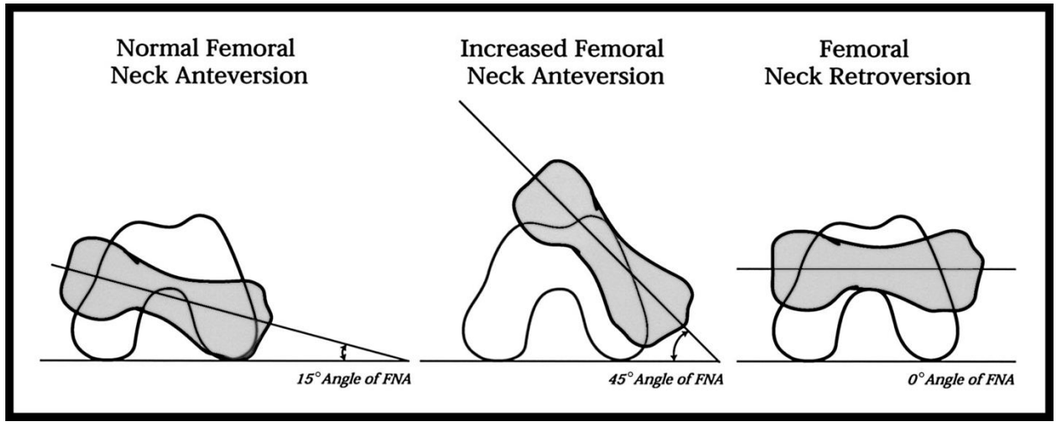

INTRODUCTION – FOCUS ON FEMORAL VERSION

- Different measurement methods:
  - Yoshioka
  - Waidelich
  - Hernandez
  - Murhpy

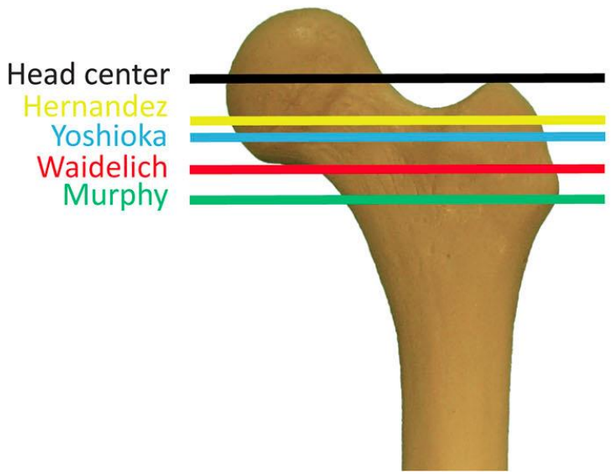

- ***No definitive cut-off*** in Literature

- Most widely cut-off used is ***5-20°,*** but there may be some variability with different methods

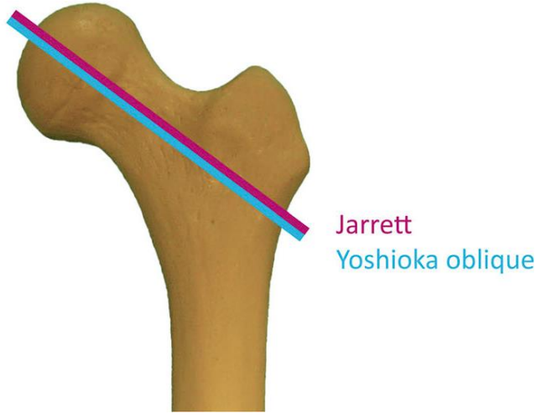

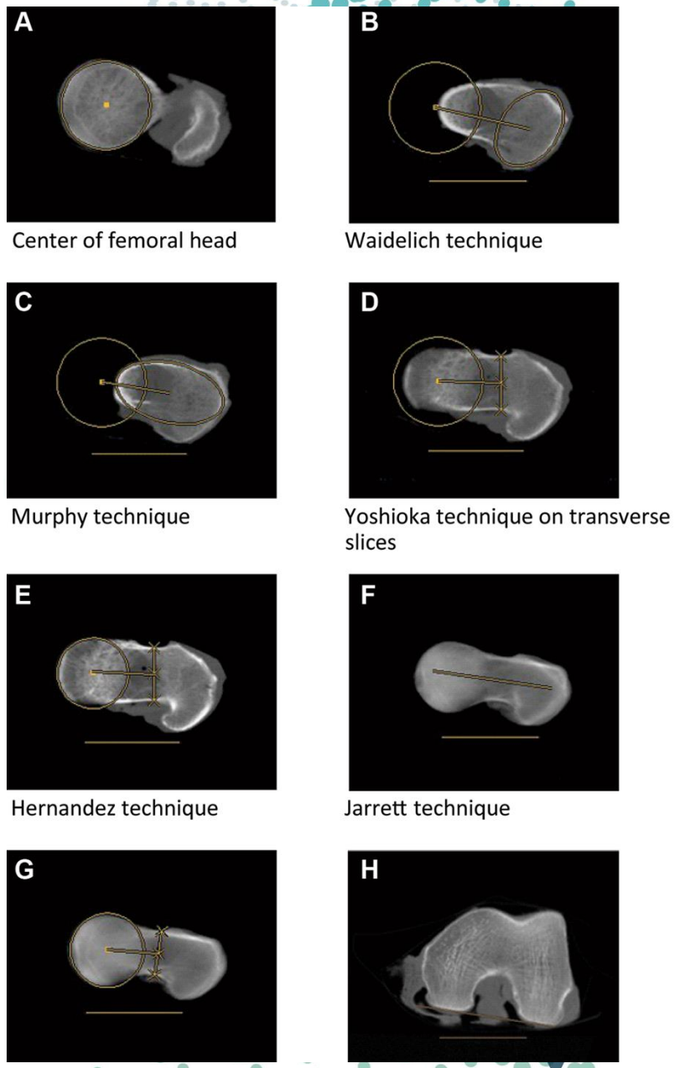

ISAKOS CONGRESS 2025 | MUNICH GERMANY June 8–11

Su, EOR 2024
Kaiser, AOTS 2016

INTRODUCTION – PROBLEM WITH FEMORAL VERSION

- **Problem 1** → Femoral version is calculated on different superimposed slices → risk for poor reproducibility

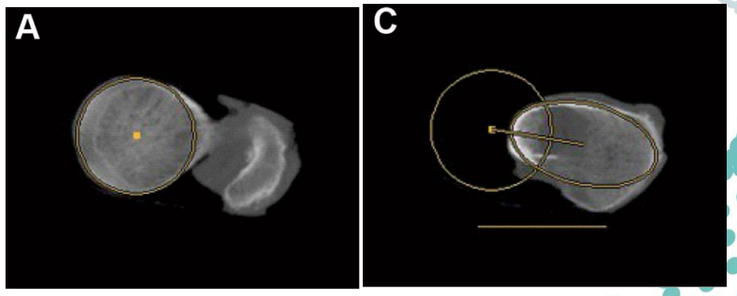

- **Problem 2** → Increasing femoral version values for methods with a distal definition of the angle, with differences up to 17°

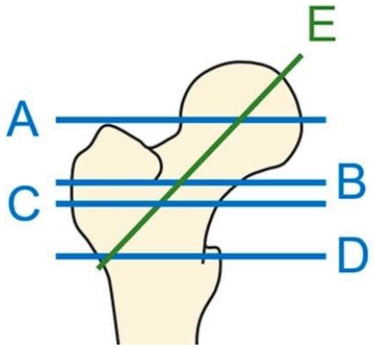

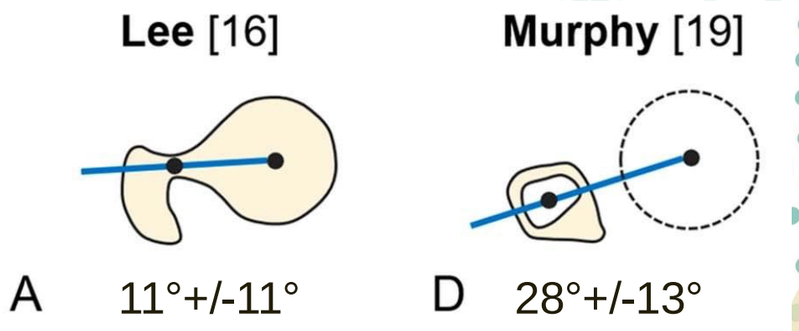

Scorcelletti, JOA 2020
Schmaranzer, CORR 2019

AIM OF THE STUDY

- Evaluate a new measurement method for Femoral version designed to overcome the risk for superimposed slices

- Comparison with existing measurement methods to assess its reliability

ISAKOS CONGRESS 2025 | MUNICH GERMANY June 8–11

METHODS

Population

Screening of 116 consecutive bilateral lower limb CT angiographies

INCLUSION CRITERIA	EXCLUSION CRITERIA
CT scan including hip – knee – ankle (complete bony landmark for torsional deformity evaluation)	Previous surgeries - fractures
	Malformations
	Lower limb joint replacement
	End-stage OA
	Tumors

- 50 patients (50 right femurs, 15 females + 35 males)
- Mean age 72.4±9.7 years
- 2 observers (T0 and T1 30 days)

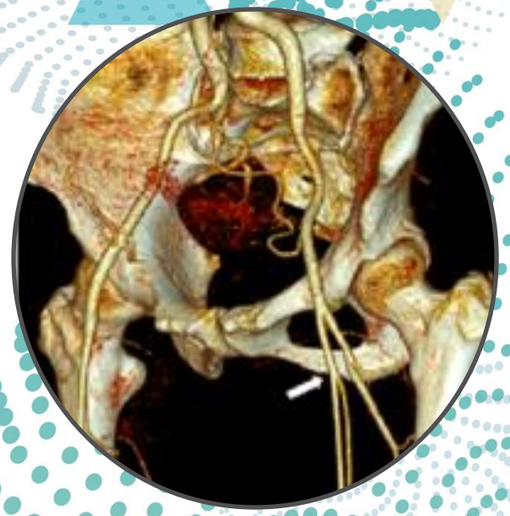

ISAKOS CONGRESS 2025

Measurements

- **<u>Femoral version with Maximum Intensity Projection (MIP)</u>** → projecting the voxel with the highest attenuation value on every view throughout the volume onto a 2D image



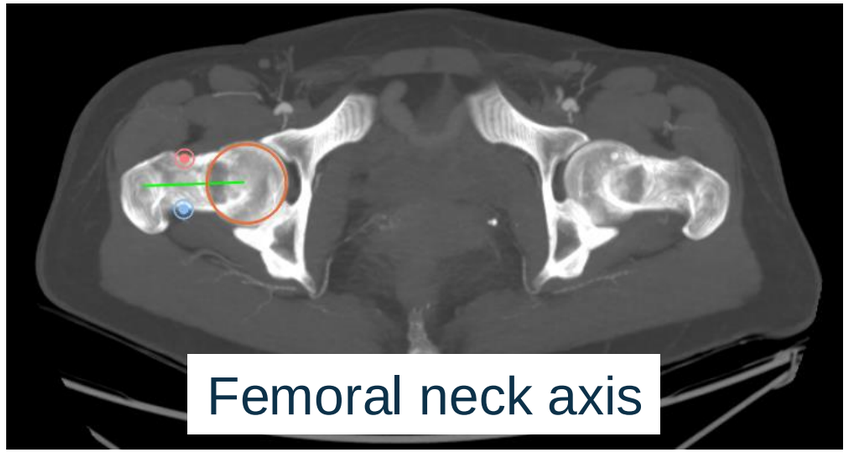

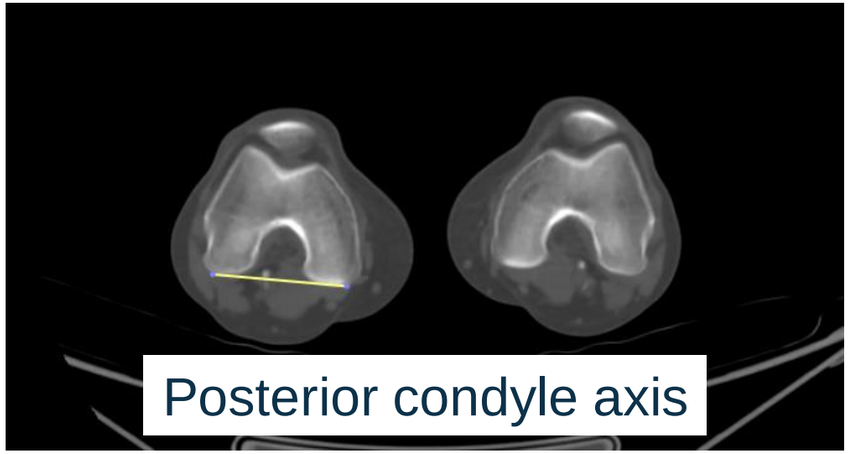

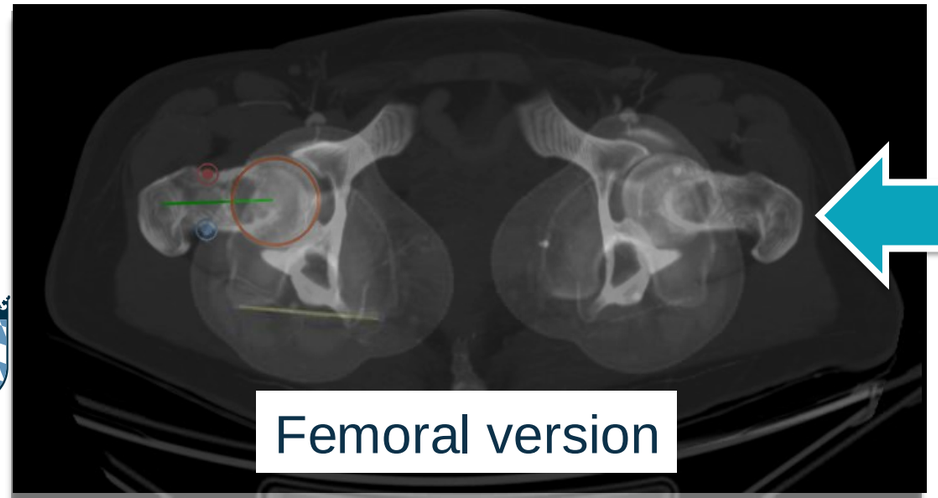

- **MIP of the femoral neck axis**
- **Superimposition of FNA with posterior condylar axis**

- **Femoral version with standard mesurement methods**

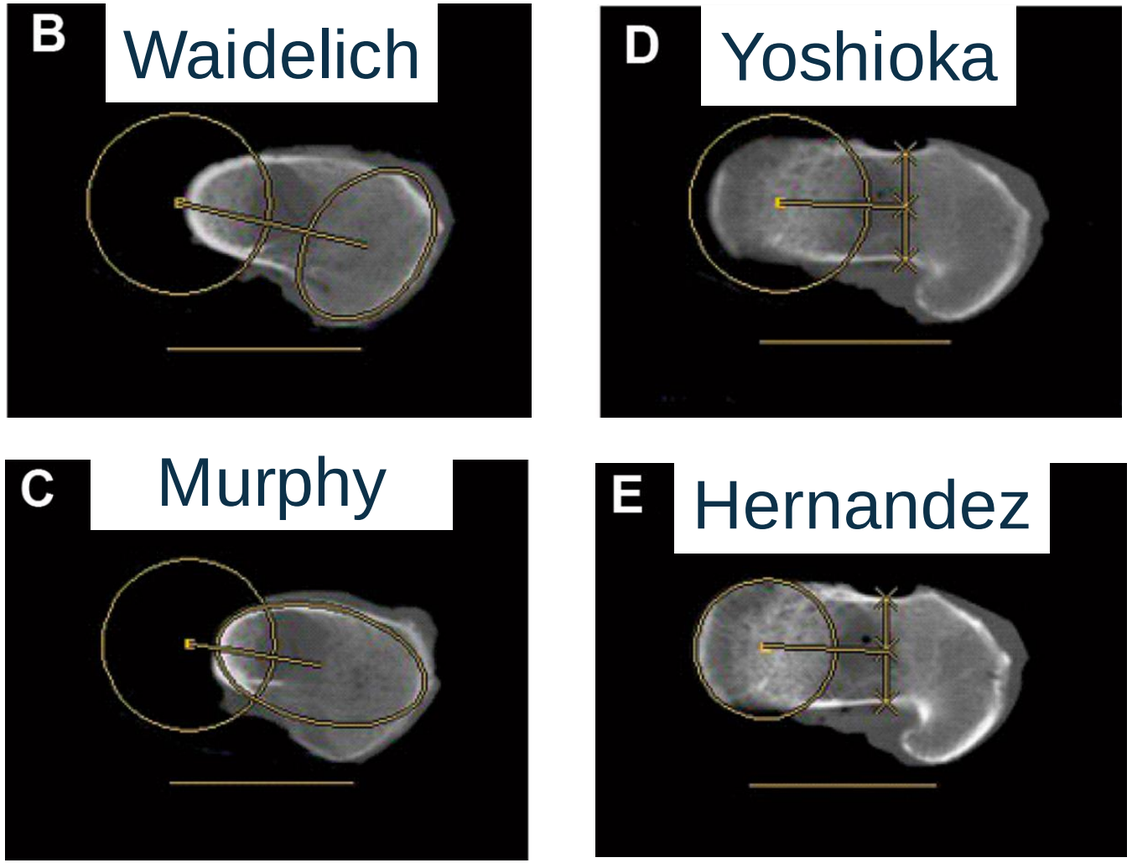

COMPARISON FNA MIP VS FNA STANDARD MEASUREMENT

- **INTRA-OBSERVER RELIABILITY:**
  - Pearson correlation index (R, normal distribution)
  - Spearman's rank correlation coefficient (rho, not normal distribution)

- **INTER-OBSERVER RELIABILITY**
  - Intraclass-correlation-coefficient (ICC)
  - Kappa coefficient

Su, EOR 2024
Kaiser, AOTS 2016

RESULTS

High variability between measurements

METHOD	AVERAGE	STANDARD DEVIATION
Murphy	18.4°	7.2
Waidelich	24.6°	7.4
Yoshioka	11.5°	7.8
Hernandez	10.7°	7.0
MIP	13.7°	6.2

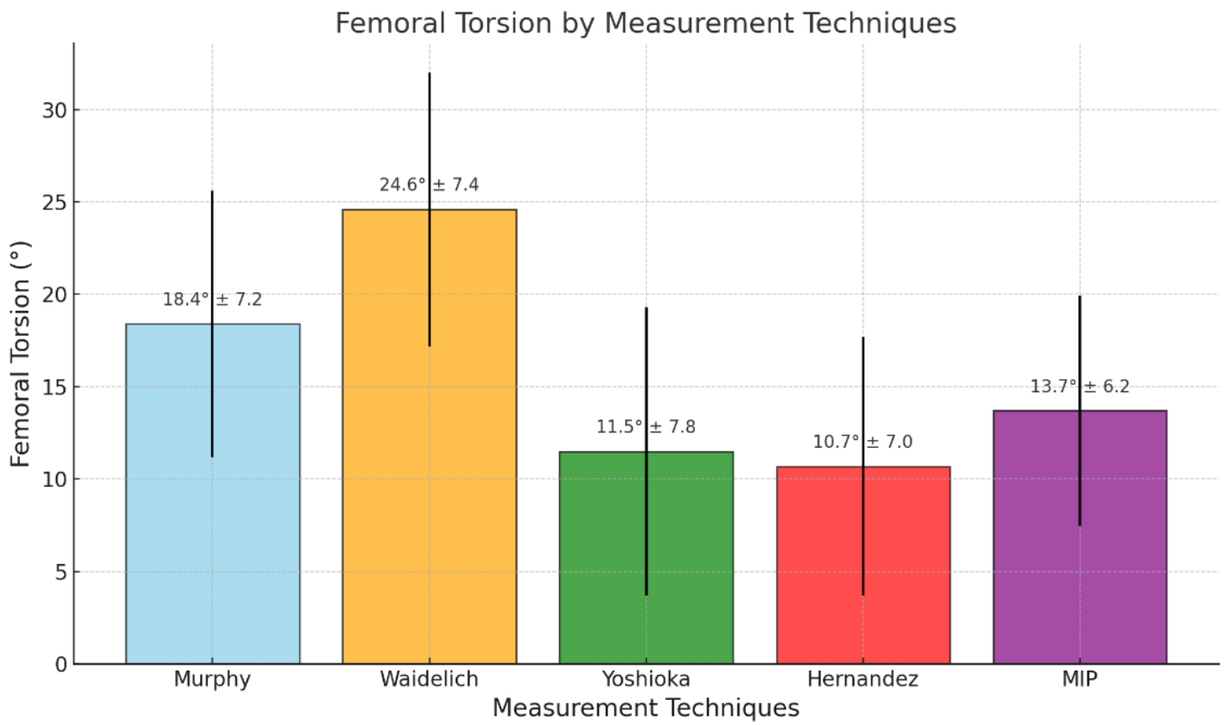

Intra-observer reliability

- All measurement techniques showed high levels of intra-observer reliability
- **MIP** demonstrated **higher intra-observer reliability** compared to the others

MEASURE	INTRA-OBSERVER B (Pearson)		INTRA-OBSERVER P (Pearson)	
	COEFF R	P VALUE	COEFF R	P VALUE
WAIDELICH	0,8816	P<0,0001	0,9202	P<0,0001
MURPHY	0,9189	P<0,0001	0,9054	P<0,0001
YOSHIOKA	0,7604	P<0,0001	0,9903	P<0,0001
HERNANDEZ	0,8215	P<0,0001	0,9757	P<0,0001
MIP	0,9718	P<0,0001	0,9914	P<0,0001

Inter-observer reliability

MIP demonstrated **higher inter-observer reliability** compared to the others

MEASURE	INTER-OBSERVER (ICC)			
	COEFF SAME	IC95% SAME	COEFF AVER	IC95% AVER
WAIDELICH	0,8204	0,7023 - 0,8946	0,9014	0,8251 - 0,9444
MURPHY	0,7474	0,5920 - 0,8492	0,8555	0,7437 - 0,9185
YOSHIOKA	0,604	0,3911 - 0,7555	0,7531	0,5623 - 0,8607
HERNANDEZ	0,7912	0,6574 - 0,8766	0,8834	0,7933 - 0,9342
MIP	0,8426	0,7369 - 0,9080	0,9145	0,8485 - 0,9518

CONCLUSION

- High variability between different methods to measure femoral version
- MIP demonstrated excellent intra-observer and inter-observer reliability
- MIP performs better compared to standard methods

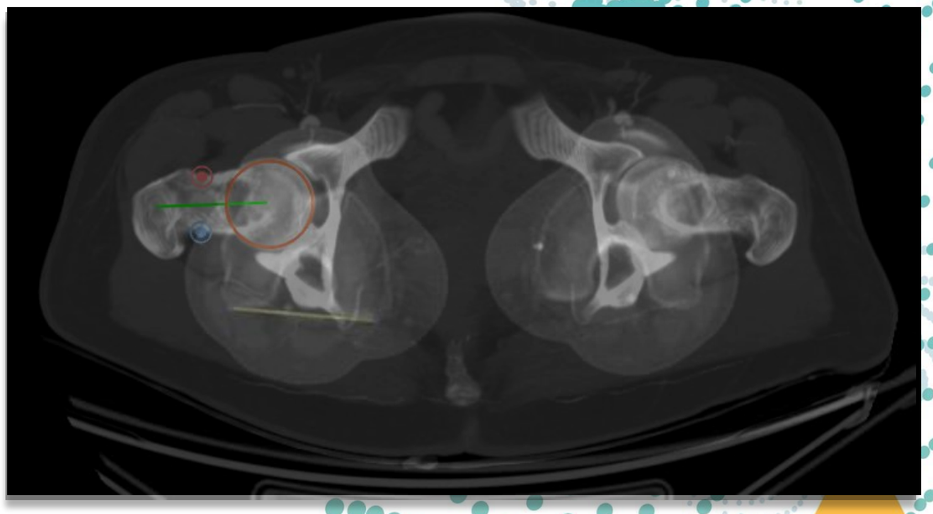

Femoral version measured with MIP is easy and efficent

RECOMMENDED READINGS

1. Barton KI, Boldt KR, Sogbein OA, Steiner NJ, Moatshe G, Arendt E, Getgood A. Femoral internal torsion greater than twenty-five degrees and/or external tibial torsion greater than thirty degrees as measured by computed tomography are threshold values for axial alignment correction in patellofemoral instability. J ISAKOS. 2024 Jun;9(3):386-393. doi: 10.1016/j.jisako.2024.02.002.
2. Botser IB, Ozoude GC, Martin DE, Siddiqi AJ, Kuppuswami S, Domb BG. Femoral anteversion in the hip: comparison of measurement by computed tomography, magnetic resonance imaging, and physical examination. Arthroscopy. 2012 May;28(5):619-27. doi: 10.1016/j.arthro.2011.10.021.
3. Bråten M, Terjesen T, Rossvoll I. Femoral anteversion in normal adults. Ultrasound measurements in 50 men and 50 women. Acta Orthop Scand. 1992 Feb;63(1):29-32. doi: 10.3109/17453679209154844.
4. Kaiser P, Attal R, Kammerer M, Thauerer M, Hamberger L, Mayr R, Schmoelz W. Significant differences in femoral torsion values depending on the CT measurement technique. Arch Orthop Trauma Surg. 2016 Sep;136(9):1259-1264. doi: 10.1007/s00402-016-2536-3.
5. Liodakis E, Doxastaki I, Chu K, Krettek C, Gaulke R, Citak M, Kenawey M. Reliability of the assessment of lower limb torsion using computed tomography: analysis of five different techniques. Skeletal Radiol. 2012 Mar;41(3):305-11. doi: 10.1007/s00256-011-1185-4.
6. Mackay J, Thomason P, Sangeux M, Passmore E, Francis K, Graham HK. The impact of symptomatic femoral neck anteversion and tibial torsion on gait, function and participation in children and adolescents. Gait Posture. 2021 May;86:144-149. doi: 10.1016/j.gaitpost.2021.03.004.
7. Perandini S, Faccioli N, Zaccarella A, Re T, Mucelli RP. The diagnostic contribution of CT volumetric rendering techniques in routine practice. Indian J Radiol Imaging. 2010 May;20(2):92-7. doi: 10.4103/0971-3026.63043.
8. Scorcelletti M, Reeves ND, Rittweger J, Ireland A. Femoral anteversion: significance and measurement. J Anat. 2020 Nov;237(5):811-826. doi: 10.1111/joa.13249.
9. Seitlinger G, Moroder P, Scheurecker G, Hofmann S, Grelsamer RP. The Contribution of Different Femur Segments to Overall Femoral Torsion. Am J Sports Med. 2016 Jul;44(7):1796-800. doi: 10.1177/0363546516639945.
10. Vanhove F, Noppe N, Fragomen AT, Hoekstra H, Vanderschueren G, Metsemakers WJ. Standardization of torsional CT measurements of the lower limbs with threshold values for corrective osteotomy. Arch Orthop Trauma Surg. 2019 Jun;139(6):795-805. doi: 10.1007/s00402-019-03139-1.
11. Waelti S, Fischer T, Griessinger J, Cip J, Dietrich TJ, Ditchfield M, Allmendinger T, Messerli M, Markart S. Ultra-low-dose computed tomography for torsion measurements of the lower extremities in children and adolescents. Insights Imaging. 2022 Jul 15;13(1):118. doi: 10.1186/s13244-022-01257-w.
12. Waidelich HA, Strecker W, Schneider E. Computed tomographic torsion-angle and length measurement of the lower extremity. The methods, normal values and radiation load. Rofo. 1992 Sep;157(3):245-51. German. doi: 10.1055/s-2008-1033007.
13. Waldt S (2013) Lower limb alignments. In: Waldt S, Woertler K (eds) Measurements and classifications in musculoskeletal radiol- ogy. George Thieme Verlag KG, New York, pp 5–10.
14. Yoshioka Y, Cooke TD. Femoral anteversion: assessment based on function axes. J Orthop Res. 1987;5(1):86-91. doi: 10.1002/jor.1100050111.