ISAKOS CONGRESS 2025 | MUNICH GERMANY June 8–11

Meniscal-Wall Ultrasound-Guided Steroid Infiltration For Degenerative Meniscal Lesions Shows Low Rate Of Conversion To Surgery

DUPRAT F, MOUARBES D, BERARD E, SAOUDI S, LIONS JB,THOMAS P, FARUCH BILFELD M, CAVAIGNAC E

Toulouse, FRANCE

Faculty Disclosure Information

- Nothing to disclosure

Introduction

Hypothesis: **« Ultrasound-guided corticosteroid injection of the meniscal wall in stable and symptomatic DML helps avoid surgical treatment and improve clinical scores»**

Primary objective: Survival without surgery at least 2 years of follow-up

Secondary objectives:
SKV, Tegner, VAS
Predictive factors for good responders (SKV>90)
Pain and functional scores

Materials and methods

Retrospective, single-center study, **187 patients**

Inclusion criteria :

- **Grade 2 and 3 lesion**
- **Medial meniscus pain**

Exclusion criteria :

- Unstable lesion (clinical or MRI)
- Ligament damage
- Mechanical axis deviation >5°
- Radiological osteoarthritis (Kellgren-Lawrence >2)
- Cartilaginous damage (ICRS II)
- Surgery, infiltration or knee trauma in the previous year

US meniscal guided infiltration [1]

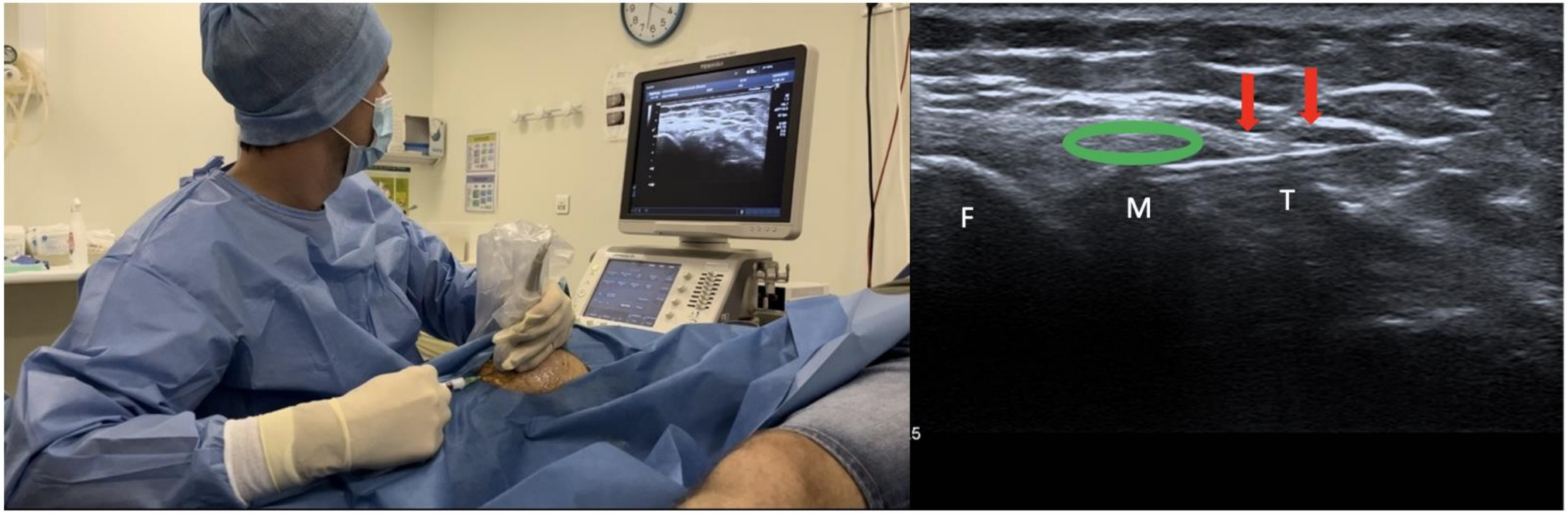

Results

- 187 patients
- **Mean age : 51 years**
- > 35 ans : 87%
- Left = right
- Sick leave : 20 %
- Sports ceasing: 56%

	Total 187 (100.0)
Side (R/L) n(%)	
RIGHT	94 (50.3)
LEFT	93 (49.7)
Age (years)	
Mean (SD)	50.96 (14.19)
Age (years) n(%)	
<35ans	25 (13.4)
>=35ans	162 (86.6)
Sick leave n(%)	
no	149 (79.7)
yes	38 (20.3)
Sport ceasing n(%)	
no	82 (43.9)
yes	105 (56.1)

Results

Primary endpoint

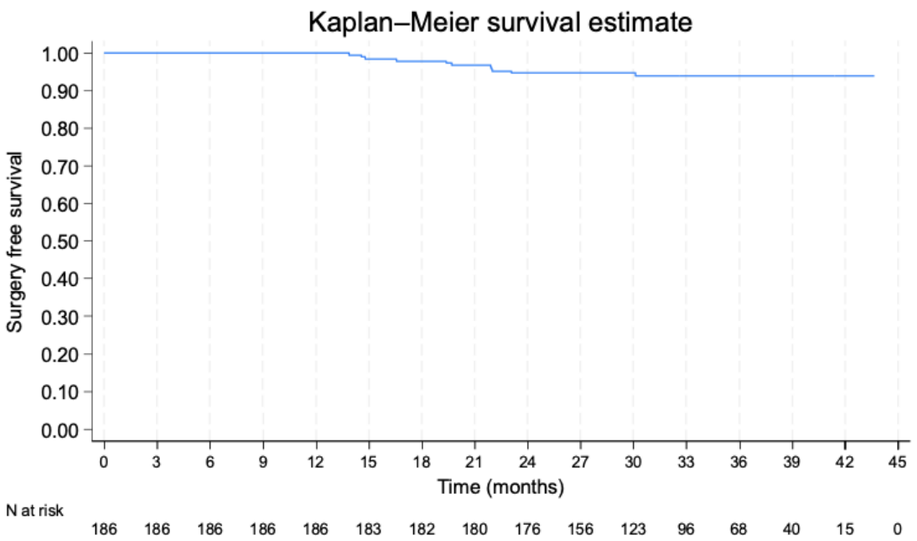

Stability at 42 months : 94 %

95% survival without surgery at 2 years !! [2]

ISAKOS CONGRESS 2025 | MUNICH GERMANY June 8–11

Results

Secondary endpoint

7 menisectomy

5 high tibial osteotomies

Surgery rate : 6,4% (12 patients)

ISAKOS CONGRESS 2025 | MUNICH GERMANY June 8–11

Results

Secondary endpoint

- **SKV mean : 71**
- **TEGNER mean : 6,75**
- **VAS at rest : 1,47**
- **VAS walking : 2,47**
- **Seack leave: 2,1 %**
- **Sports ceasing : 6,4 %**

	Total 187 (100.0)
VAS pain (rest)	
n /missing	187/0
Mean (SD)	1.47 (2.51)
VAS pain (walking)	
n /missing	187/0
Mean (SD)	2.47 (2.91)

ISAKOS CONGRESS 2025 | MUNICH GERMANY June 8–11

Results

Predictive factor for good response (SKV > 90)

	SKV		
	≤90 N=154 (82.4%)	>90 N=33 (17.6%)	p value
BMI			
n /missing	154/0	33/0	
Mean (SD)	26.23 (4.93)	24.04 (3.82)	.017
Median	26.00	23.00	

BMI significantly lower in better responders

ISAKOS CONGRESS 2025 | MUNICH GERMANY June 8–11

Discussion

Strenght :

- **Sample size**
- **Precise indication**
- **Simple and standardized procedure**
- **Stability at 42 months**

Limitations :

- **Restropective study**
- **Non comparative study**
- **Memory bias**

Take home message

- Survival without surgery at 2 years : 95 %
- Good functionnals and pain scores
- Better responder profil if BMI is lower

US guided meniscal infiltration for DML :

1) **Simple**
2) **Effective +++**

References

1-Duprat F, Mouarbes D, Berard E, Thomas P, Laffort J, Cavaignac E, Faruch Bilfeld M. **Ultrasound guided injection of corticosteroids technique for the treatment of degenerative meniscal tear**. Arthroscopy journal. 2024

2-Duprat F, Mouarbes D, Berard E, Saoudi S, Lions JB, Thomas P, Faruch Bilfeld M, Cavaignac E. **Meniscal-wall ultrasound-guided steroid infiltration for degenerative meniscal lesions (DML) shows low rate of conversion to surgery**. OTSR Journal. 2024

3-Beaufils P, Becker R, Kopf S, et al. **Surgical management of degenerative meniscal lesions : the 2016 ESSKA meniscal consensus.** Knee Surg Sports Traumatol Arthrosc. 2017

4-Hohmann E. **Treatment of Degenerative Meniscus Tears**. *Arthroscopy*. 2023

5-Habib GS, Saliba W, Nashashibi M. **Local effects of intra-articular corticosteroids**. *Clin Rheumatol* 2010

6-Arnoczky SP, Warren RF. **Microvasculature of the human meniscus**. *Am J Sports Med*. 1982

7-Bouvard M, Juret A. **Interest of infiltrations of the « meniscal wall » by corticosteroids in meniscal pain of the knee. About 214 cases.** Journal of Sports Traumatology. 2008

8-Coll C, Coudreuse JM, Guenoun D, et al. **Ultrasound-Guided Perimeniscal Injections: Anatomical Description and Feasibility Study**. *J Ultrasound Med*. 2022