ISAKOS CONGRESS 2025 | MUNICH GERMANY June 8–11

SPARING THE POSTEROLATERAL BUNDLE IN ACL PARTIAL INJURIES

EVALUATION AND COMPARISON OF 2 DIFFERENT MODALITIES FOR THE SURGICAL MANAGEMENT OF PARTIAL ACL INJURIES IN A POPULATION OF PATIENTS INVOLVED IN PROFESSIONAL SPORT

Baldassarri Matteo MD[1]
Luca Perazzo MD[2]
Diego Ghinelli MD[3]
Sarino Ricciardello MD[2]
Alessandro Parma MD[2]
Roberto Buda Prof.[4]

1. Villa Regina Hospital – Bologna ITALY
2. Villa Laura Hospital – Bologna ITALY
3. Villa Maria Hospital – Rimini ITALY
4. Private Hospital "Eugenio Gruppioni"– Bologna ITALY

Faculty Disclosure Information

- None of the authors received payments or services, either directly or indirectly (i.e., via his or her institution), from a third party in support of any aspect of this work.
- None of the authors, or their institution(s), have had any financial relationship, in the six-twelve months prior to submission of this work, with any entity in the biomedical area that could be perceived to influence or have the potential to influence what is written in this work.
- All the authors authors have never had relationships, or has engaged in any other activities, that could be perceived to influence or have the potential to influence what is written in this work.

INTRODUCTION AND PURPOSE

Several methods outlined in literature for chronic partial Anterior Cruciate Ligaments Tears do not preserve the undamaged section of the ligament. The purpose of this research was to conduct a retrospective analysis of the outcomes achieved using the identical ACL reconstructive surgery method in 43 sports patients, whether the AM bundle was preserved or not.

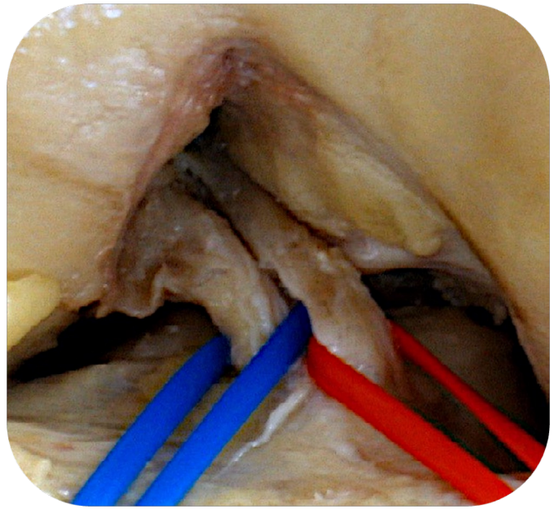

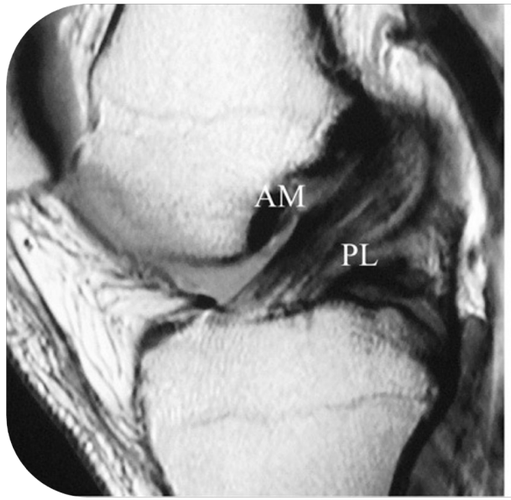

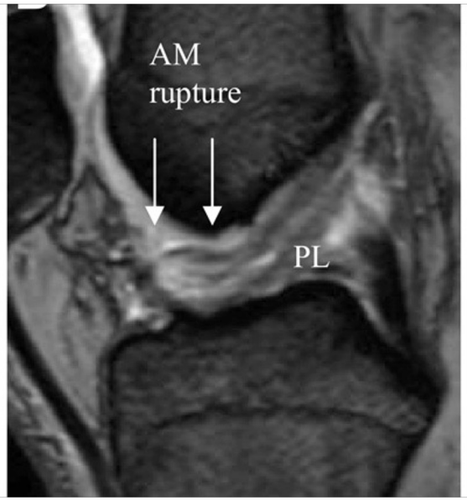

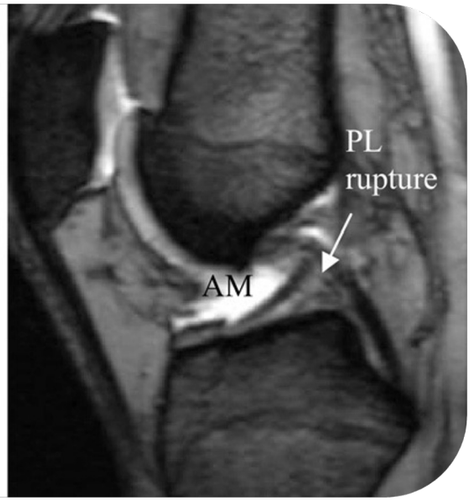

MATERIAL & METHODS

Between 2018 and 2021, 43 patients with ACL partial tear injury and rupture of the posterolateral (PL) bundle were randomly split into 2 groups with similar sex, age, and sports activity levels. Group A, consisting of 22 patients, underwent ACL reconstruction utilizing the ST-GR over the top technique, which involved sacrificing the anteromedial (AM) remaining bundle. Meanwhile, in Group B, 21 patients underwent ACL reconstruction technique with the use of only ST bundle technique and preserving the AM bundle.

Each patient underwent MRI assessment at 12 months and clinical evaluation using the IKDC and Tegner scores at 6-, 12-, 24-, 36-, 48-months. Testing with the KT-1000 device was conducted at 12 months follow-up. Statistical analysis was conducted on the results to compare subjective outcome and stability between the 2 groups, with significance set at $P < 0.05$ for all tests.

SURGICAL TECHNIQUE

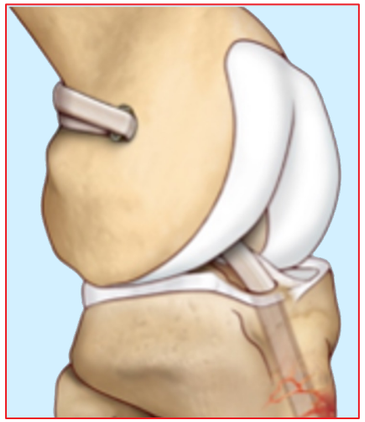

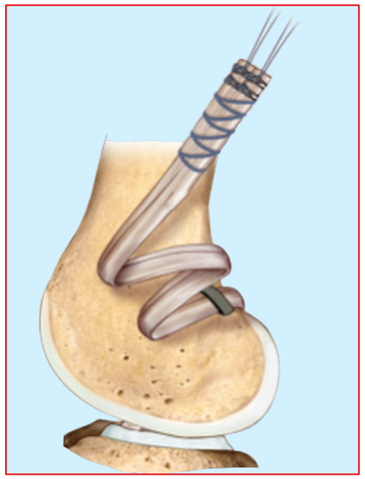

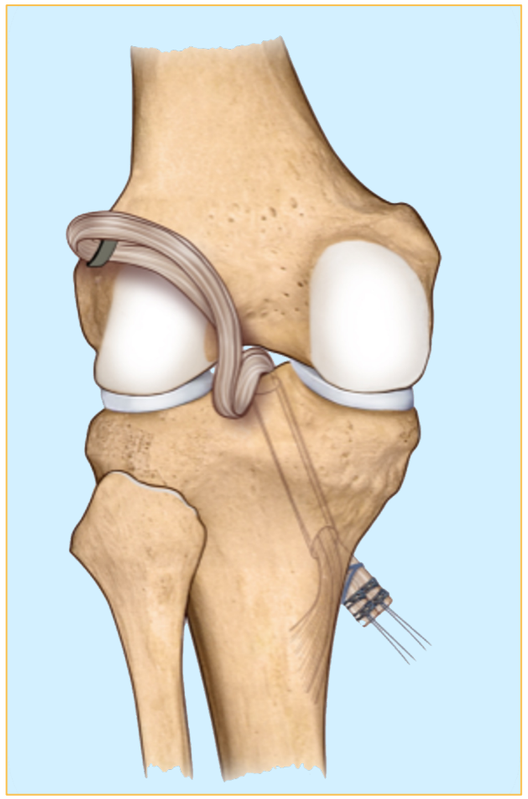

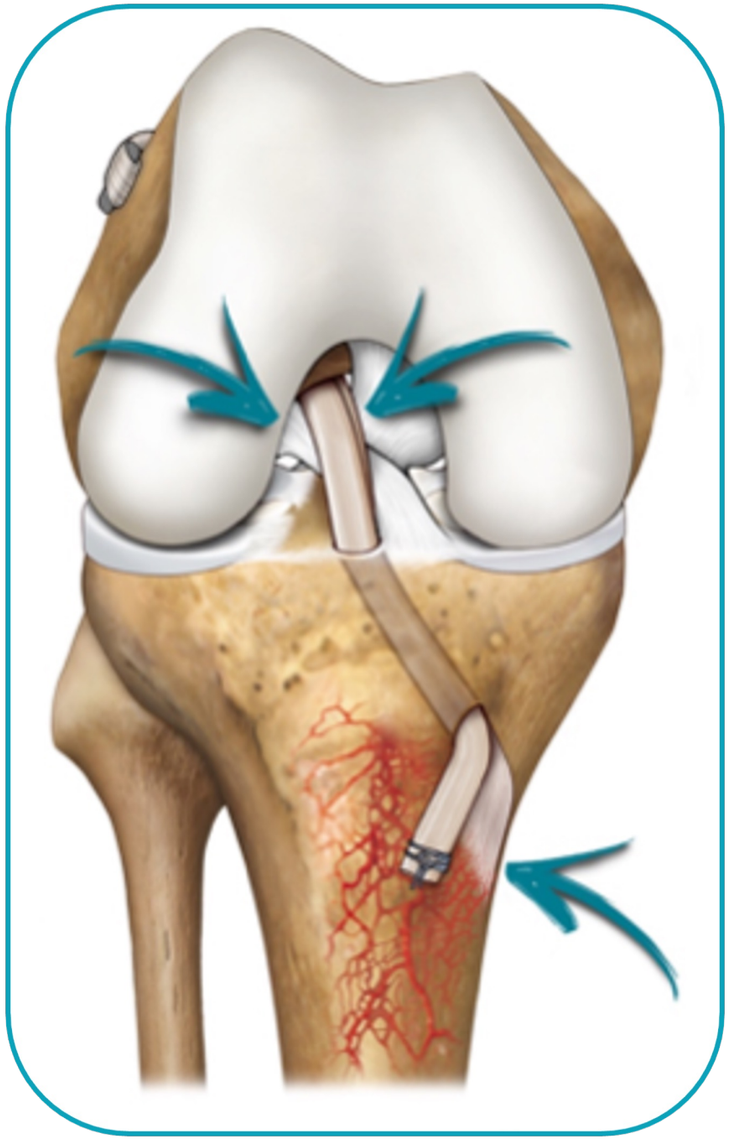

SURGICAL TECHNIQUE

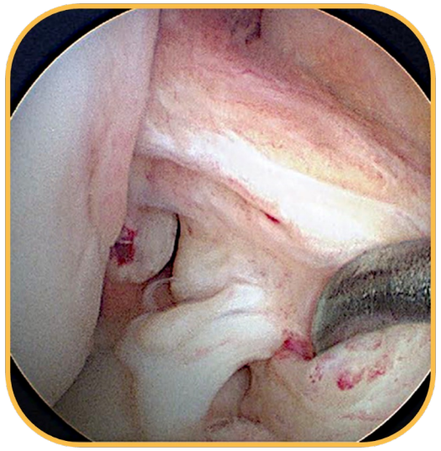

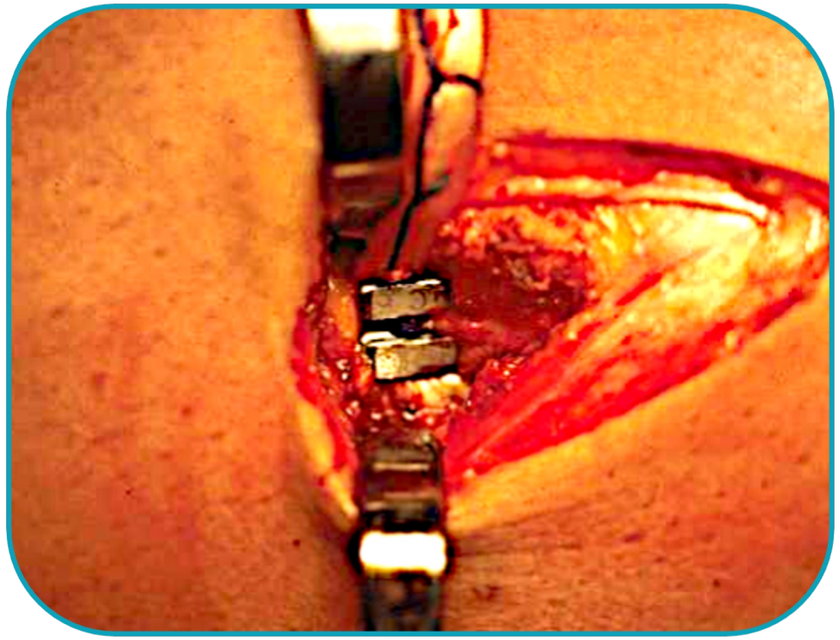

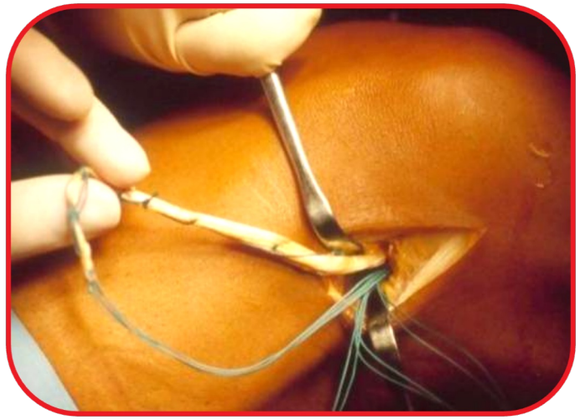

RESULTS

No failures were noted.
At final follow-up IKDC subjective score was 90.6±3.7 in group A and 91.2±3.4 in group B.
At 48-month follow-up, group A had a Tegner score of 7.4±2.3, while group B had a score of 7.8±1.7.
KT-1000 results show that group A had a 1.3±0.9 mm side-to-side difference compared to group B's 0.9±0.6 mm.
Group A took 7.1 months to return to the sport, while Group B took 6.2 months.

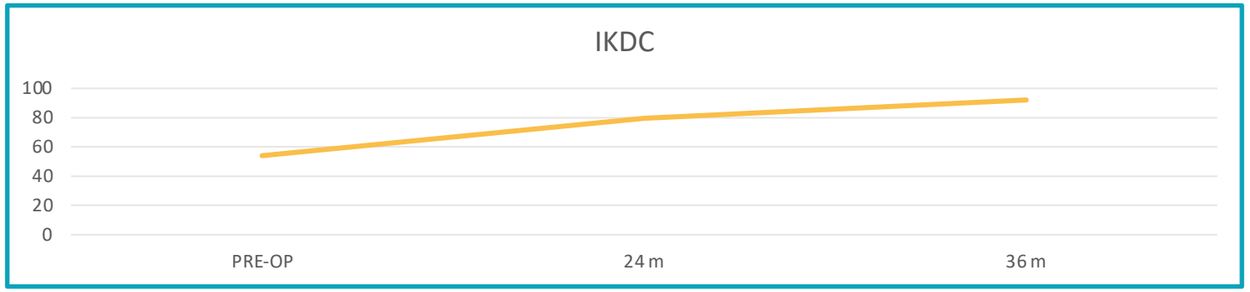

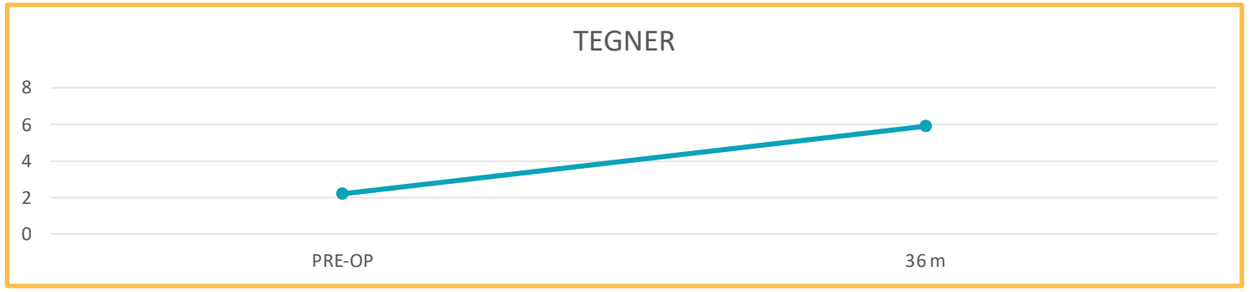

ISAKOS CONGRESS 2025 | MUNICH GERMANY June 8–11

CONCLUSIONS

Both methods described in this study have proven to ensure a successful result. Despite the lack of statistically significant variations in subjective and objective outcomes among the techniques, notable advantages were observed with the sparing bundle technique in group B, including improved clinical scores at final follow-up period and a quicker resumption of sporting activities.

CLINICAL CASE

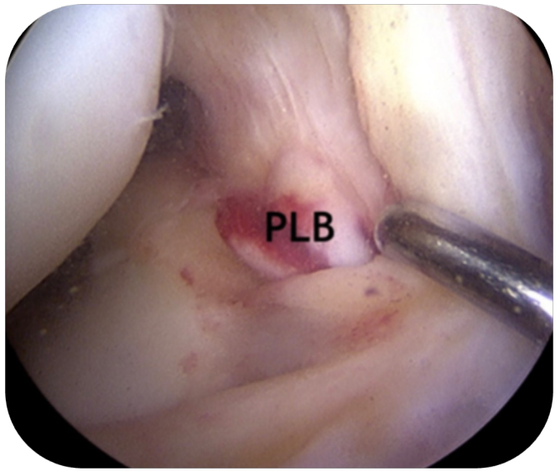

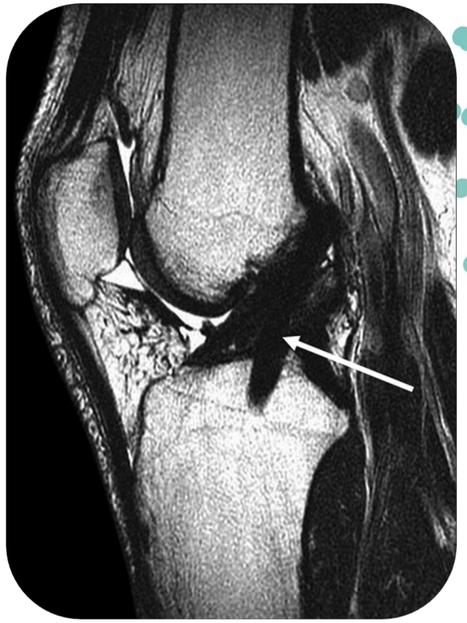

REFERENCES

1. Wang H, Liu Z, Li Y, Peng Y, Xu W, Hu N, Huang W. Is Remnant Preservation in Anterior Cruciate Ligament Reconstruction Superior to the Standard Technique? A Systematic Review and Meta-Analysis. Biomed Res Int. 2019 Dec 11;2019:1652901. doi: 10.1155/2019/1652901. PMID: 31886174; PMCID: PMC6927015.
2. Yoo YS, Song SY, Yang CJ, Ha JM, Kim YS, Seo YJ. A Comparison between Clinical Results of Selective Bundle and Double Bundle Anterior Cruciate Ligament Reconstruction. Yonsei Med J. 2016 Sep;57(5):1199-208. doi: 10.3349/ymj.2016.57.5.1199. PMID: 27401652; PMCID: PMC4960387.
3. Kopka M, Heard SM, Buchko GM, Hiemstra LA, Lafave MR, Kerslake S. Remnant-Sparing Anterior Cruciate Ligament Reconstruction Results in Similar Clinical, Functional, and Quality-of-Life Outcomes to Anatomic Single-Bundle Anterior Cruciate Ligament Reconstruction. Arthrosc Sports Med Rehabil. 2024 Jan 24;6(2):100898. doi: 10.1016/j.asmr.2024.100898. PMID: 38405580; PMCID: PMC10883819.
4. Buda R, Baldassarri M, Perazzo L, Ghinelli D, Faldini C. The biological respect of the posterolateral bundle in ACL partial injuries. Retrospective analysis of 2 different surgical management of ACL partial tear in a population of high-demanding sport patients. Eur J Orthop Surg Traumatol. 2019 Apr;29(3):651-658. doi: 10.1007/s00590-018-2312-x. Epub 2018 Oct 12. PMID: 30315365.
5. Lee BI, Kim BM, Kho DH, Kwon SW, Kim HJ, Hwang HR. Does the tibial remnant of the anterior cruciate ligament promote ligamentization? Knee. 2016 Dec;23(6):1133-1142. doi: 10.1016/j.knee.2016.09.008. Epub 2016 Oct 30. PMID: 27806877.