ISAKOS CONGRESS 2025 | MUNICH GERMANY June 8–11

Hospital Británico

ITRA CONSULTORIO MÉDICO

CASA HOSPITAL San Juan de Dios RAMOS MEJÍA / CASTELAR | ARGENTINA

Use of Pericapsular Nerve Group (PENG) Block for Postoperative Pain Control in Hip Arthroscopy

A Safe Option for Postoperative Pain Management: Our Experience in Patients with Femoroacetabular Impingement Syndrome

-Tomás Vilaseca, Buenos Aires, Argentina.

-Santiago Cao, Buenos Aires, Argentina.

- The authors declare that they have no conflicts of interest related to this presentation.
  No financial relationships or affiliations with commercial interests influenced the content of this study.

Introduction

Hip arthroscopy is increasingly used for femoroacetabular impingement syndrome (FAIS). Postoperative pain remains a key challenge, often leading to patient dissatisfaction.

The PENG block targets the articular branches of the femoral, obturator, and accessory obturator nerves, providing sensory blockade without motor deficit.

Objective:
To evaluate whether the PENG block reduces postoperative pain and opioid consumption in the first 24 hours after hip arthroscopy.

Materials and Methods

Study Design:

Prospective, randomized study (Jan 2022 – Jun 2024)

Participants:

- 70 patients with FAIS undergoing hip arthroscopy
- 35 received PENG block
- 35 did not
- Same surgical and anesthesia team

Inclusion Criteria:

- Diagnosis of mixed FAIS
- Failed conservative treatment
- Age >18, informed consent

Exclusion Criteria:

- Revision arthroscopy
- Periacetabular osteotomy
- Chronic opioid use or substance abuse

Outcomes:

- Pain score (VAS) at 8h postop
- Morphine equivalent consumption (first 24h)
- Duration of PENG block

PENG Block Technique

- Performed preoperatively under ultrasound guidance by the same anesthesiologist
- Patient in supine position
- Convex probe (2–5 MHz) placed transversely over ASIS, rotated 45° toward pubic ramus
- Needle inserted from lateral to medial into fascial plane between psoas tendon and pubic ramus
- 15 mL of 0.75% ropivacaine injected (2 mL test, 13 mL spread)
- Additional 5 mL used for lateral femoral cutaneous nerve block
- *All patients also received spinal anesthesia (12.5 mg isobaric bupivacaine) and standard portal infiltration.*

PENG Block: Anatomical and Ultrasound Images

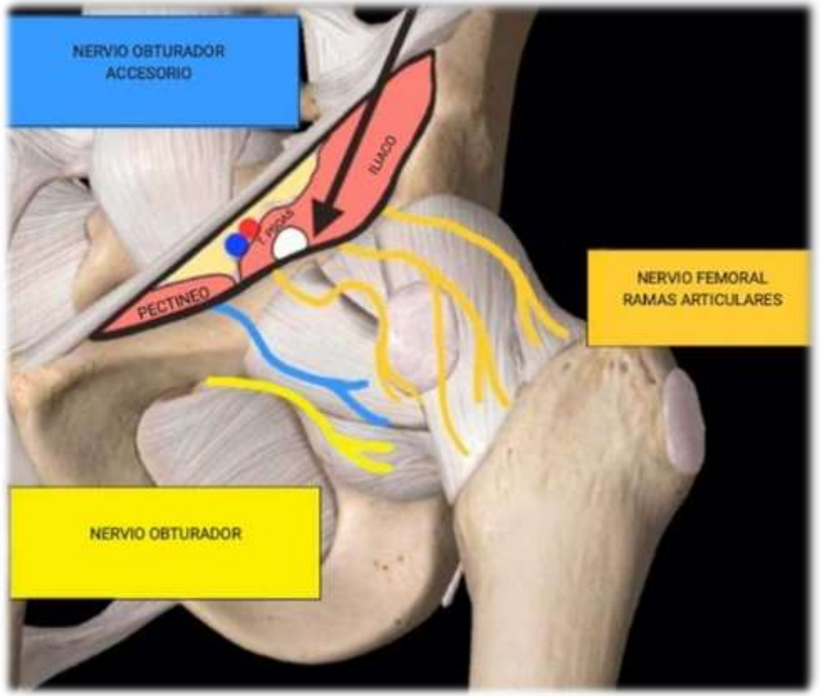

Image 1:
Schematic representation of the innervation of the anterior hip capsule and the target nerves of the PENG block.

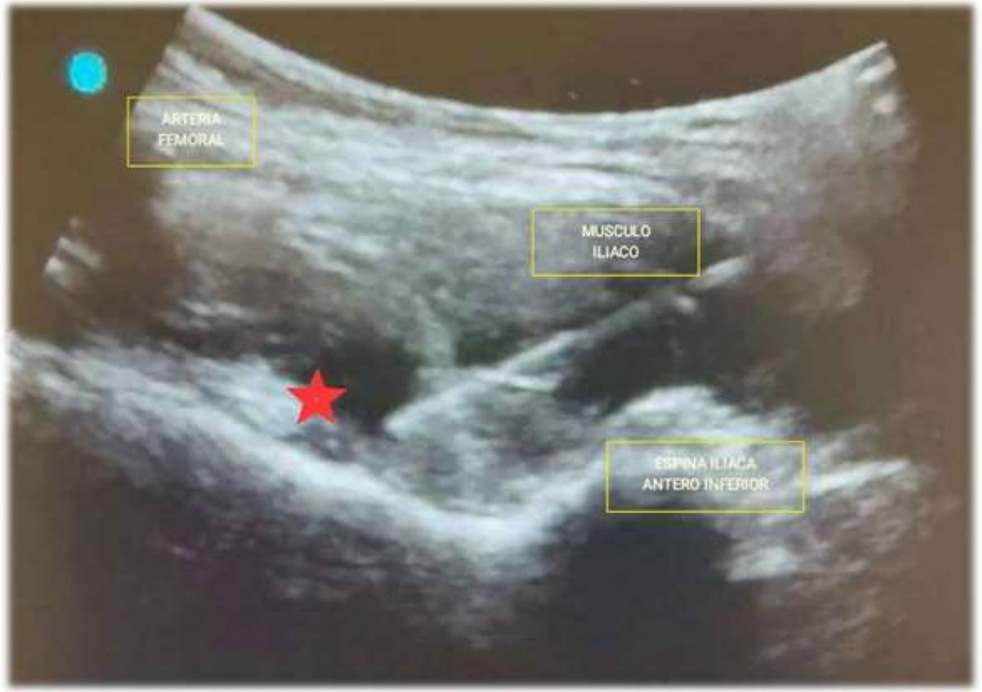

Image 2:
Ultrasound image showing: Psoas tendon (star), Iliopubic eminence, Femoral artery, Needle path between psoas tendon and pubic ramus

Ultrasound-guided injection in the correct fascial plane ensures effective block without motor impairment.

Results

VAS Score at 8 Hours Postoperative

•**PENG Group:** 3.11 ± 0.99

•**No PENG Group:** 4.86 ± 1.21

•*p < 0.05*

Block Duration (PENG Group):

•17.3 ± 4.56 hours

Statistical Test:

•Student's t-test for independent samples

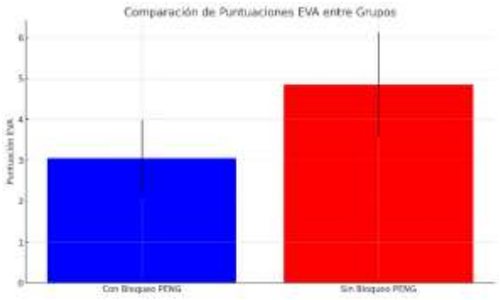

- VAS scores

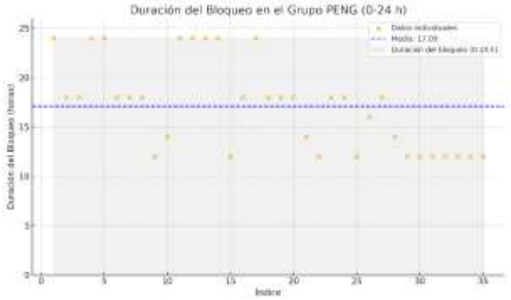

PENG block significantly reduced pain scores in the first 8 hours after surgery.

ISAKOS CONGRESS 2025 | MUNICH GERMANY June 8–11

Morphine Equivalent Consumption (first 24h):

- **PENG Group:** 5.57 ± 4.16 mg
- **No PENG Group:** 12.43 ± 4.09 mg
- *p < 0.05*

All patients were discharged within 24 hours
No complications observed

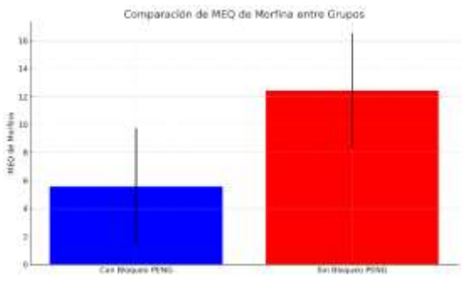

Morphine equivalents
(*with error bars: ± standard deviation*)

PENG block significantly reduced opioid use postoperatively

Discussion

- **PENG block significantly reduced both pain (VAS) and opioid use in the immediate postoperative period**

- Consistent with previous studies:
  - **Kollmorgen et al.:** Lower initial VAS and opioid use with PENG
  - **Yusupov et al.:** Less pain and opioid use, faster discharge
  - **Eppel et al.:** Modest pain reduction, no opioid difference

- **Potential benefits**:
  - Improved patient comfort
  - Reduced opioid-related side effects
  - No observed motor déficits

- ***PENG appears to be an effective component of multimodal analgesia in hip arthroscopy.***

Limitations

- **Small sample size** limits generalizability
- **Single-center study** with one surgical and anesthesia team
- **Pain assessed** only once at **8h postoperative**
- **Short follow-up**: Only first 24h analyzed
- **No placebo** or **alternative block group** for comparison

Further multicenter studies with larger cohorts and longer follow-up are needed.

Conclusions

- The PENG block is effective in reducing postoperative pain and opioid consumption after hip arthroscopy
- It provides **selective sensory blockade** without motor impairment
- Enhances **early recovery** and **patient comfort**
- Promising as part of **multimodal analgesia protocols**
- *Further research is needed to confirm long-term benefits and establish standardized protocols.*

References

1. Girón-Arango L et al. *Pericapsular Nerve Group (PENG) Block for Hip Fracture*. Reg Anesth Pain Med. 2018.
2. Kollmorgen R et al. *PENG Block Reduces Pain and Narcotic Use in FAIS Surgery*. Arthrosc Sports Med Rehabil. 2022.
3. Yusupov A et al. *Improved Outcomes After Hip Arthroscopy With PENG Block*. Arthroscopy. 2023.
4. Eppel B et al. *PENG Block in Hip Arthroscopy: A Randomized Controlled Trial*. Arthroscopy. 2024.
5. Gardner E. *The Innervation of the Hip Joint*. Anat Rec. 1948.
6. Griffin DR et al. *The Warwick Agreement on FAIS*. Br J Sports Med. 2016.
7. Paul RW et al. *Multimodal Pain Management in Arthroscopy*. Arthrosc Sports Med Rehabil. 2021.
8. Nielsen S et al. *Oral Morphine Equivalents for Opioid Use Studies*. Pharmacoepidemiol Drug Saf. 2016.