Functional outcomes and radiological cuff tear healing in arthroscopic single row rotator cuff repair in patients of age more than 65 years: A retrospective case study of 35cases

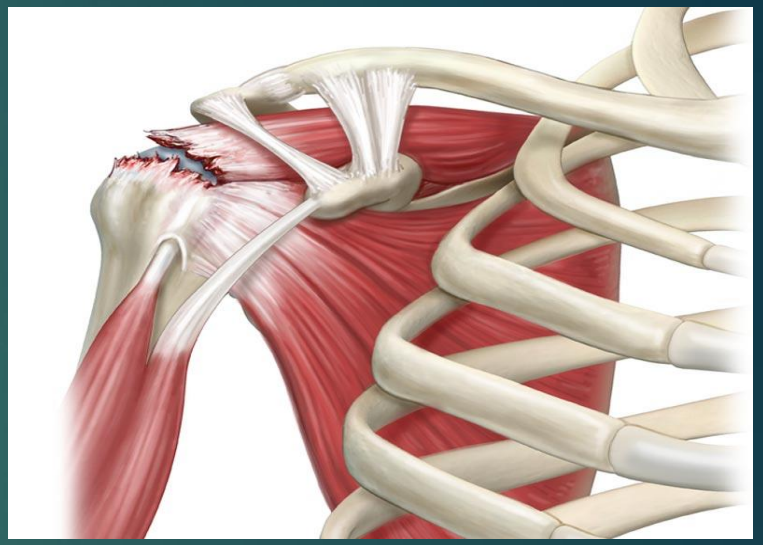

AUTHORS

1- Dr Jaimeen Jesalpura M.S.(Ortho)

Vaishvi Hospital, Vadodara, Gujarat , Email-vaishviortho@gmail.com

2- Dr Vikas Patel M.S.(Ortho)

Vaishvi Hospital, Vadodara, Gujarat , Email-drvikaspatel7589@gmail.com

3- Dr Shailin Shah M.S.(Ortho), DNB(Ortho)

Vaishvi Hospital, Vadodara, Gujarat , Email-shailinshah24@gmail.com

FACULTY DISCLOSURES

NO FINANCIAL SUPPORT OR SPONSORSHIP FROM ANY INSTITUTION OR ORGANISATION.

NO CONFLICT OF INTEREST.

NO AFFILIATIONS TO ANY COMPANY OR ORGANISATION.

INTRODUCTION

The incidence of rotator cuff tears (RCT) increases with age and tends to occur as part of the degenerative process of aging

Patients usually present late to clinic with severely retracted tear, fatty atrophy and arthritic changes associated with disuse osteopenia.

Older individuals have a strong desire to maintain a physically active lifestyle and expect an early return to sport and occupational activities

Over the last decade, some surgeons have promoted a progression from single-row (SR) to double-row (DR) and transosseous equivalent (TOE) techniques.

The goal is to restore the anatomic rotator cuff footprint and maximize the tendon-bone contact area.

PURPOSE

The purpose of this study was to assess functional outcome of arthroscopic single row rotator cuff repair in patients of age group more than 65 and assess healing status radiologically in view of fatty atrophy, tear retraction and arthritic changes.

HYPOTHESIS

We hypothesize that arthroscopic single row rotator cuff repair should heal well radiologically and give good functional results in age group more than 65 years in cost effective manner(using lesser anchor) despite fatty atrophy, arthritis and tear retraction.

BIOMECHANICS

- Deltoid and supraspinatus muscles - Coronal force couple
- Subscapularis and infraspinatus muscles- Axial force couple.
- Rotator cuff muscle compress the humeral head to the glenoid during shoulder abduction and which provides joint stability.
- A tear in cuff can interfere with these force couples, causing the humeral head to migrate superiorly and increasing the likelihood of cuff impingement between the greater tuberosity and the acromion.
- As the tear size increases, the forces needed to move the arm also rise, contributing to further anterior or posterior extension of the tear.
- The absence of load sharing by the torn tendons elevates the tensile stress on the remaining

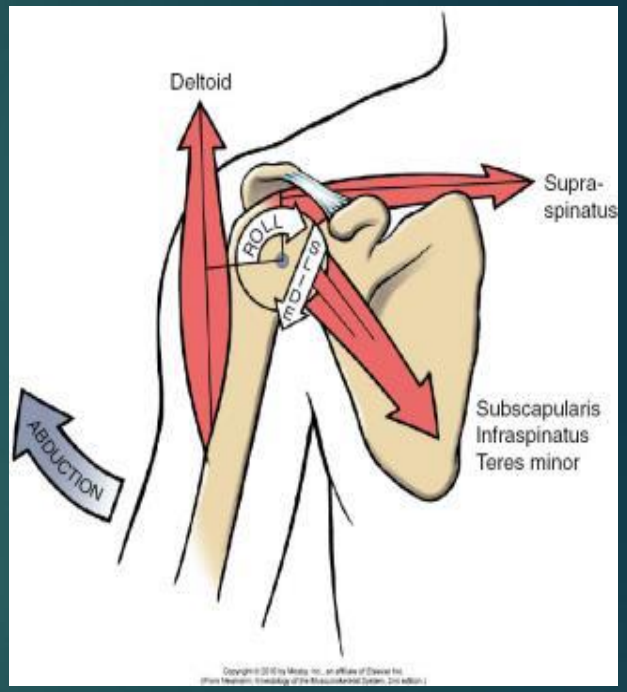

METHODOLOGY

- STUDY TYPE-A retrospective monocentric study
- DURATION- between July 2017 and January 2023
- SAMPLE SIZE-35 Shoulders (14 Male and 17 Female)
- MINIMUM FOLLOW UP- 9 Months
- MEAN FOLLOW-UP- 40 months

Patte's classification

Small (< 1 cm)
Medium (1–3 cm)
Large (3–5 cm)
Massive (> 5 cm)

INCLUSION CRITERIA

(1) Rotator cuff full-thickness tears (2)
(2) Age > 65 and above at the time of surgery;
(3) Participation in follow-up for a minimum of 9 month

EXCLUSION CRITERIA

(1) Irreparable full-thickness tears with fatty infiltration greater than stage III.
(2) Partial Rotator cuff tear
(3) Revision rotator cuff repair surgery
(4) neurological disorder of upper limb

EVALUATION

- Clinical examination and radiological investigations done for all the patients.
- Constant score, University of California, Los Angeles (UCLA) score, simple shoulder test score, and VAS score during pre- and post-operative phases
- At 9 months follow-up ultrasonography for Sugaya grading and re-tears assessment was done by an experienced musculoskeletal radiologist

IMPORTANT OPERATIVE STEPS

- Subacromial space decompression.
- Adhesions were removed, allowing the cuff to move freely.
- The cancellous bone bed was created using a motorized shaver system.
- The edges of the torn cuff were revitalized using duckbill forceps and a motorized shaver system.
- Complete rotator cuff repairs done in all cases.
- Reverse shoulder replacement kept ready in OT.

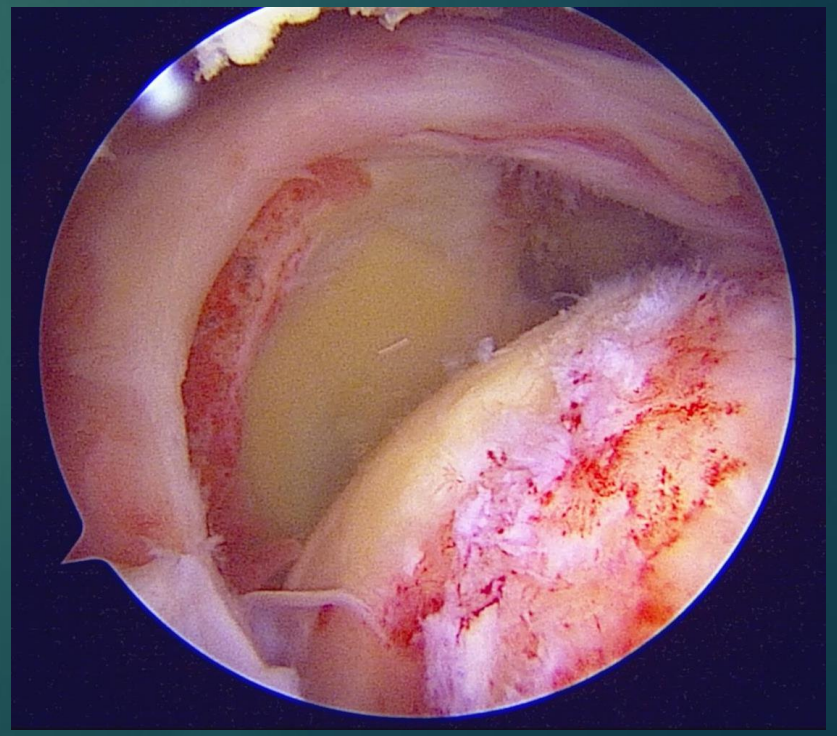

RESULTS

Variables	Pre-operative	Post-operative	P value
external rotation at side	66.45 ± 9.50	85.16 ± 5.08	<0.001
ER	70.32 ± 9.48	87.42 ± 4.45	<0.001
IR	39.52 ± 12.67	71.29 ± 9.22	<0.001
AFF	106.77 ± 26.88	170.00 ± 7.75	<0.001
MRC	2.84 ± 0.45	5.00 ± 0.00	<0.001
CMS	71.13 ± 5.89	98.35 ± 3.94	<0.001
UCLA	23.52 ± 2.26	34.42 ± 1.29	<0.001
STS	6.52 ± 0.85	11.71 ± 0.46	<0.001
VAS	9.23 ± 1.20	14.7 ± 0.3	<0.001
AHD	6.03 ± 1.52	8.45 ± 2.15	<0.001

DISCUSSION

- This study showed a notable improvement in Constant score, UCLA, and Simple shoulder score after surgery even in retears cases.
- .Oh et al and Denard demonstrated similar results indicating that ARCR should be the primary treatment for large-massive rotator cuff in the absence of arthritis. (American Journal of Sports Medicine)
- Melillo stated that primary rotator cuff repair is highly recommended even for patients with massive cuff tears
- Gerber reported good functional outcomes with low retears.(JBJS)
- Burkhart showcased patients with massive tear treated arthroscopically having good range of motion and no difficulty in routine life. (Arthroscopy - Journal of Arthroscopic and Related Surgery)
- Despite early retears, Paxton found that clinical improvement and pain alleviation was long-lasting at the 10-year follow-up(JBJS)

Review > J Am Acad Orthop Surg. 2011 Nov;19(11):657-66.
doi: 10.5435/00124635-201111000-00002.

Arthroscopic revision rotator cuff repair

Patrick J Denard [1], Stephen S Burkhart

> Arthroscopy. 2018 Mar;34(3):771-780. doi: 10.1016/j.arthro.2017.08.255.

Arthroscopic Correction of the Critical Shoulder Angle Through Lateral Acromioplasty: A Safe Adjunct to Rotator Cuff Repair

Christian Gerber [1], Sabrina Catanzaro [2], Michael Betz [2], Lukas Ernstbrunner [3]

Comparative Study > Arthroscopy. 2001 Nov-Dec;17(9):905-12. doi: 10.1053/jars.2001.26821.

Arthroscopic rotator cuff repair: Analysis of results by tear size and by repair technique-margin convergence versus direct tendon-to-bone repair

S S Burkhart [1], S M Danaceau, C E Pearce Jr

> J Bone Joint Surg Am. 2013 Apr 3;95(7):627-32. doi: 10.2106/JBJS.L.00255.

Clinical and radiographic outcomes of failed repairs of large or massive rotator cuff tears: minimum ten-year follow-up

E Scott Paxton [1], Sharlene A Teefey, Nirvikar Dahiya, Jay D Keener, Ken Yamaguchi, Leesa M Galatz

Why Single row repair ?

- Single row repair(cost-effective) was done in all cases with average of 2.40 ± 0.49 anchors with 1 double loaded and 1 triple loaded anchor or 2 double loaded anchors.
- Key for rotator cuff fixation is not the quantity of anchors, but the number of functional sutures going from the anchors through the tendon.(Journal of Arthroscopic and Related Surgery)
- Mazzocca in laboratory setting reported no distinction between the single-row (SR) repair and double-row (DR) repair. Both repair group showed a load to failure of more than 250 N.(AJSM)
- Nicholas and Millet in their independent RCT showed excellent outcomes for SR or DR repair with good clinical scores in both

> Am J Sports Med. 2005 Dec;33(12):1861-8. doi: 10.1177/0363546505279575. Epub 2005 Oct 6.

Arthroscopic single-row versus double-row suture anchor rotator cuff repair

Augustus D Mazzocca [1], Peter J Millett, Carlos A Guanche, Stephen A Santangelo, Robert A Arciero

Review > J Shoulder Elbow Surg. 2014 Apr;23(4):586-97. doi: 10.1016/j.jse.2013.10.006. Epub 2014 Jan 8.

Clinical and structural outcomes after arthroscopic single-row versus double-row rotator cuff repair: a systematic review and meta-analysis of level I randomized clinical trials

Peter J Millett [1], Ryan J Warth [2], Grant J Dornan [2], Jared T Lee [2], Ulrich J Spiegl [2]

Role of Subscapularis repair

- Subscapularis is the only anterior rotator cuff muscle, repairing it is essential for balancing posterior forces of the rotator cuff.
- Repairing subscapularis first render massive cuff tears ***repairable*** by decreasing tension on adjacent supraspinatus repairs (Barth,-Orthopedics and Traumatology: Surgery and Research)

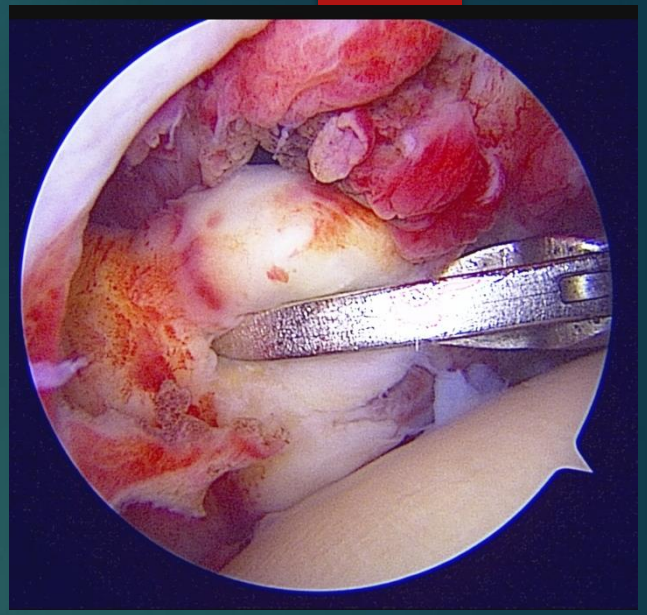

ROLE OF LONG HEAD OF BICEPS

- ***Persistent pain generator*** causing shoulder dysfunction.
- Arthroscopic Repair of cuff along with a biceps tenotomy results in excellent long-term shoulder function in elderly patients.(Boileau, Pascal - JSES)
- A simple, fast, effective and reproducible procedure and was performed in 9 cases yielding good outcomes.

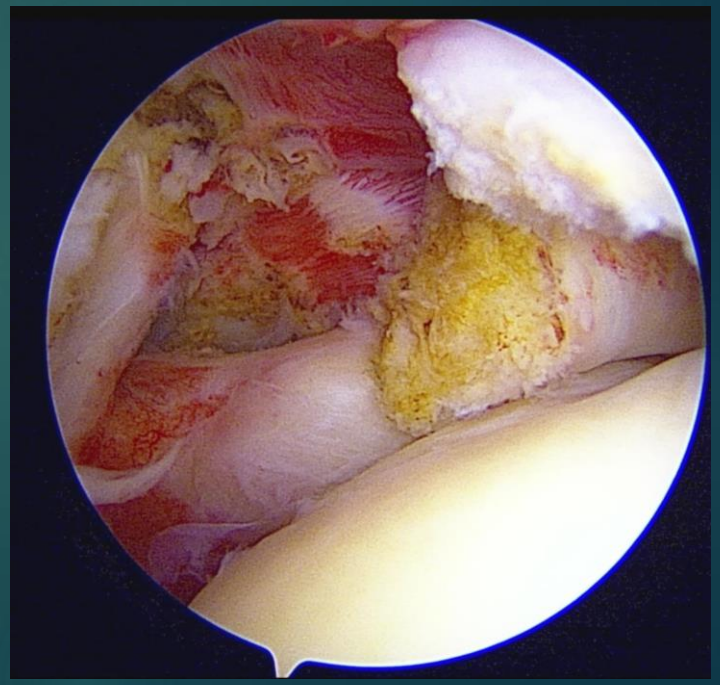

> J Bone Joint Surg Am. 2007 Apr;89(4):747-57. doi: 10.2106/JBJS.E.01097.

Isolated arthroscopic biceps tenotomy or tenodesis improves symptoms in patients with massive irreparable rotator cuff tears

Pascal Boileau [1], François Baqué, Laure Valerio, Philip Ahrens, Christopher Chuinard, Christophe Trojani

Medialised repair

- Attempting anatomic repair increases the tension leading to retear in chronic tears, severe muscle dystrophy, fatty infiltration and retraction of tendons.
- After mobilisation of tendon if ***tension free repair*** not possible, then anatomic footprint is medialised by creating new site for attachment with <8mm medialisation.
- 7 cases we performed medialised repair up to maximum 8 mm and all had significant improvement in functional score
- Goutallier highlighted importance of tension free repair which resulted in good clinical and functional outcome.(JSES)
- Taniguchi reported good results in 51 cases of 5 to 15 mm medialization(JSES)
- Chalmer and Snyder highlighted that **single-row medialized repair** might provide a lower-tension repair compared to a double-row repair, which could enhance cuff healing(Arthroscopy - Journal of Arthroscopic and Related Surgery)

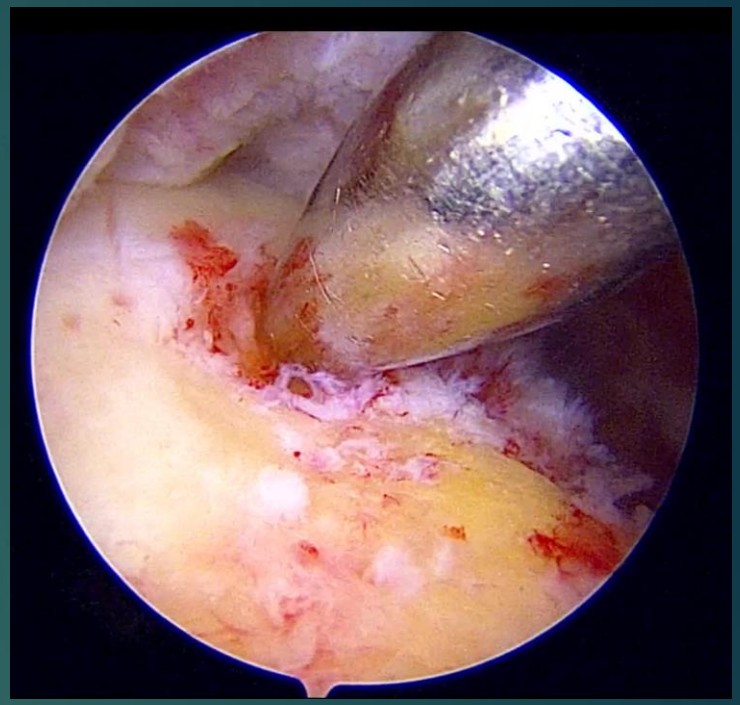

Editorial > Arthroscopy. 2019 Oct;35(10):2814-2816. doi: 10.1016/j.arthro.2019.06.010.

Editorial Commentary: Does a Medialized Repair Allow Single-Row to Outperform Double-Row Rotator Cuff Repair?

Peter N Chalmers [1]

REVERSE SHOULDER REPLACEMENT

- RSA is indicated for Advanced cuff arthropathy, irreparable RC tears and glenohumeral osteoarthritis.
- RSA has higher cost and associated with short and long term complications like infection, dislocation, loosening, neuropathy, scapular notching etc.
- Makhni's cost-effectiveness study show that ARCR for patients over 65 with cuff tears is evidently more cost-effective than primary RSR when analysing QALY (Journal of Arthroscopic and Related Surgery).

CONCLUSION

We found 98.3 % good to excellent result in clinical and functional outcomes after single row arthroscopic rotator cuff repair in patients aged >65 years in absence of cuff tear arthropathy.

REFERENCES

1. Hattrup SJ. Rotator cuff repair: Relevance of patient age. 1995.
2. Rhee YG, Cho NS, Yoo JH. Clinical outcome and repair integrity after rotator cuff repair in patients older than 70 years versus patients younger than 70 years. Arthroscopy - Journal of Arthroscopic and Related Surgery. 2014;30(5):546–54.
3. Arora M, Sohan S, Sinha AK. Functional outcomes are improved after rotator cuff repair in the Indian population: A systematic review. Vol. 8, Journal of Arthroscopy and Joint Surgery. Reed Elsevier India Pvt. Ltd.; 2021. p. 57–63.
4. Tempelhof S, Rupp S, Seil R. Age-related prevalence of rotator cuff tears in asymptomatic shoulders.
5. Fehringer E V., Sun J, VanOeveren LS, Keller BK, Matsen FA. Full-thickness rotator cuff tear prevalence and correlation with function and co-morbidities in patients sixty-five years and older. J Shoulder Elbow Surg. 2008 Nov;17(6):881–5.
6. Brewer BJ. Aging of the rotator cuff*.
7. Bhatia S, Greenspoon JA, Horan MP, Warth RJ, Millett PJ. Two-year outcomes after arthroscopic rotator cuff repair in recreational athletes older than 70 years. American Journal of Sports Medicine. 2015 Jul 3;43(7):1737–42.
8. Hantes ME, Ono Y, Raoulis VA, Doxariotis N, Venouziou A, Zibis A, et al. Arthroscopic Single-Row Versus Double-Row Suture Bridge Technique for Rotator Cuff Tears in Patients Younger Than 55 Years: A Prospective Comparative Study. American Journal of Sports Medicine. 2018 Jan 1;46(1):116–21.
9. Wall LB, Keener JD, Brophy RH. Double-row vs single-row rotator cuff repair: A review of the biomechanical evidence. Vol. 18, Journal of Shoulder and Elbow Surgery. 2009. p. 933–41.
10. Genuario JW, Donegan RP, Hamman D, Bell JE, Boublik M, Schlegel T, et al. The cost-effectiveness of single-row compared with double-row arthroscopic rotator cuff repair. Journal of Bone and Joint Surgery. 2012 Aug 1;94(15):1369–77.
11. Sahu AK, Moran EK, Gandikota G. Role of ultrasound and MRI in the evaluation of postoperative rotator cuff. Vol. 23, Journal of Ultrasonography. Walter de Gruyter GmbH; 2023. p. E188–201.
12. Cofield RH. Rotator cuff disease of the shoulder. JBJS. 1985 Jul;67(6):974–079.
13. Lädermann A, Burkhart SS, Hoffmeyer P, Neyton L, Collin P, Yates E, et al. Classification of full-thickness rotator cuff lesions: A review. Vol. 1, EFORT Open Reviews. British Editorial Society of Bone and Joint Surgery; 2016. p. 420–30.
14. Somerson JS, Hsu JE, Gorbaty JD, Gee AO. Classifications in Brief: Goutallier Classification of Fatty Infiltration of the Rotator Cuff Musculature. Clin Orthop Relat Res. 2016 May 1;474(5):1328–
15. Constant CR, Murley AH. A clinical method of functional assessment of the shoulder. Clin Orthop Relat Res [Internet]. 1987 Jan [cited 2018 Aug 19];(214):160–4. Available from: http://www.ncbi.nlm.nih.gov/pubmed/3791738
16. The UCLA Shoulder Rating Scale.
17. Witney-Lagen C, Mazis G, Bruguera J, Atoun E, Sforza G, Levy O. Do elderly patients gain as much benefit from arthroscopic rotator cuff repair as their younger peers? J Shoulder Elbow Surg. 2019 Jun 1;28(6):1056–65.
18. romeo ftrct.
19. Gladstone JN, Bishop JY, Lo IKY, Flatow EL. Fatty infiltration and atrophy of the rotator cuff do not improve after rotator cuff repair and correlate with poor functional outcome. American Journal of Sports Medicine. 2007 May;35(5):719–28.
20. Goutallier D, Postel JM, Bernageau J, Lavau L, Voisin MC. CLINICAL ORTHOPAEDICS AND RELATED RESEARCH Number 304, pp 78-83 Fatty Muscle Degeneration in Cuff Ruptures Pre-and Postoperative Evaluation by CT Scan.