# A novel surgical approach for the surgical treatment of anterior glenoid rim fracture (Ideberg Type Ia) −Anteroinferior axillary approach−

Yukitaka Fujisawa MD, PhD[1)], Akihiko Hasegawa MD, PhD[2)],

Mutsumi Ohue MD[1)], Teruhisa Mihata MD, PhD[2)]

1) Department of Orthopedic Surgery, Katsuragi Hospital
2) Department of Orthopedic Surgery, Osaka Medical and Pharmaceutical University

Yukitaka Fujisawa MD, PhD

I have no financial conflict to disclose.

# Introduction

- Glenoid fossa fractures are relatively rare, accounting for 0.1%of all fractures.
- The Ideberg classification is often used to classify fracture types, and anterior rim of the scapular glenoid fossa fractures (Ideberg Type Ia) account for approximately 8% of scapular fractures.
- Deltopectoral approach is commonly used for the surgical treatment.

# Purpose

To introduce Anteroinferior Axillary Approach for the treatment of anterior glenoid rim fracture.

# Materials and Methods

## Patients

- From April 2020- March 2024
- Acute Glenoid rim fracture (Ideberg Type Ia)

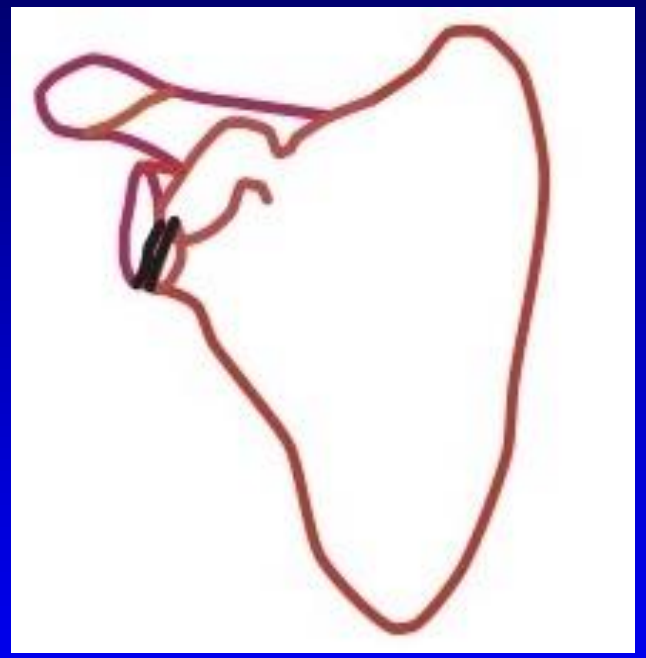

Exclusion Criteria

- Chronic fracture
- Concomitant proximal humerus fracture requiring ORIF

- 7 Patients (2 Male and 5 Female)

# Operation Methods

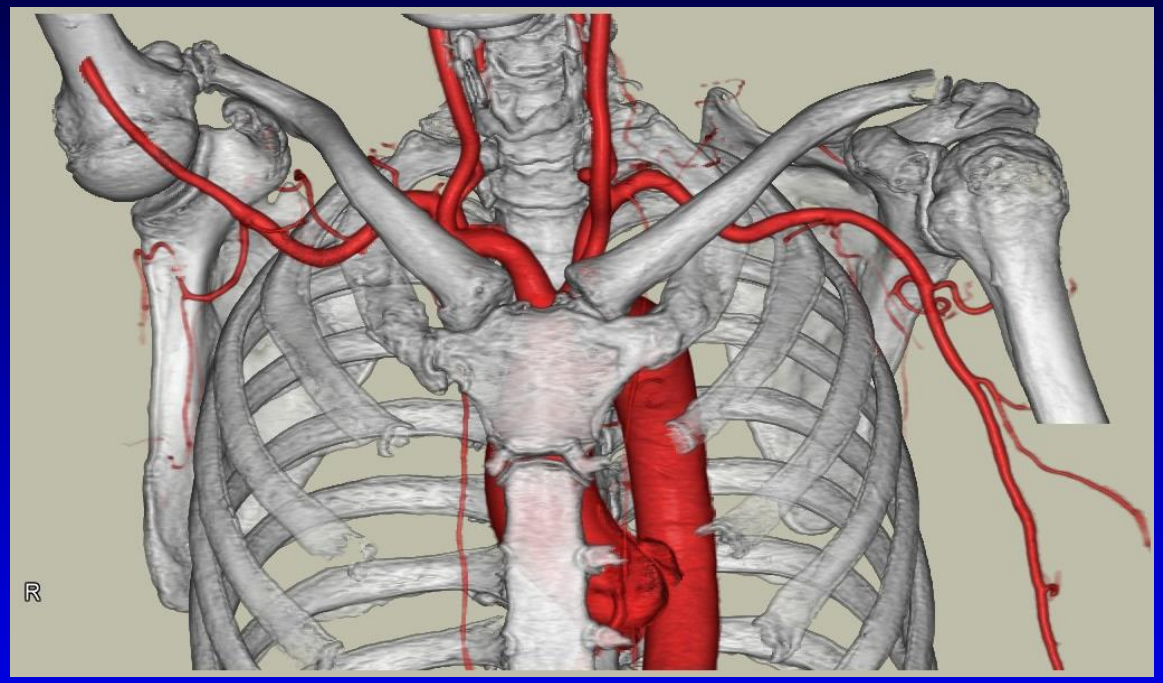


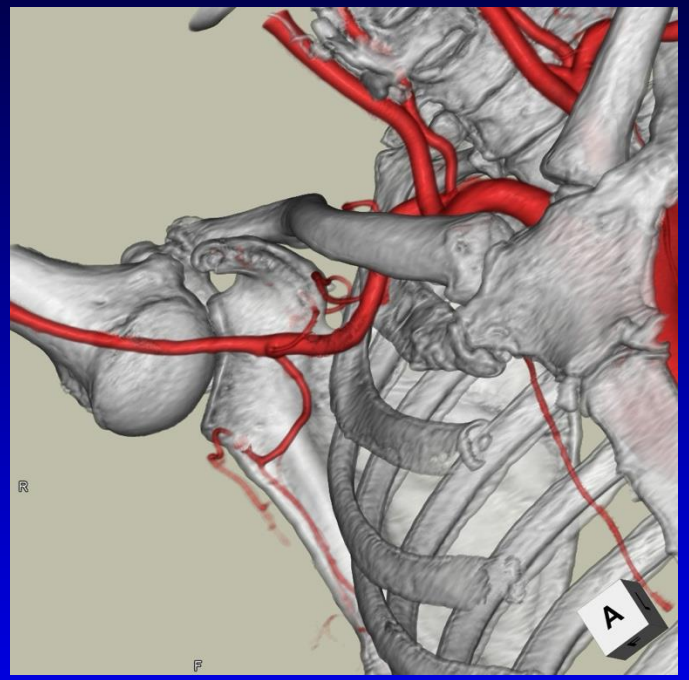


The position of the upper extremity in abduction and external rotation allows the axillary neurovascular bundle to escape superiorly.

# Operation Methods : Positioning & Skin incision

- Patients were placed in supine position with upper extremity in abduction and external rotation position.
- Fluoroscopy was set to true AP view
- A small skin incision (2-3cm) was made anteroinferior axillary along the Langer's line.
- The soft tissue was bluntly dissected to reach the glenoid rim.

# Operation Methods : Open reduction

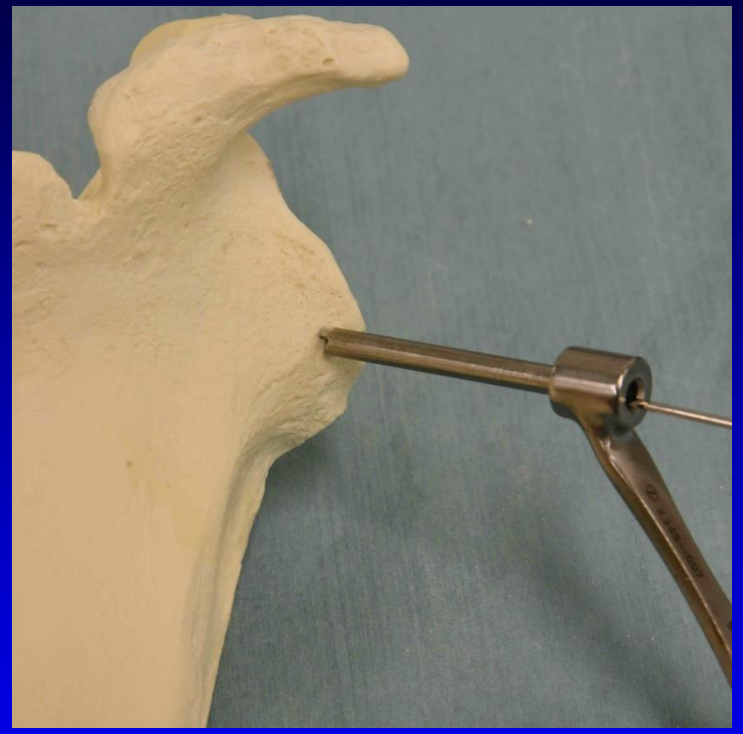
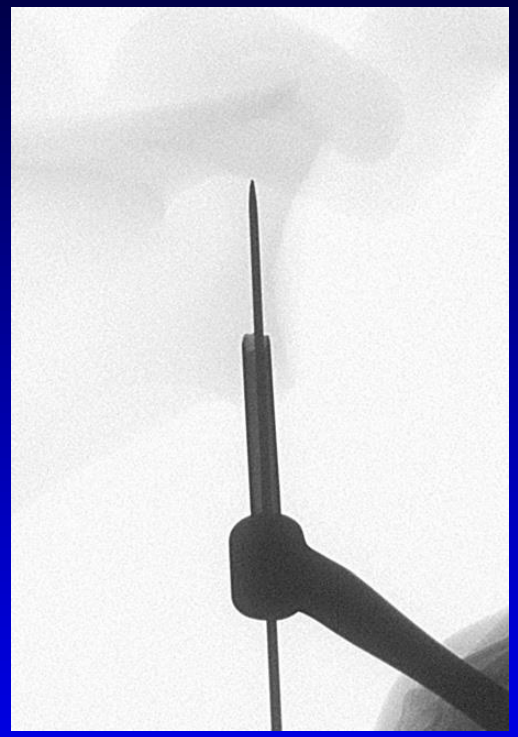



Open reduction was performed by pushing the bone fragments using a drill guide.

# Operation Methods : Guide sleeve & Internal fixation



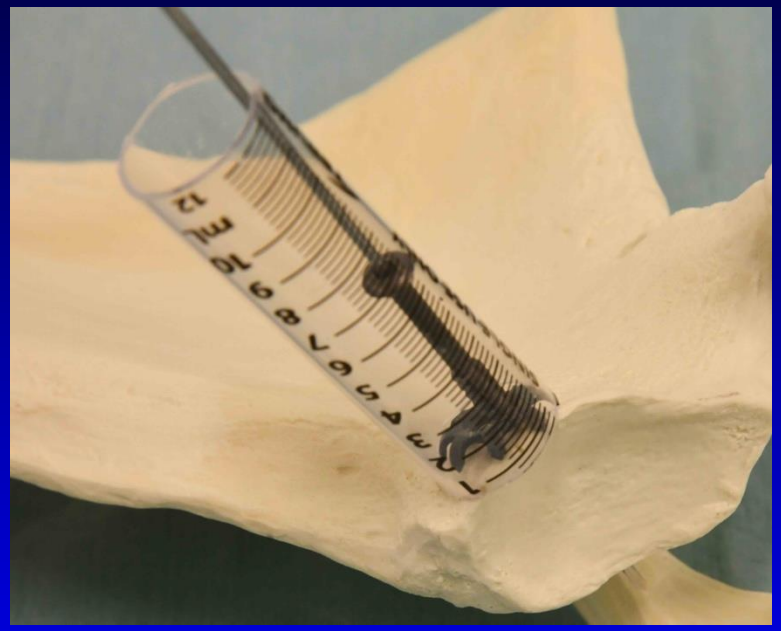



A 10-cc syringe with both ends cut off was used as a guide sleeve to prevent the entrapment of the neurovascular bundle.

The bone fragment was fixed with a 4.0-mm cannulated screw with a spike washer.

# Operation Methods : Fluoroscopic images

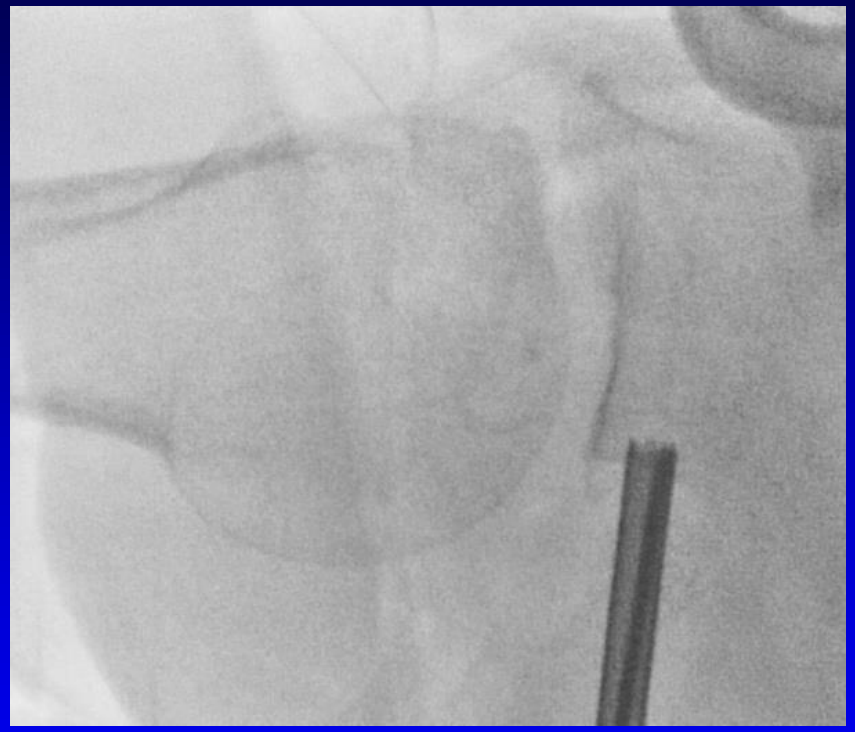

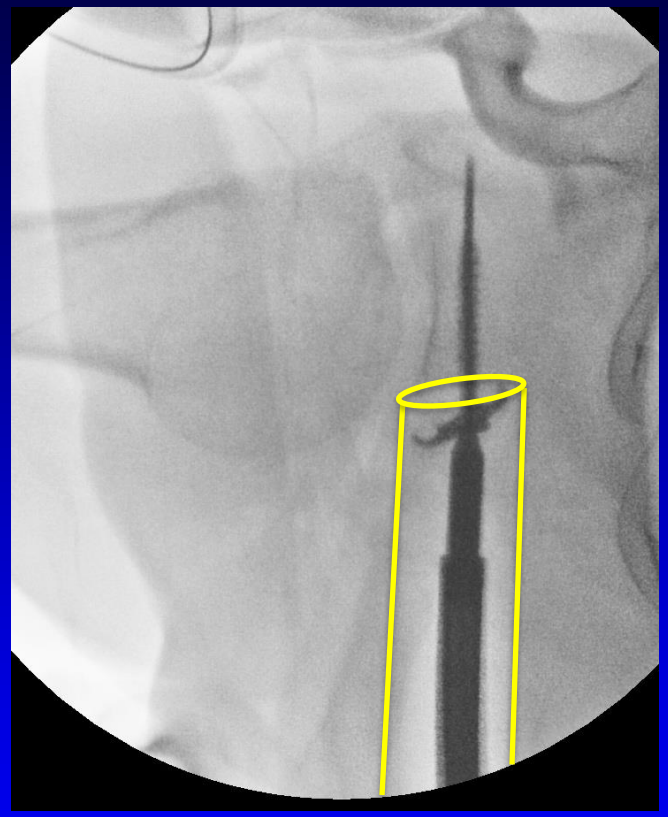

All procedures were performed under fluoroscopic guidance

# Results: Clinical outcomes (n=7)

- 7 cases : 2male 5 female
- Age: 72.8 years old (46-92 years)
- Bone fragment width: 36.9% (28.4-43.6%)
- Operation Time mean 40.7min (19-70min)
- Immobilized for 3 weeks using a sling

- The active shoulder range of motion 6 months after surgery

Flexion 148° (120-160), Abduction 147° (120-160)
External Rotation 58° (30-75), Internal Rotation T11 (L2-Th8)

All cases achieved bone union and full recovery to perform daily activities after surgery.

# Case1: Male 46y.o.

Bone fragment size 28.4%
Operation Time 35min
ROM Flex:160, Abd:160, ER:60, IR:Th8

# Tips & Tricks

If the MED (Micro Endoscopic Discectomy) device is available in stead of 10-cc syringe, the procedure will be easier and safer to perform.

# Conclusions

- Anteroinferior axillary approach is easy, minimally invasive, and useful approach to treat glenoid rim fracture (Ideberg Type-Ia).
- With optimal limb positioning and the use of a guide sleeve, surgeons can treat the glenoid rim fracture without damaging the neurovascular bundle.