ISAKOS CONGRESS 2025 | MUNICH GERMANY June 8–11

All-Inside Endoscopic Classic Bröstrom-Gould Technique – Medium Term Results

Choon Chiet HONG MBBS, MMed (Ortho), MPH, FRCSEd (Orth), SINGAPORE [PRESENTER]

Christel CHARPAIL MD, FRANCE

Charles KON Kam King MBBS, FRCS, SINGAPORE

Stéphane GUILLO MD, FRANCE

Faculty Disclosure Information

My disclosures are:

Gen Secretary – ESSKA AFAS

Associate Editor – KSSTA

Faculty – AO Trauma

Editorial Board Member – JOFAS

I receive honorarium from speaking in educational programme by Arthrex on ad-hoc basic unrelated to this study

Introduction 1

- Lateral ligament sprain is especially **common in active sporting community** and has significant burden on **physical function, quality of life and healthcare economies** [1-3]

- **Up to 70%** of patient with acute lateral ligament sprain can experience **residual symptoms** such as reinjury, pain, weakness and recurrent instability leading to the sequela of **chronic lateral ankle instability (CLAI)** [3-5]

- In those who failed nonoperative treatment, surgical stabilization of the lateral ligaments have shown good long term outcomes [3,6,7]

- **Anatomical direct repair** of lateral ligaments is the most commonly used surgical repair procedure where the most commonly used technique is the **Brostrom-Gould procedure** due to its reproducibility and excellent long term outcomes [8-10]

1) Herzog MM, Kerr ZY, Marshall SW, Wikstrom EA. Epidemiology of Ankle Sprains and Chronic Ankle Instability. J Athl Train. 2019 Jun;54(6):603-610.

2) Roos KG, Kerr ZY, Mauntel TC, Djoko A, Dompier TP, Wikstrom EA. The Epidemiology of Lateral Ligament Complex Ankle Sprains in National Collegiate Athletic Association Sports. Am J Sports Med. 2017 Jan;45(1):201-209.

3) Hong CC, Calder J. The Burden of the "Simple Ankle Sprains": A Review of the Epidemiology and Long-Term Impact. Foot Ankle Clin. 2023 Jun;28(2):187-200.

4) Anandacoomarasamy A, Barnsley L. Long term outcomes of inversion ankle injuries. Br J Sports Med. 2005 Mar;39(3):e14; discussion e14.

5) Gribble PA, Bleakley CM, Caulfield BM, Docherty CL, Fourchet F, Fong DT, Hertel J, Hiller CE, Kaminski TW, McKeon PO, Refshauge KM, Verhagen EA, Vicenzino BT, Wikstrom EA, Delahunt E. Evidence review for the 2016 International Ankle Consortium consensus statement on the prevalence, impact and long-term consequences of lateral ankle sprains. Br J Sports Med. 2016 Dec;50(24):1496-1505.

6) Guillo S, Bauer T, Lee JW, Takao M, Kong SW, Stone JW, Mangone PG, Molloy A, Perera A, Pearce CJ, Michels F, Tourné Y, Ghorbani A, Calder J. Consensus in chronic ankle instability: aetiology, assessment, surgical indications and place for arthroscopy. Orthop Traumatol Surg Res. 2013 Dec;99(8 Suppl):S411-9.

7) Matsui K, Burgesson B, Takao M, Stone J, Guillo S, Glazebrook M; ESSKA AFAS Ankle Instability Group. Minimally invasive surgical treatment for chronic ankle instability: a systematic review. Knee Surg Sports Traumatol Arthrosc. 2016 Apr;24(4):1040-8.

8) Chang SH, Morris BL, Saengsin J, Tourné Y, Guillo S, Guss D, DiGiovanni CW. Diagnosis and Treatment of Chronic Lateral Ankle Instability: Review of Our Biomechanical Evidence. J Am Acad Orthop Surg. 2021 Jan 1;29(1):3-16.

9) Guillo S, Bauer T, Lee JW, Takao M, Kong SW, Stone JW, Mangone PG, Molloy A, Perera A, Pearce CJ, Michels F, Tourné Y, Ghorbani A, Calder J. Consensus in chronic ankle instability: aetiology, assessment, surgical indications and place for arthroscopy. Orthop Traumatol Surg Res. 2013 Dec;99(8 Suppl):S411-9.

10) Attia AK, Taha T, Mahmoud K, Hunt KJ, Labib SA, d'Hooghe P. Outcomes of Open Versus Arthroscopic Broström Surgery for Chronic Lateral Ankle Instability: A Systematic Review and Meta-analysis of Comparative Studies. Orthop J Sports Med. 2021 Jul 21;9(7):23259671211015207.

Introduction 2

- Arthroscopic techniques for Brostrom-Gould procedure is gaining popularity with many studies published in the recent years reporting similar/superior outcomes (functional score, pain score, earlier return to sports). However, these studies are mostly **retrospective** with **short term** outcomes and **inadequately described technique** [1]

- Specifically, the purported all-arthroscopic technique only **partially replicate** the classical open Brostrom-Gould procedure because the superior fascicle of the ATFL is **intracapsular** while the inferior fascicle of ATFL which connects to the CFL via the arciform fibers are **extracapsular** [2]

- Hence, the supposed all-arthroscopic technique **CANNOT reproduce** the standard Brostrom-Gould procedure where there is a complete capsuloligamentous repair with IER augmentation

- Most of the all-inside techniques have **only repaired the intracapsular** structures while some have addressed this issue by adding a **mini-open or percutaneous** approach to reach those extracapsular structures

1) Attia AK, Taha T, Mahmoud K, Hunt KJ, Labib SA, d'Hooghe P. Outcomes of Open Versus Arthroscopic Broström Surgery for Chronic Lateral Ankle Instability: A Systematic Review and Meta-analysis of Comparative Studies. Orthop J Sports Med. 2021 Jul 21;9(7):23259671211015207.

2) Dalmau-Pastor M, El-Daou H, Stephen JM, Vega J, Malagelada F, Calder J. Clinical Relevance and Function of Anterior Talofibular Ligament Superior and Inferior Fascicles: A Robotic Study. Am J Sports Med. 2023 Jul;51(8):2169-2175.

Aim

- We aim to **evaluate** the **medium term** functional outcomes and complication rates of an **all-inside endoscopic classic Brostrom-Gould technique** for patients with CLAI

- We **hypothesize** that this all-inside endoscopic technique allows direct visualization and access to both ATFL+CFL ligaments and the IER

Method 1

- Retrospective review of **prospectively kept database** since 2015
- All patients treated with the all-inside endoscopic classic Brostrom-Gould technique for CLAI by senior author
- **Inclusion** - CLAI, mechanical instability on clinical examination, ATFL/CFL injury seen on Ultrasound and CT arthrography, failed nonsurgical treatment for at least 3 months, good remnant ligaments for repair (grade 1 and 2 ATFL)
- **Exclusion** - concomitant fractures, previous surgery, revision cases, ligament reconstruction cases, concurrent syndesmosis or cartilage lesions

- Demographic data, intraoperative details (tourniquet time, duration of follow up)
- Outcome measures - AOFAS score, Karlsson score, Ankle activity score (AAS) and patient satisfaction
- Failure of surgical treatment was defined as recurrent instability as this was the most commonly cited definition in the literature
- Surgical technique was previously described by Guillo et al[1] where the approach can be **INTERCHANGED** between **arthroscopy for intracapsular** structures and **endoscopy for the extracapsular** structures

1) Guillo S, Odagiri H. All-Inside Endoscopic Broström-Gould Technique. Arthrosc Tech. 2019 Dec 18;9(1):e79-e84

Method 2

Sequence of steps

Figure 1; Patient placed in semi lateral position allowing the free and easy external (position 1) or internal rotation (position 2) of the leg to allow interchanging of anterior arthroscopic approach (position 1) to endoscopic approach (position 2).

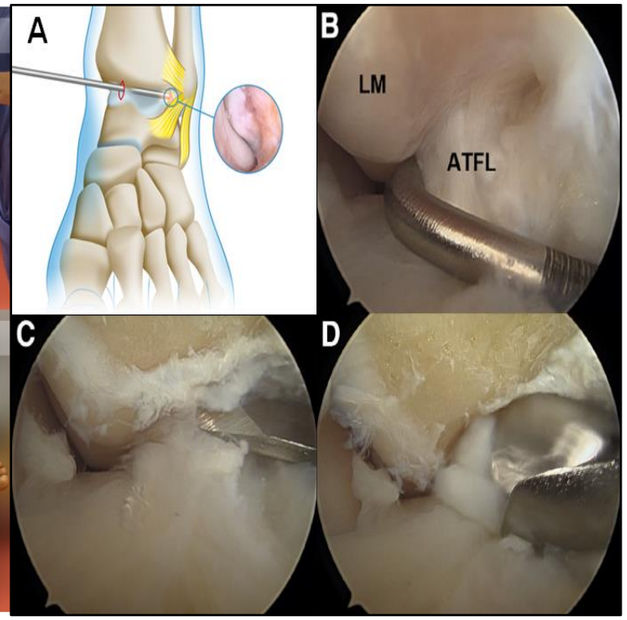

Figure 2 : 2A illustrating anterior ankle arthroscopy with the routine AM portal made medial to the tibialis anterior tendon with ankle in dorsiflexion. 2B showed the ATFL ligament and its corresponding footprint. 2C-2D depicted the release of the ATFL from the fibula footprint using beaver blade and its footprint prepared using a bone shaver to improve biological healing. AM, anteromedial; LM, lateral malleolus; ATFL, anterior talofibular ligament

Figure 3: 3A showed the creation of the endoscopic working space between the skin and IER using the trocar. 3B illustrated the creation of the endoscopic lateral portal at 2cm anterosuperior to the mid-distance point between the base of the fifth metatarsal and the tip of the fibula. 3C showed the placement of the arthroscope in the endoscopic lateral portal while the shaver is in the AL portal. IER, inferior extensor retinaculum; AL, anterolateral.

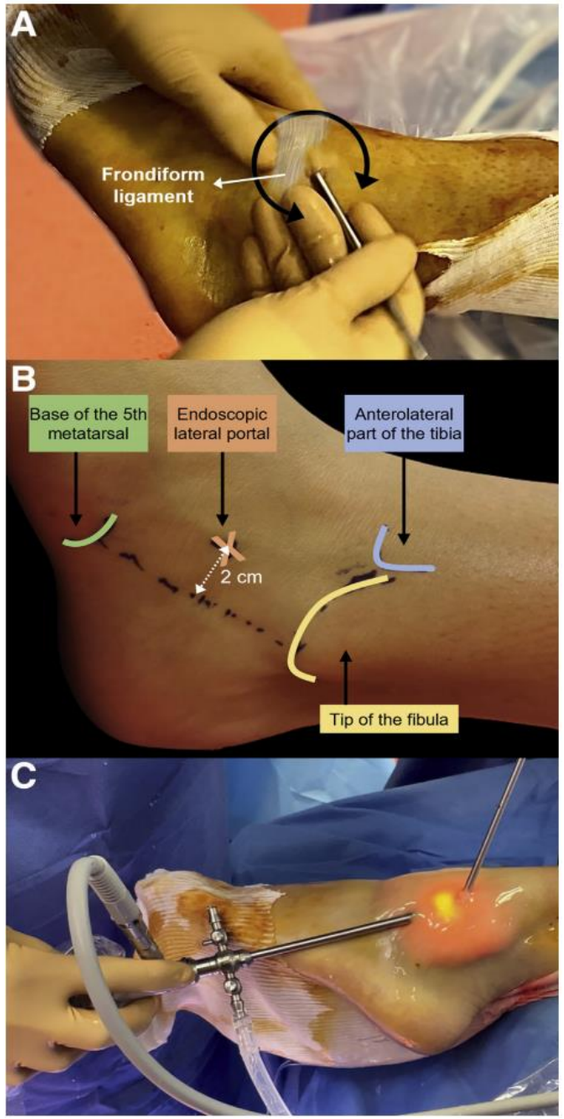

Figure 4: 4A demonstrated the view from the EL portal viewing towards the AL portal while the probe highlighted the previously made AL portal there the dissection begins. 4B showed the dissection deepened down to the CFL insertion at the fibula running further inferiorly deep to the fibular tendons. 4C showed the obscure tubercle which is an important landmark separating the ATFL and CFL footprint. EL, endoscopic lateral; AL, anterolateral; CFL, calcaneofibular ligament; ATFL, anterior talofibular ligament.

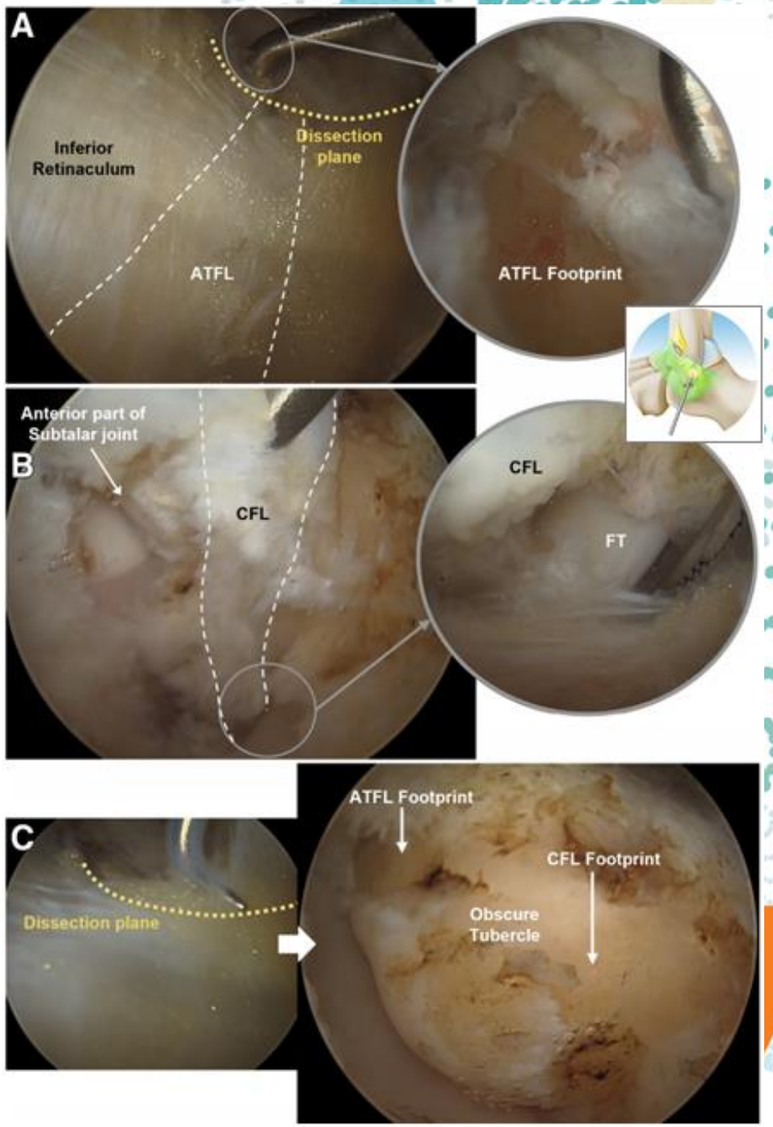

ISAKOS CONGRESS 2025 | MUNICH GERMANY June 8–11

1) Guillo S, Odagiri H. All-Inside Endoscopic Broström-Gould Technique. Arthrosc Tech. 2019 Dec 18;9(1):e79-e84

Method 3

Sequence of steps

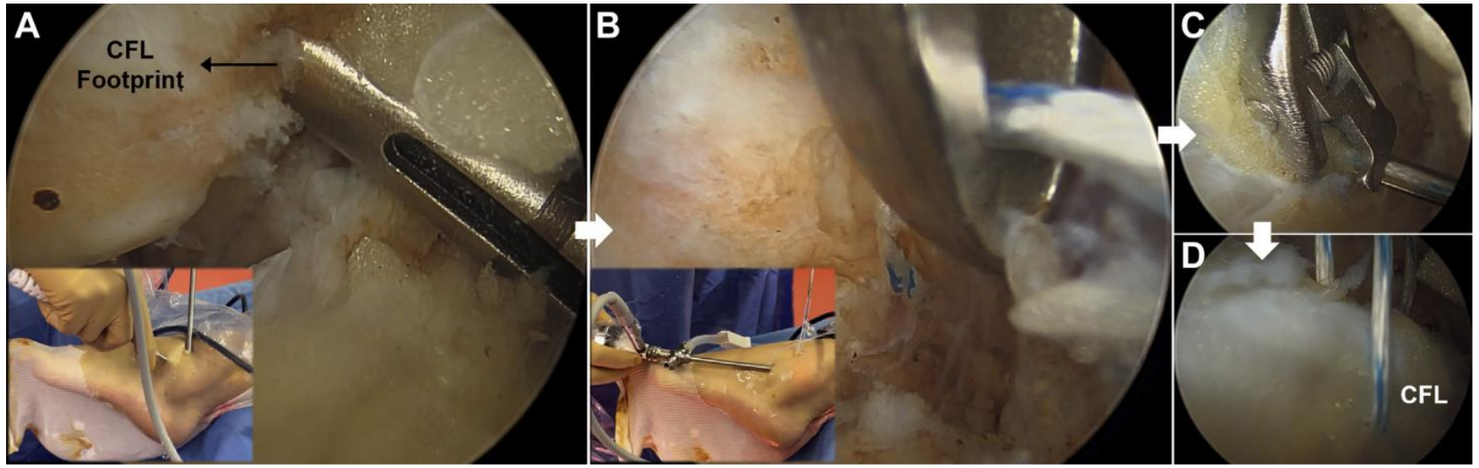

Figure 5: 5A showed the placement of the CFL anchor via the EL portal at the footprint just inferior to the obscure tubercle while using the AL portal as the viewing portal. 5B demonstrated the retrieval of the sutures from the AL portal when the arthroscope is exchanged back to the EL portal as the viewing portal. 5C and 5 D showed the usage of Mini Scorpion to pass one strand of the suture through CFL and another through IER respectively while retrieving them out of the AL portal again. CFL, calcaneofibular ligament; EL, endoscopic lateral; AL, anterolateral; IER, inferior extensor retinaculum.

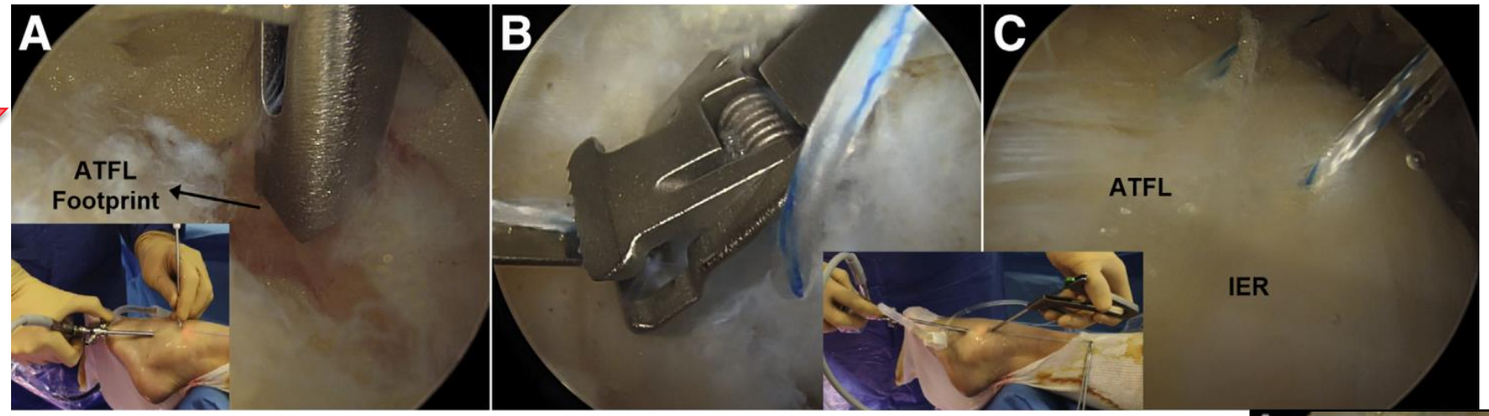

Figure 6: 6A showed the arthroscope in the EL portal while the second suture anchor is inserted via the AL portal at the ATFL footprint superior to the obscure tubercle. 6B and 6C illustrated the use of Mini Scorpion to pass one strand of the suture through ATFL and the other strand through IER respectively. EL, endoscopic lateral; AL, anterolateral; ATFL, anterior talofibular ligament; IER, inferior extensor retinaculum.

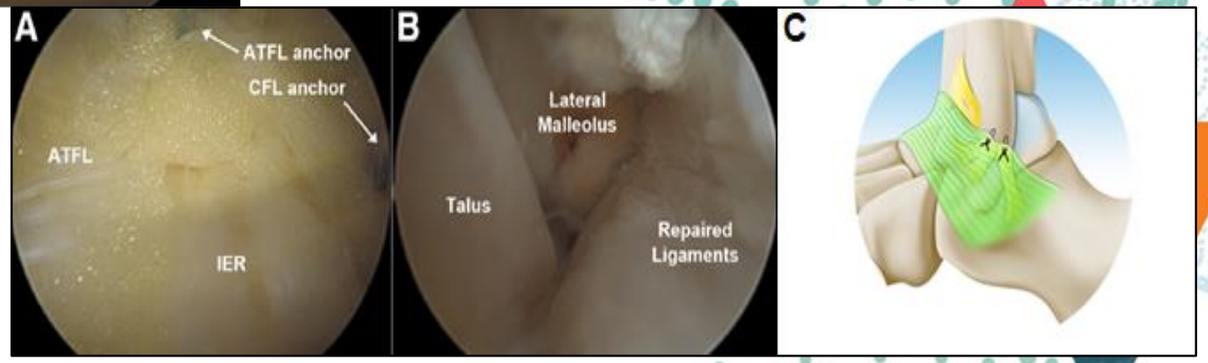

Figure 7: 7A showed final inspection of the repaired ligaments via endoscopic view from the EL portal while 7B showed the final inspection of the repaired ligaments arthroscopically via the AL portal and 7C illustrated the classic Bröstrom-Gould repair. EL, endoscopic lateral; AL, anterolateral.

ISAKOS CONGRESS 2025 | MUNICH GERMANY June 8–11

1) Guillo S, Odagiri H. All-Inside Endoscopic Broström-Gould Technique. Arthrosc Tech. 2019 Dec 18;9(1):e79-e84

Results 1

Characteristics	Study Cohort, n=43
Age, mean, (S.D.; range) years	29.4 (11.9; 13 - 57)
Gender, n (%) Male Female	 29 (67.4%) 14 (32.6%)
Weight, mean, (S.D.; range) kg	67.5 (14.8; 49 – 110)
Height, mean, (S.D.; range) cm	167.7 (7.9; 152 – 186)
BMI, mean, (S.D.; range) kg/m^2	23.9 (4.5; 18 – 39)
Level of sporting activities, n= 38, (%) *Leisure Competitive	 16 (42.1%) 22 (57.9%)
Tourniquet time, mean, (S.D.;range) minutes	27.7 (6.6; 18 – 45)
Follow up duration, mean, (S.D.;range) months	63.1 (8.5; 50 – 82)

Outcome Score*	Preoperative, n=43	Postoperative, n=43	Net improvement, n=43	p value
Karlsson Total Score, mean (S.D.)	59.7 (14.5)	91.5 (14.5)	31.8 (18.9)	0.000
AOFAS Score, mean (S.D.)	69.6 (13.9)	93.7 (10.7)	24.1 (15.4)	0.000
Satisfaction, mean (S.D.)		8.63 (2.0)		

- In terms of activity level, AAS showed **32 (74.4%)** patients maintained or had improvement in the AAS after surgery at 5.41 ± 2.8 from 5.38 ± 2.8 with an **average satisfaction rate of 9.1 ± 1.3.**
- Although the **remaining 11** patients had **decreased AAS at 4.6 ± 2.6 from 8.2 ± 1.8**, they demonstrated an **average satisfaction rate of 7.4 ± 2.9.**
- Among the 11 with decreased AAS, 7 reported a satisfaction rate of ≥ 8 while **2 reported satisfaction rate of ≥ 5.** The remaining 2 patients had a **drop in AAS from 9 to 3 and 8 to 2** with poor satisfaction rates of 3 and 2 respectively.
- There were 3 patients with recurrent instability at their last follow up after surgical treatment resulting in a failure rate of 7% (3 out of 43 patients). Despite that, there were no surgical complications or reoperations in this cohort.

Results 2

- When comparing the effect of age, gender, BMI and ATFL ligament grading on the outcome scores (AOFAS and Karlsson), satisfaction rate and AAS, there were no significant differences noted.

- However, when the BMI was divided **categorically** into being overweight (BMI ≥ 25 kg/m^2) or not, the mean AOFAS score at final follow-up was 96.8 for those patients with a BMI< 25 kg/m^2 and 88.1 for those wth a BMI≥ 25 kg/m^2 (p=0.052). The rest of the outcome measures were not significantly different between the patients who are overweight or not.

- Out of the 38 patients who self-reported their level of sporting engagements as recreational/leisurely versus competitive players, 16 (42.1%) patients who played sports leisurely had an average preoperative AAS of 4.7 ± 2.5 while the other 22 (57.9%) patients participating in sports competitively presented with an average preoperative AAS of 8.3± 1.0 which were statistically significantly different (p=0.000). This highlighted the consistency of self-reported level of sporting activities with the AAS.

- Patients who play sports recreationally/leisurely and competitively both had an overall mild reduction in the AAS with the recreational/leisurely players from 4.7 ± 2.5 to 4.0 ± 2.3 and competitive players from 8.3± 1.0 to 7.1 ± 2.2 at an average of 5 years.

Discussion

- The most important finding in this study is that the all-inside endoscopic Brostrom-Gould procedure **leads to excellent** functional outcomes in majority of patients and > 2/3 patients maintained their ankle activity level at an average **5 years** postoperatively with good satisfaction rate.

- This is important because there has been a lack of medium to long term follow up for arthroscopic lateral ligament repair techniques.

- To our knowledge, this is the first study to report medium term functional outcomes, activity level and satisfaction rate at an average of 5 years using a **single consistent all-inside endoscopic technique** that can visualize and access **both lateral ankle ligaments with Gould augmentation**

- There is currently no clear consensus on the definition of failure for surgical management of CLAI. Dallman et al reported in a recent systematic review of 42 studies that a myriad of definitions were present in the literature and the most commonly cited definition was recurrent instability followed by rerupture where the failure rate of the Bröstrom-Gould procedure could range from 1.1% to 45.2% depending on the definition provided in the study.

- Based on the most commonly cited definition of failure which is recurrent instability, the failure rate for this cohort would be 7% (3 out of 43 patients). Despite that, we are still unable to classify the remaining single patient with pain, stiffness and decreased AAS after lateral ligament repair without instability symptoms was a failure.

1) Dallman J, Wolf MR, Campbell T, Herda T, White J, Tarakemeh A, Vopat BG. Current Definitions of Failure in Lateral Ankle Instability Surgery: A Systematic Review. Am J Sports Med. 2023 Aug;51(10):2748-2757.

Limitation

- Small cohort of patients
- Single surgeon and lack of control group for comparison
- Possible selection bias due to recruitment by single surgeon but there is a strict set of inclusion and exclusion criteria
- Potential criticism that it may be technically demanding to perform this procedure endoscopically but it has been reported in a prospective study that it is safe and replicable even for a young surgeon[1]
- Only patients with good quality remnant ATFL (grade 1 and 2) were recruited

1) Lopes R, Andrieu M, Cordier G, Molinier F, Benoist J, Colin F, Thès A, Elkaïm M, Boniface O, Guillo S, Bauer T; French Arthroscopic Society. Arthroscopic treatment of chronic ankle instability: Prospective study of outcomes in 286 patients. Orthop Traumatol Surg Res. 2018 Dec;104(8S):S199-S205.

Conclusion

All-inside endoscopic classic Brostrom-Gould procedure for grade 1 and 2 ATFL lesions culminated in good functional outcomes in 93% of patients and > 2/3 of patients maintained ankle activity level at an average of 5 years with good satisfaction rate.