ISAKOS CONGRESS 2025 | MUNICH GERMANY June 8–11

Vascular Assessment in Multi-ligament Knee Injury – the Belfast Protocol

Chris Madden-McKee, Jonathan Warnock, Ciara Stevenson

Royal Victoria Hospital, Belfast, Northern Ireland

Faculty Disclosure Information

- All authors report no disclosures relevant to this project.

Introduction

- The incidence of vascular injury in the dislocated knee is quoted between 5-25% in the literature[1].
- 50% of knee dislocations may reduce spontaneously prior to attending hospital[2].
- Evidence-based protocols to assess vascular injury rely on the physician's ability to determine objective laxity in more than one ligament and appreciate that all MLKI have been dislocated until proven otherwise.[3].

Aims

- To identify predictors of vascular injury in multi-ligament knee injuries (MLKI).
- To create a protocol for vascular assessment in the emergency department to reduce the risk of missed arterial injury.

Methods

- Retrospective review of a database of MLKIs in a level 1 major trauma centre from 2019-2023.
- MLKI defined as disruption of at least 2 out of 4 of:
  - ACL, PCL, MCL (Posteromedial corner), LCL (Posterolateral corner)
- Digital records and MRI reports reviewed.

Results

- 73 knees were included.
- 34 knees (47%) were injured in high-energy mechanisms.
- 25 knees (34%) were injured playing sports.
- 5 cases (7%) of vascular injury.
- 12 cases (16%) of foot drop secondary to common peroneal nerve injury.

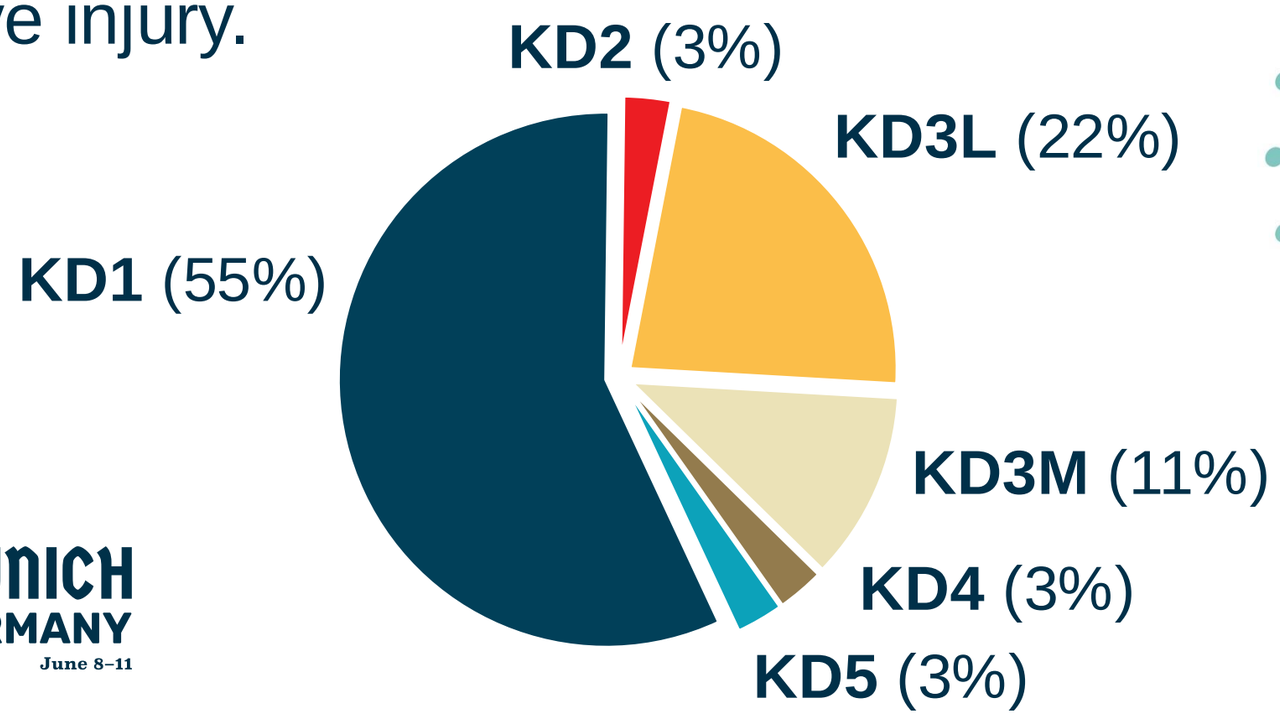

Results

- Of the 5 patients with confirmed vascular injury:
  - **ALL** were Schenk IIIL injuries.
  - **4/5** presented dislocated (the other gave clear history of dislocation with spontaneous reduction).
- Knees presenting dislocated – **100%** underwent CT Angiogram post reduction
- Knees presenting with clear history (or photographic evidence) of transient dislocation – **25%** (7/28) underwent CT Angiogram on presentation (ABPI not routinely performed in ED at this time)
- **NO** MLKIs (0/29) meeting the following criteria had vascular injury in this study:
  - Not dislocated on presentation and no clear history of transient dislocation
  - Absence of common peroneal nerve palsy

Discussion

- Our protocol has been updated accordingly.
- All knees that present dislocated proceed to urgent CT Angiography.
- Patients with a clear history (or video evidence) of a transient knee dislocation, with objective laxity in more than 1 ligament to include a lateral-sided injury +/- foot drop proceed to urgent CT Angiography
- All other MLKI require serial ABPIs in the Emergency Department

The Belfast Protocol

Patient presents with potential MLKI to ED

Knee not dislocated on presentation

Consider other differentials, including fracture, extensor mechanism disruption and patellar dislocation.

Low concern for MLKI – follow protocol for soft tissue knee injury ED referral pathway.

Knee dislocated on presentation

Reduce knee urgently and apply long leg backslab

Admit, Immediate CT Angiogram, Urgent MRI

Suspected MLKI

Clinical laxity in at least 2 out of 4 of: ACL/PCL/MCL/LCL

'Hard' clinical signs of vascular injury (e.g. reduced/absent pulses, prolonged CRT, pale/cold foot)

Admit, Immediate CT Angiogram and/or Vascular Surgery referral, Urgent MRI

Assess for high-risk features for arterial injury

1) Clear history (or photo/video evidence) of knee dislocation OR
2) Suspected lateral ligament injury OR
3) Foot drop (common peroneal nerve palsy)

Yes – Admit, Immediate CT Angiogram, Urgent MRI

No – Serial ABPI in ED, Acute knee clinic <1 week

ABPI <0.9 = Immediate CT Angiography

References

1. Medina O, Arom G, Yeranosian M, Petrigliano F, McAllister D. Vascular and Nerve Injury after knee dislocation: A systematic review. *Clin Orthop Relat Res* 2014 Sep;472(9):2621-2629
2. Wascher DC, Dvirnak PC, Decoster TA. Knee dislocation: Initial assessment and implications for treatment. *J Orthop Trauma* 1997;11(7):525-29
3. Nicandri G, Dunbar R, Wahl C. Are evidence-based protocols which identify vascular injury associated with knee dislocation underutilized? *Knee Surg Sports Traumatol Arthrosc* 2010;18:1005-1012