ISAKOS CONGRESS 2025 | MUNICH GERMANY June 8–11

Novel Classification System For Comprehensive Management of Complex Multi-Ligamentous Injuries(MLKI)- Knee Dislocation(KD) Type -V Injuries

Authors:

- *Dr Ramakanth R, Consultant, Dept Of Arthroscopy & Sports Medicine**
- *Dr SR Sundararajan, Dept Chief, Dept Of Arthroscopy & Sports Medicine**
- *Dr Terence Dsouza, Senior Registrar, Dept Of Arthroscopy & Sports Medicine**
- *Dr Suchit Chavan, Assistant Professor, Dept of Orthopaedics***
- *Dr S Rajasekaran, Chairman & Dept Chief, Dept of Orthopedics**

**** Ganga Hospital, Coimbatore, India***

***** GMCH, Mumbai***

Faculty Disclosure Information

- *The authors have no relevant financial or non-financial interests to disclose.*
- *The authors have no conflicts of interest to declare*

Lacunae in Literature

- *No single classification system combining types of peri-articular tibia/femur fracture with ligament injury*
  - **Limitation of existing classification system**
    - Schenck does not specify the pattern or type of peri-articular fracture
  - **Hence, essential to devise a Novel classification system for KD-V injuries.**

Aims and Objectives

Primary Aim:

- accurately classifying fracture types, thereby enhancing communication, strategizing and facilitating a comprehensive management plan.

Secondary aim:

-Functional Outcomes of Single stage and Double stage management of KD-V injuries

Material & Methods

- Retrospective Study
- IRB approval taken
- Study Period: 2019 – 2022; Ganga Hospital, Coimbatore

Inclusion Criteria	Exclusion Criteria
• All KD-V injuries with no neurological deficit • Single and double staged managed KD-V injuries • Min - 12 months follow up	• Neuro-vascular deficit • Open fracture • Unfit for surgery

Flow chart

MLKI injuries (N) = 233

Exclusion criteria

- **KD – I, II,I II, IV= 201**

Included in the study (n) = 32

Closed fracture with no neurovascular injury (n=14)

- Neurovascular injury – 5
- Open fracture – 7
- Lost to follow up – 4
- No complete data – 2

KD –knee dislocation –schenk`s classification

Material & Methods

Flow chart

Closed fracture with no neurovascular injury (n=14)

Ligament injury + periarticurar –

tibia fracture

(n=13)

Ligament injury + periarticular -

femoral fracture

(n=1)

Cruciate ligament tear/avulsion – arthroscopic Reconstruction/fixation

Collateral ligament non-operative/ repair/reconstruction Avulsion – Fixation (ORIF/ARIF)

Tibial fracture – ORIF with CC screw/Plating

Cruciate ligament tear/avulsion – arthroscopic Reconstruction/fixation

Collateral ligament non-operative/ repair/reconstruction Avulsion – Fixation (ORIF/ARIF)

Femoral fracture – Percutaneous with CC screw

A. Rim fractures – Avulsion(n-7); Compression (n=4)

B. Condylar fracture

Post op evaluation

- Clinical evaluation – IKDC and Lysholm score
- Radiological evaluation – Stress X ray

- Femoral Hoffa fracture - 1

GANGA MEDICAL CENTRE & HOSPITALS PVT LTD

ISAKOS CONGRESS 2025 | MUNICH GERMANY June 8–11

Surgical Technique

- Supine position under CSE

- arthroscopic evaluation

↓

fracture provisional fixation

↓

ligament/meniscus injury mx

↓

definitive fracture fixation

Post op protocol

- posterior support long knee brace with NWB with walker for 6 weeks
- No knee bending was allowed for the first three weeks
- Prone knee bending exercises were initiated at three weeks
- Partial weight-bearing began at six weeks and was gradually increased to full weight-bearing by eight weeks
- Weight-resisted exercises commenced three months post-surgery. The patient was advised to begin squatting, sitting cross-legged, and participating in recreational sports six months postoperatively

Statistical Analysis

- SPSS version 22
- Continuous variables - Independent t-test
- Categorical variables - Fisher's exact test or Chi-square test
- Pre and post op clinical scores - Friedman test
- The p-value of < 0.05 - significance for all statistical tests.

Data Collected for study

Clinical data

- Pre Op
  - " Xray + CT + MRI"
  - Bony indices
- Fracture classification (Rim and Condylar #)
- Ligament injury classification (Schenck)

Radiological data

- Intra –op fracture Mx
  - Conservative Mx
  - Herbert screw fixation
  - CC screw fixation
  - proximal tibia locking plates
- Post-op Stress X ray
  - At 12 Months

RESULTS (n=14)

Injured ligament and peri-articular fracture	Surgical management
• ACL, PCL, MCL, LCL and Rim compression (Multi-stage Mx)	External fixator f/b ACL + PCL reconstruction + MCL repair + Antero-medial plating
• ACL, PCL ,PLC and Rim avulsion (Single stage Mx)	ACL + PCL reconstruction + fibula TBW + Herbert screw fixation
• ACL, MCL and Condylar fracture (Single stage Mx)	ACL reconstruction + CC screw fixation
• PCL, PLC and Rim compression (Multi-stage Mx)	Anteromedial plating f/b PCL + PLC reconstruction
• ACL and Condylar fracture (Single stage Mx)	ACL reconstruction + Lateral meniscus repair + CC screw fixation
• PCL, LCL avulsion (fibular) and Rim compression • (Multi-stage Mx)	External fixator f/b PCL reconstruction + Fibula TBW + Antero-medial plating
• PCL, LCL avulsion (fibular) and Rim avulsion (Single stage Mx)	PCL reconstruction with TBW for LCL avulsion with CC screw fixation
• PCL and Rim avulsion (un-displaced) (Single stage Mx)	PCL reconstruction with Non-operative management for fracture
• ACL and Rim compression (Single stage Mx)	ACL reconstruction + CC screw fixation
• ACL, LCL and Condylar fracture (Multi-stage Mx)	CC screw fixation f/b ACL reconstruction with LCL conservative
• PCL avulsion, MCL and Femoral peri-articular fracture (Hoffa) (Single stage Mx)	ARIF for PCL avulsion + CC screw
• ACL avulsion, MCL and Rim compression (Single stage Mx)	ARIF for ACL avulsion + CC screw
• PCL and Rim avulsion (Single stage Mx)	PCL reconstruction + Herbert screw fixation
• ACL avulsion, MCL and Rim avulsion (Single stage Mx)	ARIF for ACL avulsion + CC screw

12 patients were had stable reduction with knee brace whereas 2 patients had unstable reduction and needed external fixation

RESULTS

KD-V were subclassified into FEMORAL and TIBIA peri-articular fractures.

Peri-articular Tibia fractures were further classified as Condylar and Rim fractures

Rim fractures can be avulsion or compression type

PARAMETERS				N=14
Age (years)				32.07 +/- 12.96 (range 17 - 53)
Sex (Male : Female)				11:3
Side (Right : Left)				4:3
Mode of injury				RTA – 12 patients ; Fall from height -1; Direct contact injury – 1
KD-V Subclassification	Femoral fracture			1
	Tibial fracture	Condylar fracture		2
		Rim fracture	Avulsion	7
			Compression	4

Parameters	Pre-op	3 month	6 month Post-op	Final follow up	p value
Lysholm score	40.5+/- 6.34	65.5 +/- 2.21	74.17 +/- 1.86	84.33 +/- 33	p<0.05
IKDC score	30.33 +/- 4.5	55 +/- 4.04	65.17 +/- 6.9	71.5 +/- 4.6	p<0.05

All patients had significant improvement post op clinical scores

Parameters	Mean radiological measurements (mm)
Mean anterior translation	3.13 +/- 1.44
Mean posterior translation	1.63 +/- 0.47
Mean valgus opening	3.4 +/- 1.94 - conservative Mx group 2.49+/-1.14 – operated group
Mean varus opening	5.73 +/- 2.16 - conservative Mx group 6.6+/-1.94 - operated group

Discussion

- In our case series of 14 patients, we employed single-stage management with concomitant fracture fixation for 12 patients and double stage management for 2 patient, utilizing the novel classification system to guide the staged management and fixation method.
- Single-stage management offers several advantages, including reduced hospitalization, alleviation of apprehension regarding additional surgeries, direct visualization of articular reduction, and simultaneous management of intra-articular injuries
- The single stage outcomes have been associated with better functional outcomes but has high risk of arthrofibrosis

Complications

- 4 patients of single stage management developed stiffness, which was addressed at six weeks with manipulation under anesthesia, resulting in full knee motion recovery.
- Postoperative stiffness may arise from extensive soft tissue injury, leading to a robust inflammatory response and subsequent arthrofibrosis
- We recommend prompt intervention upon the onset of stiffness, supplemented by rigorous physiotherapy and continuous passive motion exercises to mitigate chronic pain development.

Kanakamedala etal Vs Our Study

Archives of Orthopaedic and Trauma Surgery
https://doi.org/10.1007/s00402-020-03344-3

ORTHOPAEDIC SURGERY

Check for updates

Concomitant periarticular fractures predict worse patient-reported outcomes in multiligament knee injuries: a matched cohort study

Ajay C. Kanakamedala[2] · Andrew J. Sheean[1] · Michael J. Alaia[2] · James J. Irrgang[1] · Volker Musahl[1]

No fracture classification was done

OUR STUDY

N = 14

1 undisplaced # - conservative

13 displaced fractures classified and operated

N=6

Fracture morphology :

4 undisplaced # - conservative Mx

2 displaced # - operated

Cinque etal Vs Our Study

Do Tibial Plateau Fractures Worsen Outcomes of Knee Ligament Injuries?

A Matched Cohort Analysis

Mark E. Cinque,* MS, Jonathan A. Godin,*† MD, MBA, Gilbert Moatshe,*‡ MD, Jorge Chahla,* MD, PhD, Bradley M. Kruckeberg,* BA, Jonas Pogorzelski,* MD, MHBA, and Robert F. LaPrade,*†§ MD, PhD

Rim avulsion fractures are not included in classification

N = 8
Fracture morphology classified with Schatzker

OUR STUDY
N = 14
Peri-articular femoral # - 1
Peri-articular tibial condylar # - 2
Peri-articular tibial rim avulsion # - 7
Peri-articular tibial rim compression # - 4

CONCLUSION

- Single-stage management of MLKI-KD-V injuries yields satisfactory outcomes and facilitates an early return to pre-injury activity levels at follow up of 2 years.
- Despite the high prevalence of MLKI-KD-V, the literature lacks a comprehensive classification system that incorporates the various patterns of peri-articular fractures.
- Our study supports comprehensive management of all MLKI-KD-V injuries based on a novel, easy-to-use and reproducible classification system.

NOVEL CLASSIFICATION

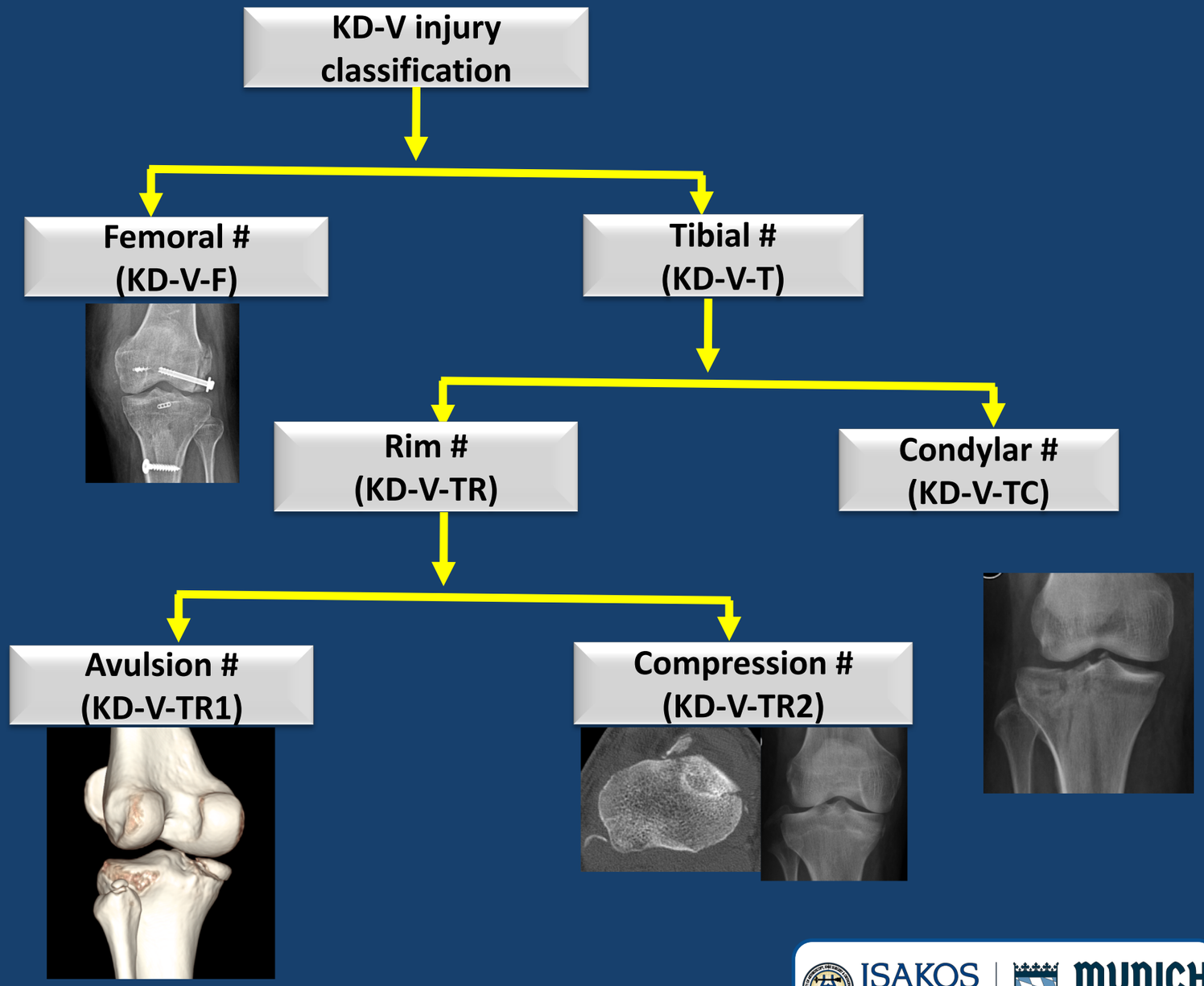

GANGA MEDICAL CENTRE & HOSPITALS PVT LTD
ISAKOS CONGRESS 2025
MUNICH GERMANY June 8–11

References:

- Fanelli GC, Edson CJ. Arthroscopically assisted combined anterior and posterior cruciate ligament reconstruction in the multiple ligament injured knee: 2- to 10-year follow-up. Arthroscopy. 2002 Sep;18(7):703–14.
- Kanakamedala AC, Sheean AJ, Alaia MJ, Irrgang JJ, Musahl V. Concomitant periarticular fractures predict worse patient-reported outcomes in multiligament knee injuries: a matched cohort study. Arch Orthop Trauma Surg. 2020 Nov;140(11):1633–9.
- Robertson A, Nutton RW, Keating JF. Dislocation of the knee. The Journal of Bone and Joint Surgery British volume. 2006 Jun;88-B(6):706–11.
- Cinque ME, Godin JA, Moatshe G, Chahla J, Kruckeberg BM, Pogorzelski J, et al. Do Tibial Plateau Fractures Worsen Outcomes of Knee Ligament Injuries? A Matched Cohort Analysis. Orthopaedic Journal of Sports Medicine. 2017 Aug 1;5(8):232596711772389.
-
- Stannard J. Fracture Dislocation of the Knee. J Knee Surg. 2016 Apr 18;29(04):300–2.
- Moore TM. Fracture--dislocation of the knee. Clin Orthop Relat Res. 1981 May;(156):128–40.
- Wascher DC. High-velocity knee dislocation with vascular injury. Treatment principles. Clin Sports Med. 2000 Jul;19(3):457–77.
- Fanelli GC, Stannard JP, Stuart MJ, Macdonald PB, Marx RG, Whelan DB, et al. Management of complex knee ligament injuries. Instr Course Lect. 2011;60:523–35.
- Sabesan VJ. Multiligament knee injuries with associated tibial plateau fractures: A report of two cases. WJO. 2015;6(3):363.
- Barrow AE, Sheean AJ, Burns TC. Return to duty following combat-related multi-ligamentous knee injury. Injury. 2017 Apr;48(4):861–5.
- Sundararajan SR, Dsouza T, Ramakanth R, Rajasekaran S. Single-Stage Arthroscopy-Assisted Reduction and Internal Fixation (ARIF) of Tibial Rim Fracture With Posterior Cruciate Ligament Reconstruction and Repair of Posterolateral Complex and Meniscal Injury. Arthroscopy Techniques. 2021 Nov;10(11):e2531–40.
- Wu J, Wang Y, Zhou F, Yang L, Tang J. Trans-articular Kirschner wire fixation in treating complex tibial plateau fractures complicated by multiple ligaments injuries: A case report and literature review. Injury. 2018 Feb;49(2):382–5.
- Azar FM, Brandt JC, Miller RH, Phillips BB. Ultra-low-velocity knee dislocations. Am J Sports Med. 2011 Oct;39(10):2170–4.