ISAKOS CONGRESS 2025 | MUNICH GERMANY June 8–11

Arthroscopic humeral head defect filling with Osteochondral Autografts Transplantation for near-track Hill Sachs lesions

A. Bergomi, F. De Filippo, G. Vittone,
M.F. Saccomanno, D. Turriciano, G. Milano

Department of Medical and Surgical Specialties, Radiological Sciences, and Public Health, University of Brescia, Brescia, Italy

Faculty Disclosure Information

- Nothing to disclose

Background

- **Near-track lesions** recently showed an increased **risk of failure** and recurrence after Bankart repair [1,2].

- Although several techniques have been described to address subcritical glenoid bone loss, the **management of the Hill-Sachs lesions** remains a challenge [3,4,5,6].

Purpose

- To present an arthroscopic technique to fill the articular portion of the Hill-Sachs lesion with **osteochondral autografts** harvested from the ipsilateral knee.

- To evaluate the functional outcomes in a series of cases managed with this technique.

Methods

- **Study design:** Retrospective study
- **Period:** 12/2022 – 09/2024

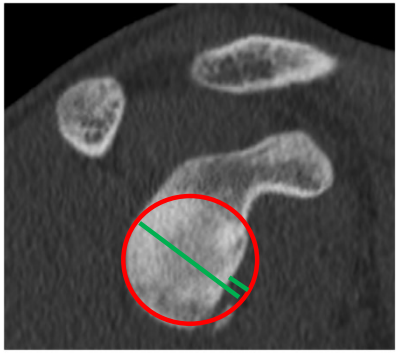

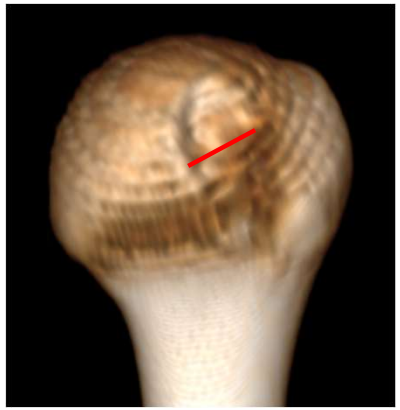

ISAKOS CONGRESS 2025 | MUNICH GERMANY June 8–11

Inclusion criteria:

- Primary or recurrent anterior glenohumeral instability
- Evidence of near-track lesion on CT scan
- 1 year follow up

Exclusion criteria:

- On-track and Off-track lesions
- Glenohumeral or AC joint Osteoarthritis
- Previous local or systemic shoulder conditions

Surgical Technique

- Lateral decubitus, a diagnostic arthroscopy is first performed, and the Hill-Sachs lesion is assessed.

- Mini-arthrotomy on the ipsilateral knee to expose the donor site: the harvester is positioned perpendicular to the proximal lateral aspect of the femoral trochlea and impacted to a depth of approximately 15 mm.

Surgical Technique

- Arthroscopic view through anterior-superior portal: through the cannula placed in the posterior portal the harvester is positioned to create the bone socket into the Hill-Sachs lesion and impacted to a depth of 10-13 mm.

- A graduated alignment rod is used to measure the final recipient socket depth and check the correct insertion angle.

Surgical Technique

- The graft taken from the knee is inserted and press-fitted perpendicularly into the recipient socket.

- Multiple plugs (2-3) may be needed to fill the defect.

- A standard capsulolabral repair or reconstruction is performed subsequently based on the injury pattern of soft tissues.

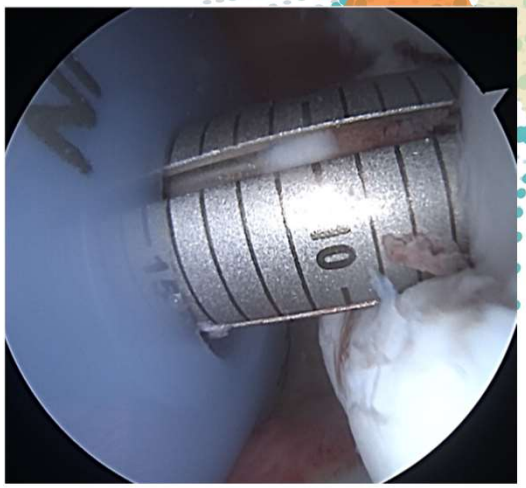

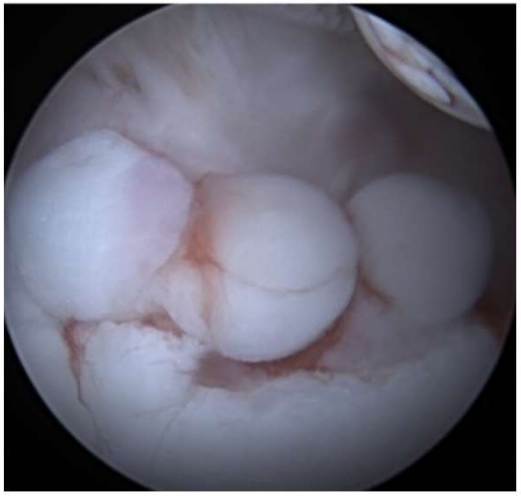

Outcomes

- ✓ **Recurrence of dislocation**
- ✓ American Shoulder and Elbow Surgeons (ASES) score
- ✓ WOSI (Western Ontario Shoulder Instability) score

- Wilcoxon signed-rank test was used to compare patient-reported outcomes (PROMs) at baseline and at follow-up

Results

Patient demographics

Parameter	Value
N° of patients	6 (5M, 1F)
Mean age (years)	26.3 ± 3.9
Mean F-U (months)	16.3 ± 3.1

Functional outcomes

Outcome	Baseline (mean)	F-U (mean)	p
ASES score	76.7 ± 15.4	95.8 ± 7.8	0.027
WOSI score	43.8 ± 10.6	7.7 ± 4.6	0.028

- **No cases of dislocation recurrence**
- **No cases showed persistent apprehension**
- No symptoms related to the harvest site

Conclusion

To date, recurrent gleno-humeral instability matched with subcritical bone loss, still represent a hard challenge.

The **arthroscopic humeral head filling with osteochondral autograft transplantation** for near-track Hill-Sachs lesions is a viable **anatomical option** that may improve clinical outcomes in patients with primary or recurrent glenohumeral instability.

References

1. **Li RT, Kane G, Drummond M, Golan E, Wilson K, Lesniak BP, et al.** On-track lesions with a small distance to dislocation are associated with failure after arthroscopic anterior shoulder stabilization. J Bone Joint Surg Am 2021;103:961-7. doi.org/10.2106/JBJS.20.00917.

2. **Yang T-C, Chen K-H, Chiang E-R, Chang M-C, Ma H-L.** Using the “Hill-Sachs interval to glenoid track width ratio” for prediction of recurrent instability after arthroscopic Bankart repair. Orthop Traumatol Surg Res 2018;104:797-801. doi.org/10.1016/j.otsr.2018.02.013.

3. **Brzoska R, Laprus H, Michniowski P, Solecki W, Klon W, Błasiak A.** Novel and effective arthroscopic extracapsular stabilization technique for anterior shoulder instability-BLS. Knee Surg Sports Traumatol Arthrosc 2019;27:3897-904. doi.org/10.1007/s00167-019-05496-1.

4. **Maiotti M, Massoni C, Russo R, Schroter S, Zanini A, Bianchedi D.** Arthroscopic subscapularis augmentation of Bankart repair in chronic anterior shoulder instability with bone loss less than 25% and capsular deficiency: clinical multicenter study. Arthroscopy 2017;33:902-9. doi.org/10.1016/j.arthro.2016.09.008.

5. **Moroder P, Bohm E, Scheibel M.** The arthroscopic bankart-plus procedure for treatment of anterior shoulder instability with small to intermediate glenoid defects. Arthrosc Tech 2018;7:e379-84. doi.org/10.1016/j.eats.2017.10.009.

6. **Nair AV, Mohan PK, Jangale A, Kuntwad V, Kumar MP, Goud N, et al**. Dynamic anterior stabilization using transosseous bone tunnel technique with the adjustable loop length cortical button incorporating high-strength suture augmentation for recurrent shoulder instability. Arthrosc Tech 2022;11:e1929-35. doi.org/10.1016/j.eats.2022.07.007.