The utility of stress ultrasound in the assessment of ACL insufficiency

Miho J. Tanaka MD, PhD
Nikitha Crasta, MD
Maria V. Velasquez Hammerle, MD
Kyle Grover, BS

HARVARD MEDICAL SCHOOL

MASSACHUSETTS GENERAL HOSPITAL
ORTHOPAEDICS

Disclosures

Tanaka

- Consultant for Arthrex
- Consultant for DePuy/Mitek
- Consultant for VeryWell Health
- Consultant for Healthy Sleep
- CMO, Core2U
- Research funding from AANA
- Research funding from FujiFilm
- Research funding from Voice in Sport Foundation
- NIH R21EB031185
- NIH 1R01AR079442
- NIH 1R01AR081344

Background

- The ultrasound (US)-assisted Lachman test has been described in a recent cadaveric study to detect anterior cruciate ligament (ACL) insufficiency with high accuracy
- During this test, the anterior translation of the tibia relative to the femur can be quantified.

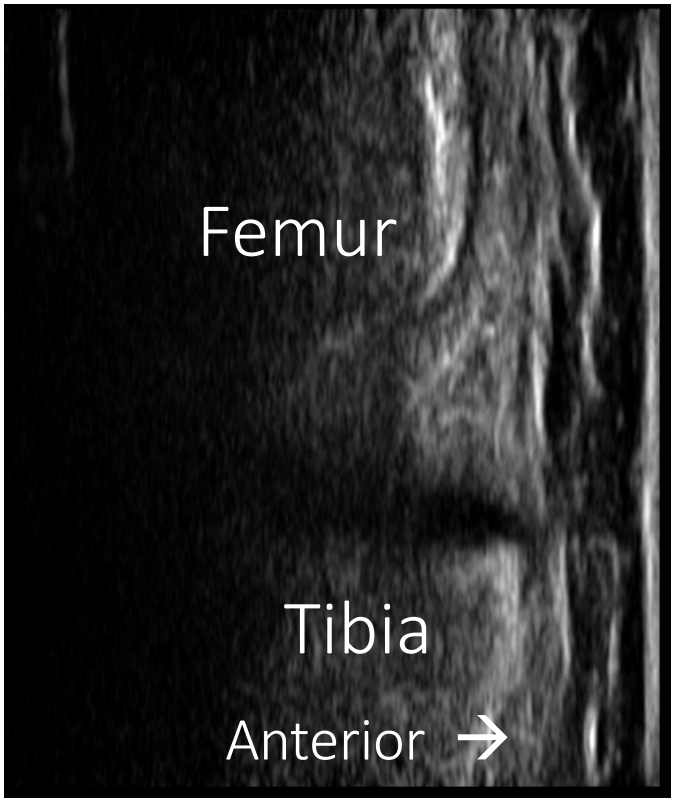

Objective

- Given its utility in a cadaveric setting, the purpose of this study was to identify the role of stress ultrasound in identifying ACL insufficiency in a clinical population.

Methods

- In patients with unilateral ACL injury, stress ultrasound was performed using the TELOS device
- The knee at positioned at 20 degrees of knee flexion, and US measurements were performed over the anteromedial knee
- Using the TELOS device, US measurements were obtained in both the unloaded state and with 90N of anteriorizing load on the tibia



Telos Medical USA

Methods

- US guided measurements were compared between the following conditions:
  - Noninjured knee
  - ACL deficient knee
  - 6 months after ACL reconstruction
- Receiver operating characteristic (ROC) curve analysis was performed to evaluate the ability of ultrasound measurements to identify ACL insufficiency

Results

- 64 patients were included in this study (19M, 45F)
- Mean age 27.9+/-7.8 years
- No significant difference was noted between the unloaded states (p=0.596):
  - Normal: 0.1+/-2.3mm
  - Injured: 0.3+/-2.6mm
  - Postoperative knees: 0.6+/-1.8mm

Results

- In the loaded state (90N), anterior translation of the tibia in the ACL deficient state (1.8+/-2.6mm) was greater than the following:
  - Normal state (0.8+/-1.9mm, p=0.107)
  - Postoperative state (0.4+/-2.0mm, p=0.020)

- No difference was noted between the uninjured and postoperative states

Results

- Using a cutoff of >2mm in the loaded state, ROC curve demonstrated an area under the curve of 0.70.

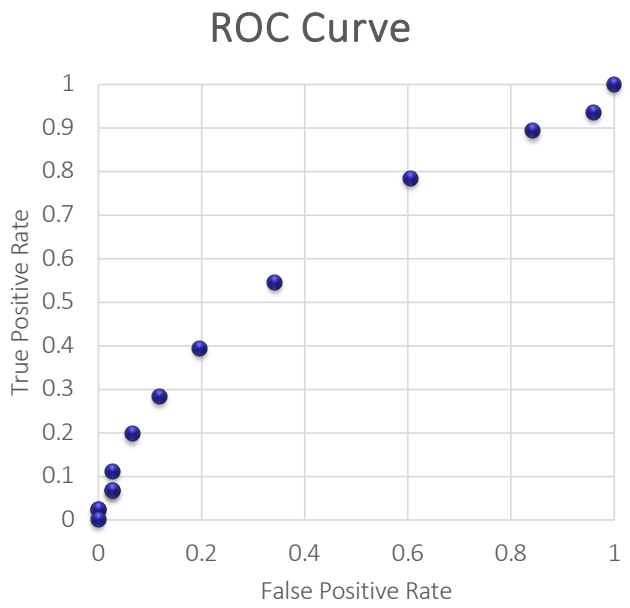

Conclusions

- Using the TELOS stress testing device, we found that stress ultrasound detected significantly greater anterior translation in the ACL-deficient state when compared to the normal knee and that this corrected to normal after ACL reconstruction.

Conclusions

- A measurement >2mm loaded at 90N identified ACL deficiency with moderate accuracy
- Further studies are needed to assess the utility of stress ultrasound for the evaluation of ACL injuries and reconstruction

References

- Boden BP, Sheehan FT, Torg JS, Hewett TE. Noncontact anterior cruciate ligament injuries: mechanisms and risk factors. J Am Acad Orthop Surg. 2010 Sep;18(9):520-7. doi: 10.5435/00124635-201009000-00003. PMID: 20810933; PMCID: PMC3625971.
- Sievert ZA, Bennett HJ, Weinhandl JT. Intra- and inter-rater reliability of ultrasound measures of the anterior cruciate ligament. J Ultrasound. 2021 Mar;24(1):49-55. doi: 10.1007/s40477-020-00450-1. Epub 2020 Mar 18. PMID: 32185703; PMCID: PMC7925765.
- Lee SH, Yun SJ. Efficiency of knee ultrasound for diagnosing anterior cruciate ligament and posterior cruciate ligament injuries: a systematic review and meta-analysis. Skeletal Radiol. 2019 Oct;48(10):1599-1610. doi: 10.1007/s00256-019-03225-w. Epub 2019 May 10. PMID: 31076833.
- Griffith JF, Ng AWH. Top-Ten Tips for Imaging the ACL. Semin Musculoskelet Radiol. 2019 Aug;23(4):444-452. doi: 10.1055/s-0039-1693489. Epub 2019 Sep 11. PMID: 31509871.
- Wu WT, Lee TM, Mezian K, Naňka O, Chang KV, Özçakar L. Ultrasound Imaging of the Anterior Cruciate Ligament: A Pictorial Essay and Narrative Review. Ultrasound Med Biol. 2022 Mar;48(3):377-396. doi: 10.1016/j.ultrasmedbio.2021.11.004. Epub 2021 Dec 21. PMID: 34949491.

Thank you

HARVARD
MEDICAL SCHOOL

MGH 1811
MASSACHUSETTS
GENERAL HOSPITAL
ORTHOPAEDICS