ISAKOS CONGRESS 2025 | MUNICH GERMANY June 8–11

PATELLAR TILT ANGLE: DOES IT TRULY REFLECT PATELLAR INCLINATION?

MANILOV, RICARDO MD.; VRANCOVICH, ESTEFANIA MD; PARTEZANI HELITO, CAMILO MD PHD; BORBORE ADRIAN MD, MALDONADO, SEBASTIAN MD., BRUNO MARTIN MD.

CLINICA MERCEDARIO

SAN JUAN, ARGENTINA

Faculty Disclosure Information

- NOTHING TO DISCLOSURE

BACKGROUND

- The patellar tilt angle (PTA) is determined by the intersection of the patellar transversal major axis and the posterior femoral line, making its value reliant on the tilt of both components.
- The posterior femoral line serves as a reference point for measuring internal knee torsion (Manilov et al.).
- When the pathological PTA is under 10° after accounting for internal knee torsion (KITA), it is considered a false positive.
- Identifying false positive PTAs is crucial, as a pathological PTA typically leads to lateral retinacular lengthening; conversely, if it results from a torsional disorder, the patient might require a derotational osteotomy at the site of the deformity.
- There is currently a lack of literature investigating which of these two factors most significantly impacts PTA values or the occurrence of false positives arising from internal knee torsion.

HYPOTHESIS:

The torsional factor has a more pronounced impact on the posterior tibial angle (PTA) compared to the actual patellar tilt when measurements are based on the posterior femoral line as a reference.

OBJECTIVE:

1° Assess the preponderance between knee internal torsion and true patellar tilt in PTA value.

2° Analyze the frequency of “false positive PTA” results attributed to knee internal torsion (KITA).

MATERIAL AND METHODS

- Retrospective analysis of complete torsional lower limb ct scans conducted between 2017 and 2024.
- A total of 934 knees from 467 patients: 96 males (20.56%) and 371 females (79.44%).
- Inclusion criteria: experiencing pain and/or instability, no previous surgical history, pathological PTA (greater than 10°).
- We derived the following equation: **PTA-KITA = PPTA**(Pure Patellar Tilt Angle). A PPTA exceeding 50% of PTA indicates patellar preponderance, while a PPTA below 50% of PTA suggests KITA preponderance.
- If PPTA ≤ 10°, the PTA was categorized as a false positive.

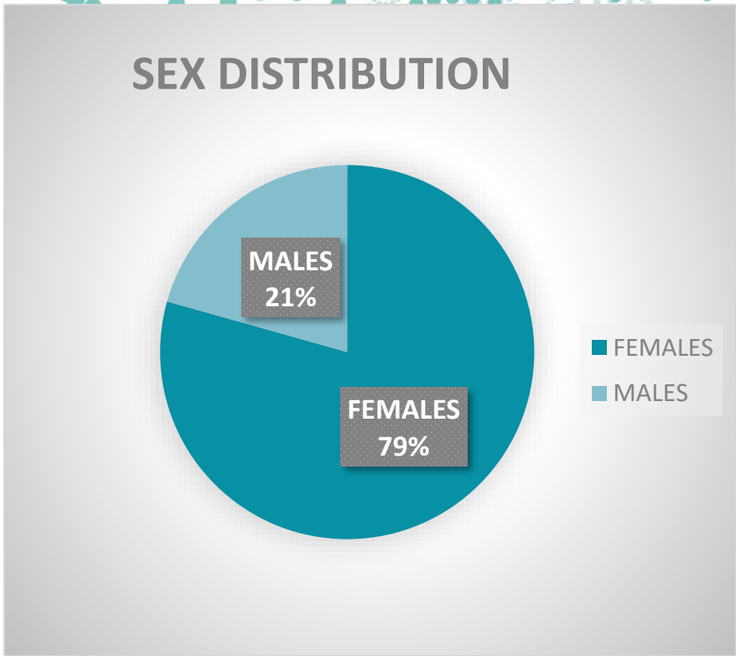

FUNCTIONAL INTEGRAL CT PROTOCOL

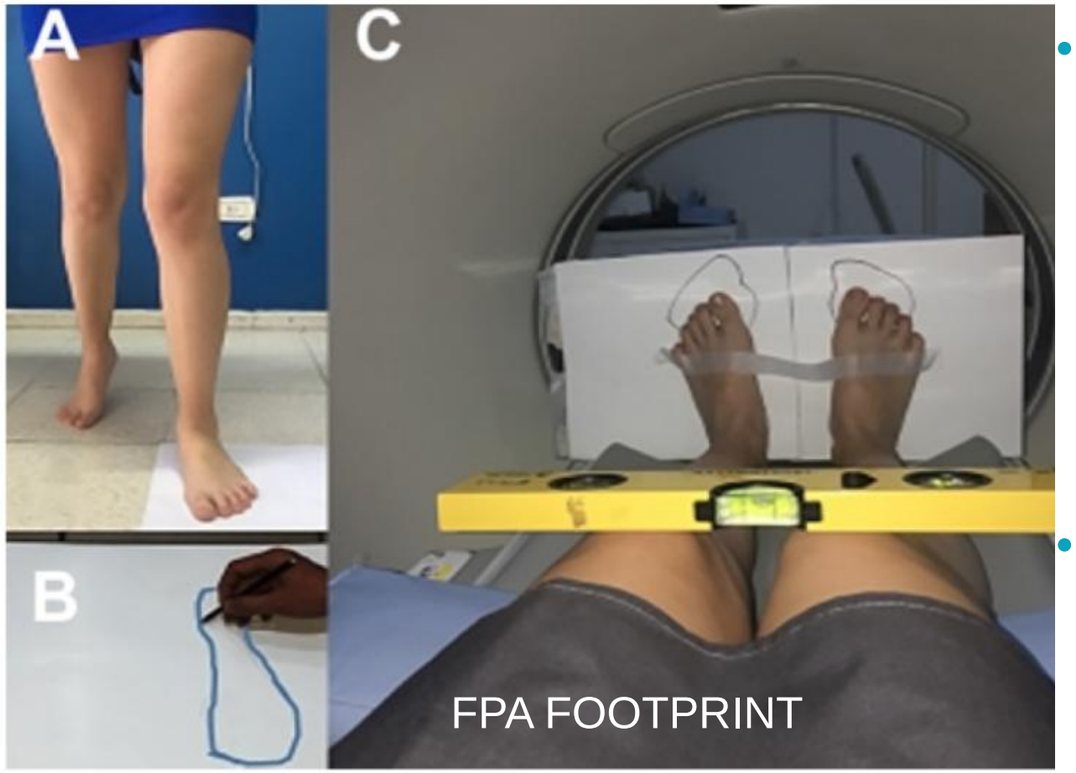

- The patient should be positioned in alignment with their own foot progression angle footprint, effectively simulating their walking position (functional).
- Ensure a comprehensive analysis of the lower limb is included, which should encompass the knee internal torsion angle (KITA).

“PATHOLOGICAL PTA >10° DOES NOT ALWAYS INDICATE A TRUE PATELLAR TILT”

AUTHENTIC PATELLAR INCLINATION

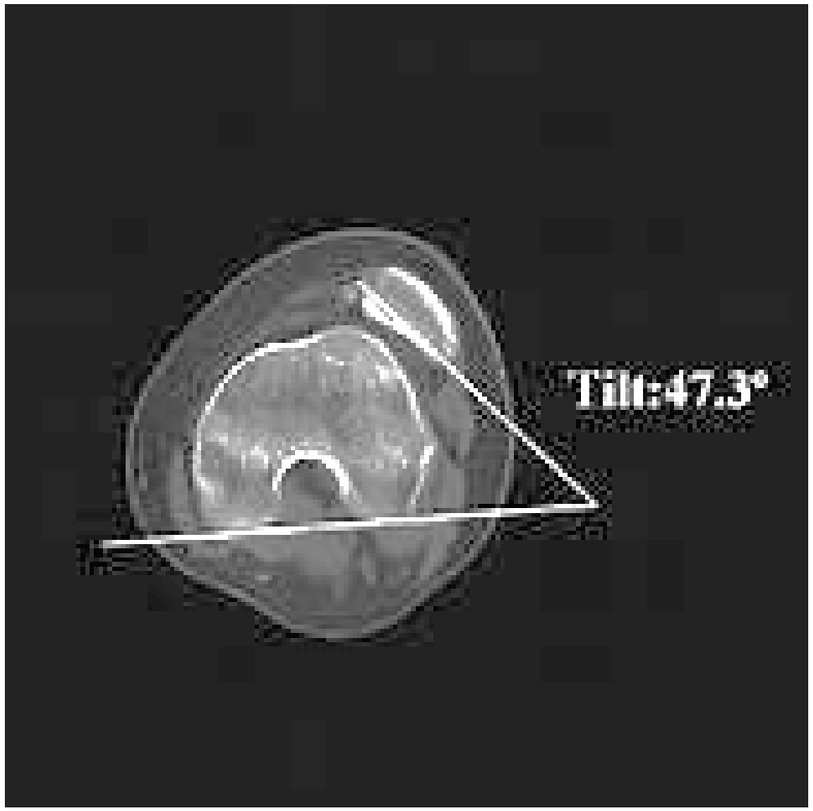

FALSE POSITIVE PTA: ABSENCE OF PATELLAR INCLINATION

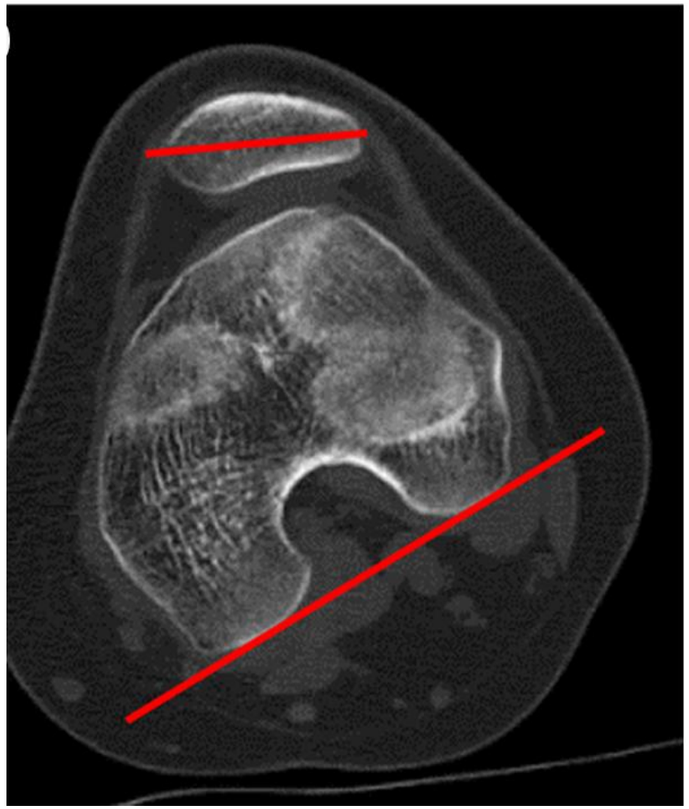

“IT IS CRUCIAL TO DISTINGUISH FALSE POSITIVES AS THEY HAVE A DIFFERENT ETIOLOGY AND, CONSEQUENTLY, REQUIRE A DIFFERENT TREATMENT.”

KNEE INTERNAL TORSION ANGLE (KITA):

This angle is determined by the intersection of a horizontal line that is parallel to the floor and the posterior bicondylar line of the femur.

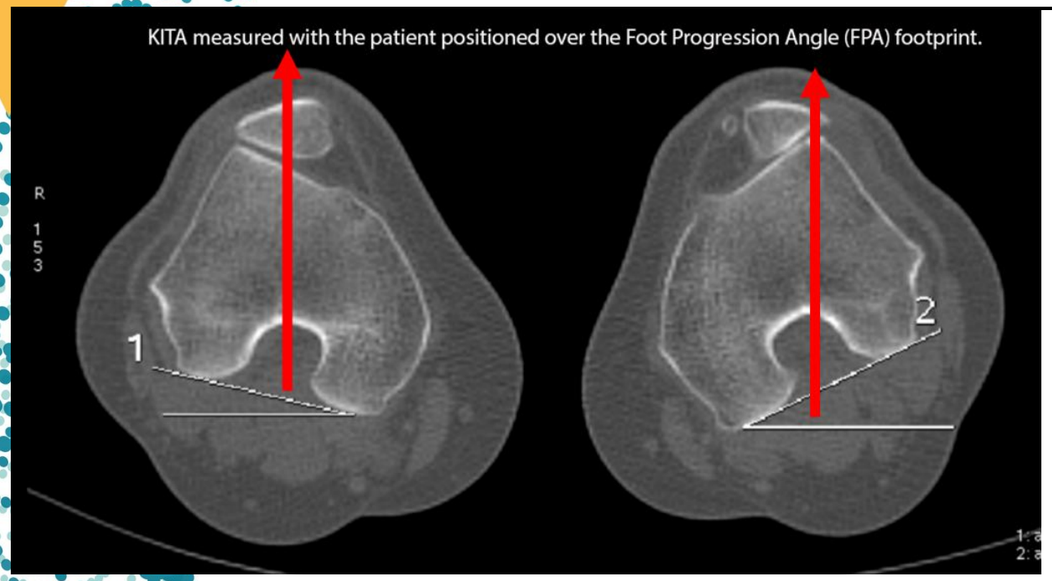

REDUCED ARTICULAR SURFACE AREA IN HIGH KITA

KITA ARISES FROM THE INTERPLAY OF FEMORAL ANTEVERSION, EXTERNAL TIBIAL TORSION, AND THE FOOT PROGRESSION ANGLE (FPA) WHEN A PATIENT IS PLACED ON THEIR OWN FPA FOOTPRINT.

ISAKOS CONGRESS 2025
MUNICH GERMANY
June 8–11

PURE PATELAR TILT ANGLE (PPTA): Obtained by subtracting kita from pta.

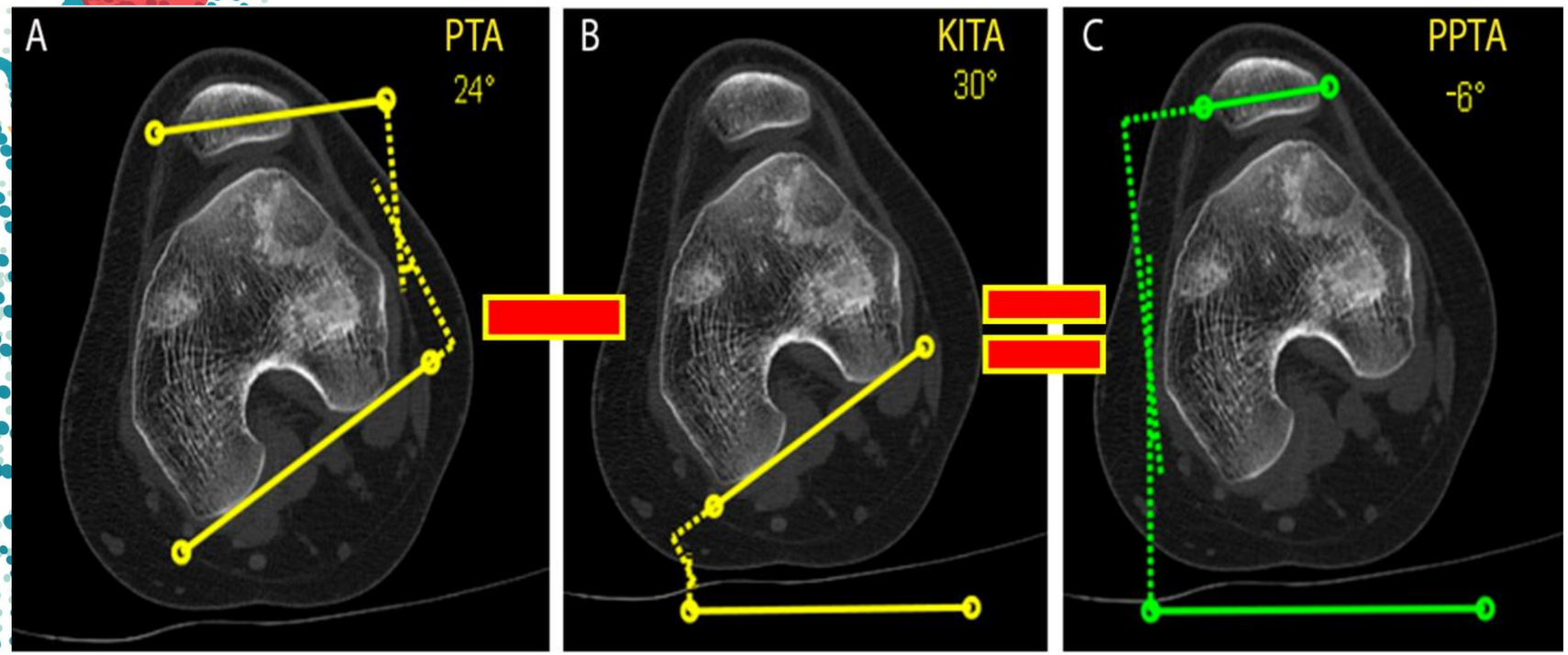

IF PPTA IS BELOW 10° = FALSE POSITIVE PTA

IF PPTA EXCEEDS 50% OF PTA = PATELLAR TILT PREPONDERANCE.

IF PPTA IS LESS THAN 50% OF PTA = KITA PREPONDERANCE.

RESULTS:

(ANALISYS SOFTWARE GRAPHPAD PRISM 10 (USA):
INTRACLASS CORRELATION COEFICIENT: INTRAOBSERVER AND INTEROBSERVER.
TWO WAY ANOVA. TURKEYS´S POST-HOC TEST , CHI SQUARE TEST)

A Incidence of False Positive Patellar Tilt Angle Due to Knee Internal Torsion

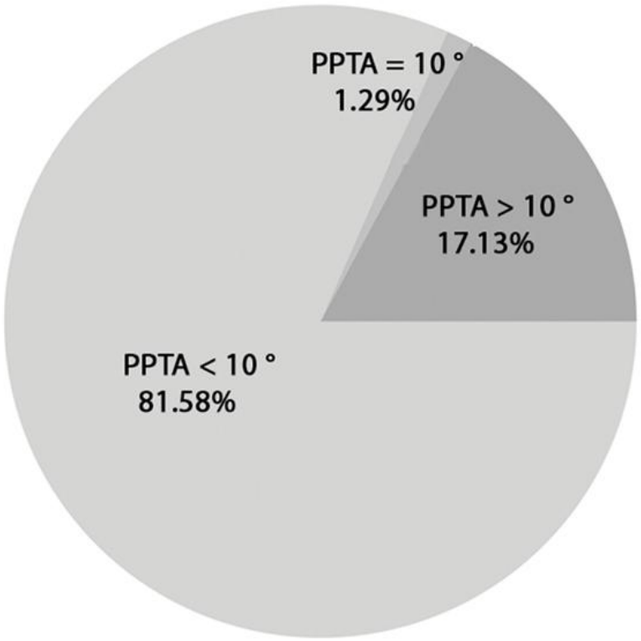

81,58% FALSE POSITIVE PTA

Preponderance of Knee Internal Torsion Influeting Patellar Tilt Angle

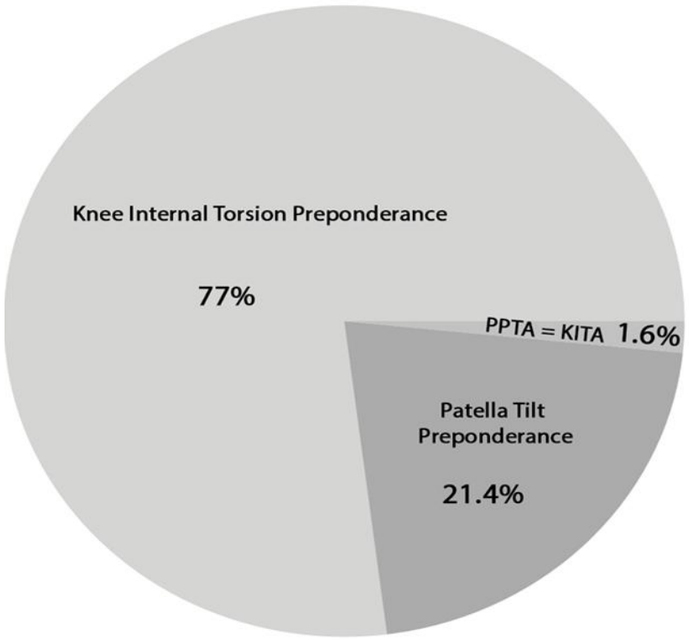

77% OF KITA PREDOMINANCE COMPARED TO 21.4% TRUE PATELLAR TILT

ISAKOS CONGRESS 2025
MUNICH GERMANY
June 8–11

DISCUSSION

- This study shows that knee internal torsion has a significant impact on PTA.
- The PPTA measurement technique, which utilizes the patellar cross-sectional axis alongside a horizontal reference line, provides a more direct assessment of actual patellar tilt without the distortion caused by torsional factors.
- Accurately distinguishing between genuine patellar tilt and torsional influences is crucial for effective diagnosis and surgical planning.
- The “menu a la carte” algorithm suggests lateral retinacular lengthening when pta increases; however, this study demonstrates that in most instances, PTA is a result of KITA and does not represent a true pathological patellar tilt. Therefore, derotational osteotomy should be considered for cases of false positive pta.

CONCLUSION

- The hypothesis was confirmed, as using the femoral bicondylar line as a reference during PTA assessment conceals a torsional component and provides deeper insights into knee torsion beyond just patellar tilt.
- The rate of false positive PTA results was unexpectedly high once kita was excluded, indicating a lack of actual patellar tilt.
- We noted a marked increase of KITA in comparison to patellar tilt in the pta measurements.
- Future studies are necessary to determine a pathological threshold value for PPTA, which seems to remain unaffected by the underlying torsional element, as it relates the patellar axis to a horizontal line that is parallel to the ground.

REFERENCES

1. Dejour H, Walch G, Nove-Josserand L, Guier C. Factors of patellar instability: an anatomic radiographic study. Knee Surg Sports Traumatol Arthrosc. 1994;2(1):19-26. doi: 10.1007/BF01552649. PMID: 7584171.
2. Dejour DH, Mesnard G, Giovannetti de Sanctis E. Updated treatment guidelines for patellar instability: "un menu à la carte". J Exp Orthop. 2021 Nov 26;8(1):109. doi: 10.1186/s40634-021-00430-2. PMID: 34837157; PMCID: PMC8626553.
3. Ficat P. Le syndrome d'hyperpression externe de la rotule [The syndrome of lateral hyperpressure of the patella]. Acta Orthop Belg. 1978 Jan-Feb;44(1):65-76. French. PMID: 665195.
4. Grelsamer, R. P., Weinstein, C. H., Gould, J., & Dubey, A. (2008). Patellar tilt: The physical examination correlates with MR imaging. *Knee*, *15*(1), 3-8. https://doi.org/10.1016/j.knee.2007.08.010
5. Kang H, Dong C, Tian G, Wang F. A Computed Tomography Study of the Association Between Increased Patellar Tilt Angle and Femoral Anteversion in 30 Patients with Recurrent Patellar Dislocation. Med Sci Monit. 2019 Jun 12;25:4370-4376. doi: 10.12659/MSM.914747. PMID: 31186399; PMCID: PMC6585535.
6. Manilov, Ricardo, Sebastián Maldonado, Oscar Orellano, Adrián Borbore, Manuel Manilov: Torsión interna de rodilla. Protocolo tomográfico patelofemoral en posición de marcha. ARTROSCOPIA | VOL. 28, N° 2 181-191 | 2021.
7. Manilov R, Chahla J, Maldonado S, Altintas B, Manilov M, Zampogna B. High tibial derotation osteotomy for distal extensor mechanism alignment in patients with squinting patella due to increased external tibial torsion. Knee. 2020 Dec;27(6):1931-1941. doi: 10.1016/j.knee.2020.10.006. Epub 2020 Nov 19. PMID: 33221691.
8. Teitge RA. Patellofemoral syndrome a paradigm for current surgical strategies. Orthop Clin North Am. 2008 Jul;39(3):287-311, v. doi: 10.1016/j.ocl.2008.04.002. PMID: 18602559.