ISAKOS CONGRESS 2025 | MUNICH GERMANY June 8–11

Extended Use of Arthrex® Dog Bone™ Button for Acromioclavicular Joint Stabilization in the Presence of Coracoid Fracture: A Case Report

1. Prof. Dr. med. Frank. Martetschläger, Deutsches Schulterzentrum, Munich, Germany

2. Naman Wahal, MBBS, MS Orthopaedics, Indraprastha Apollo, New Delhi, India

3. Dr. Abdullah Alabbasi, MBBS, FACHARZT, EBOT, BÄSMM Shoulder, Elbow & Sport Orthopedic Consultant, Jeddah, Saudi Arabia

Faculty Disclosure Information

- Nothing to disclose

Background

- AC joint dislocations + coracoid fractures = "Double Disruption" of SSSC
- Hook plates traditionally used but carry risk of osteolysis, pain, and reoperation
- Arthroscopic Dog Bone Button is minimally invasive but not typically used for coracoid fractures
- This case explores off-label use with excellent outcomes

Case Presentation

- 44-year-old femaleMountain biking accident
- 3 days post-trauma: pain, swelling, visible deformity
- Physical exam: intact skin, tender AC joint, no neurovascular deficit
- Imaging: Rockwood Type V AC dislocation + Ogawa Type I coracoid fracture

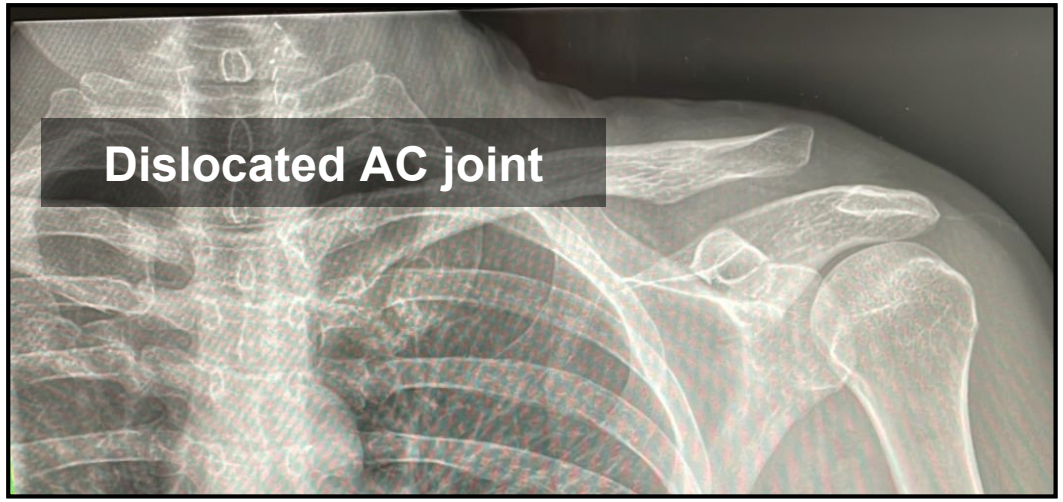

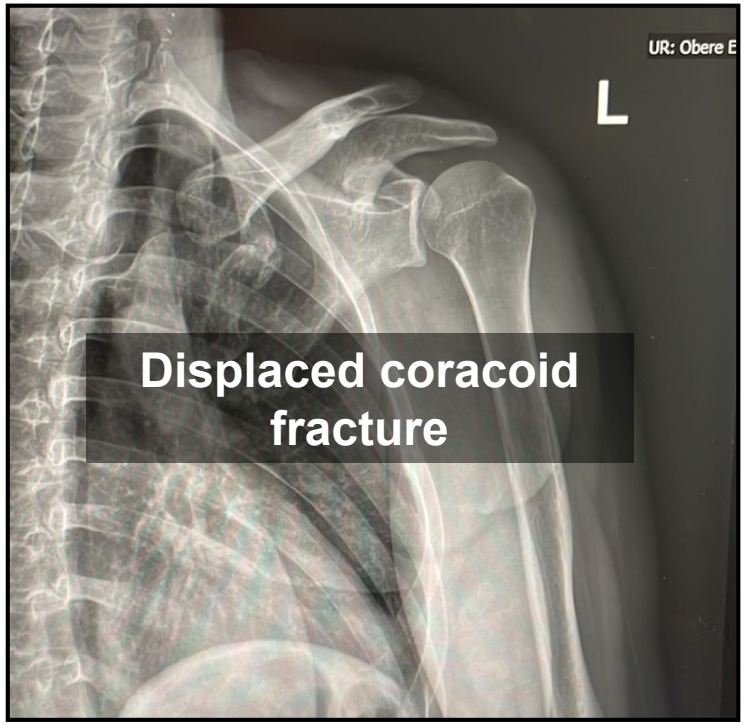

Case Presentation

- Management: **Arthroscopically-assisted AC joint fixation**
- Device**: Arthrex® Dog Bone™ Button**
- Coracoid not directly fixed — fracture managed conservatively
- Hook plate avoided due to complication risk
- AC joint stabilization led to indirect reduction of coracoid

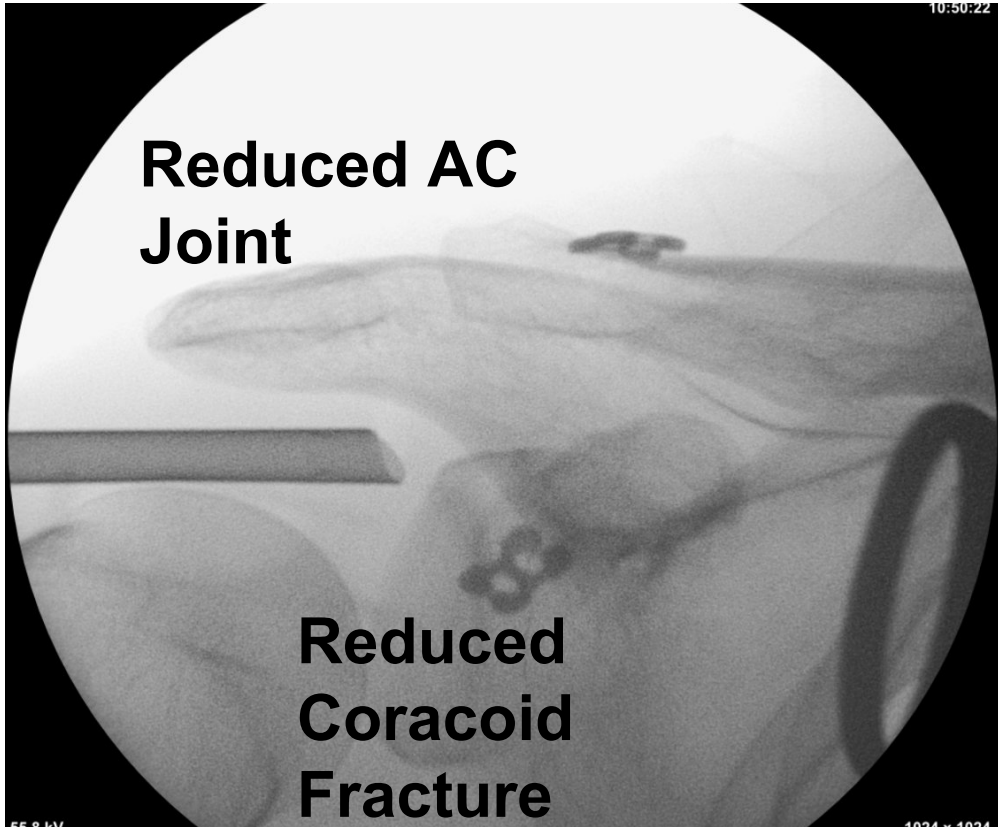

Coracoid Preparation

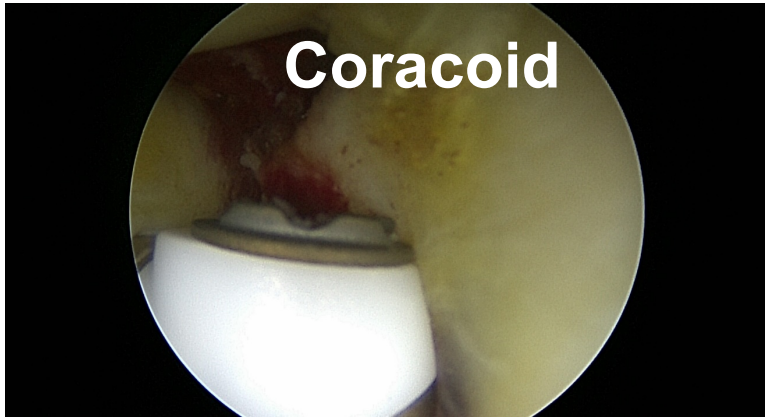

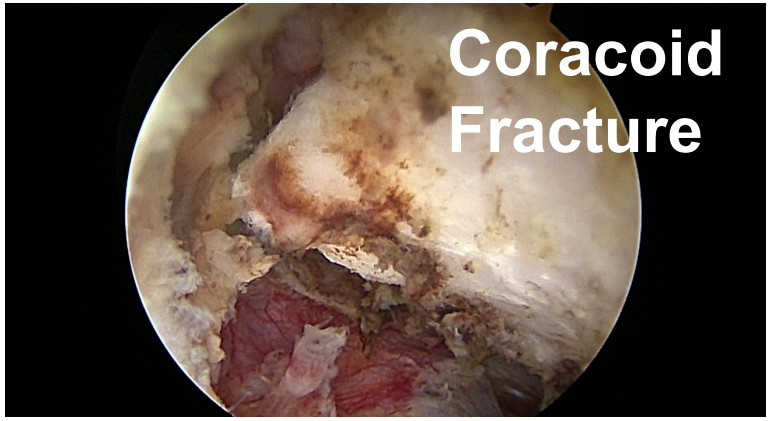

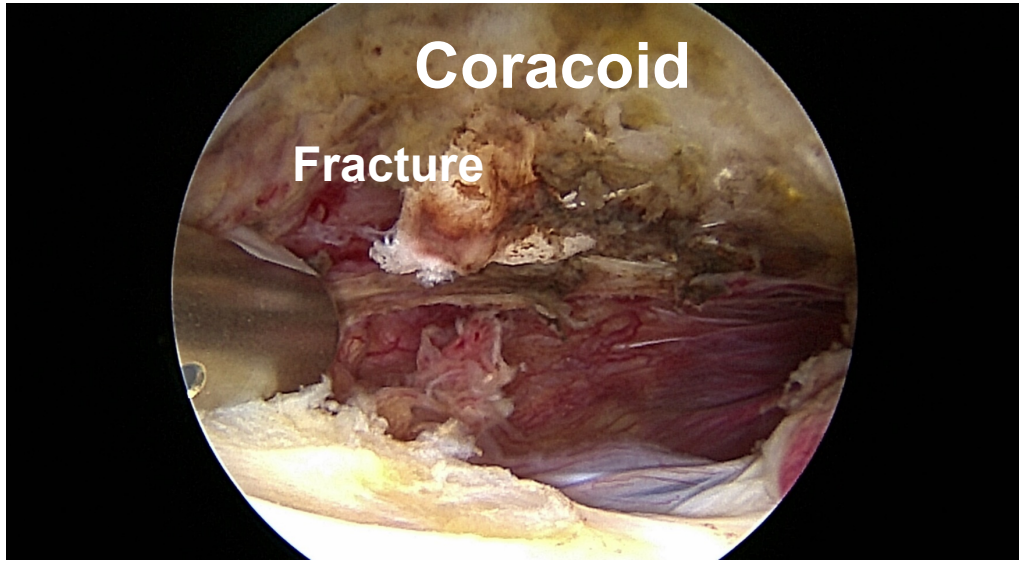

Careful placement of Dog-Bone Button

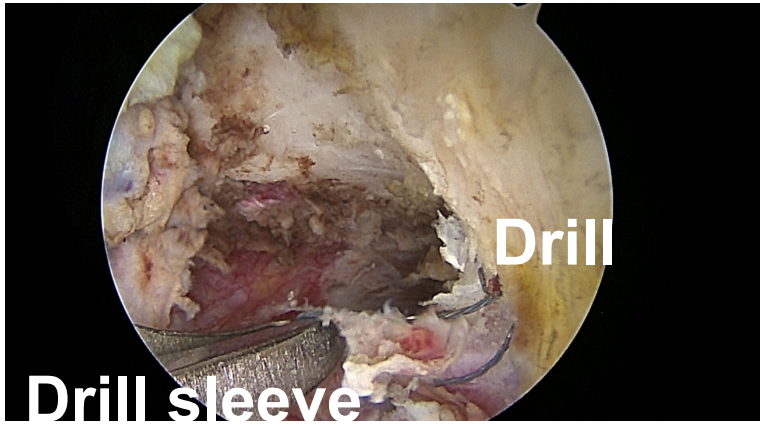

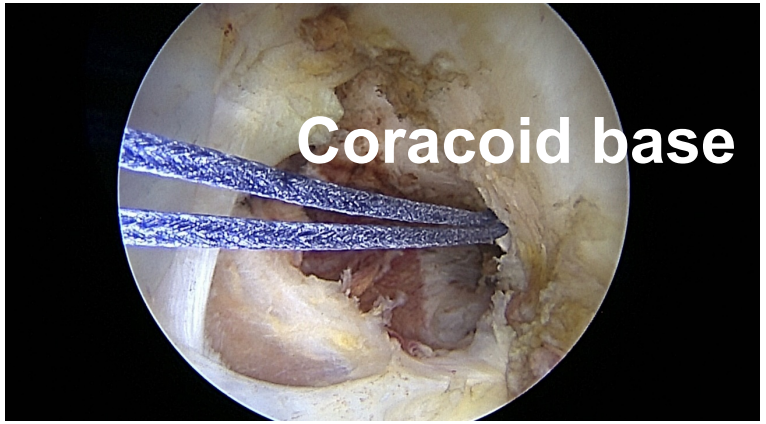

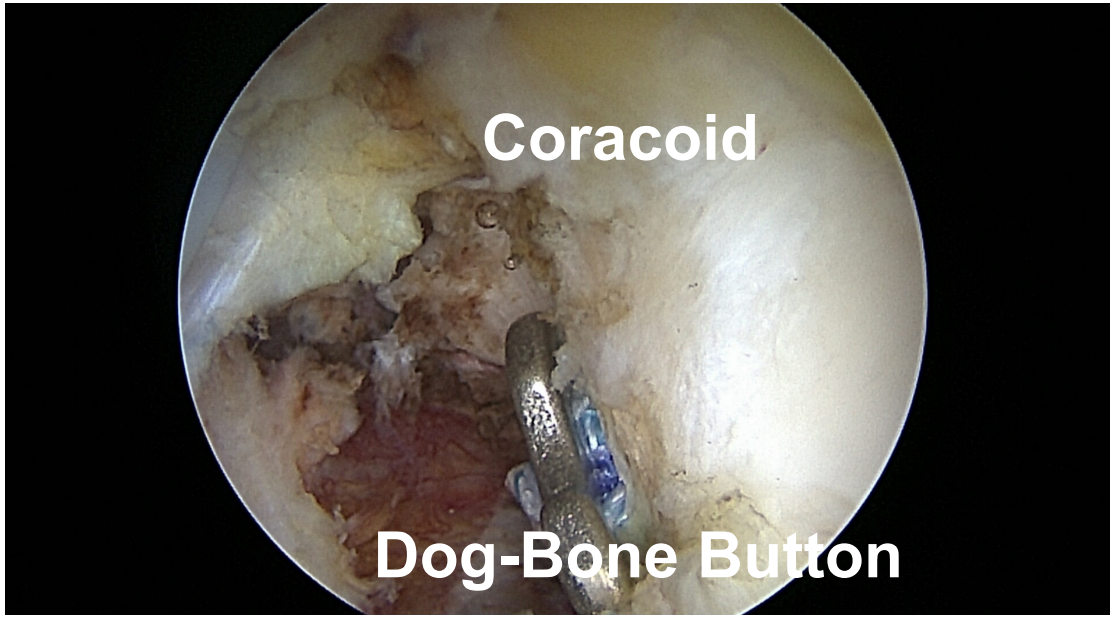

AC joint encirclage

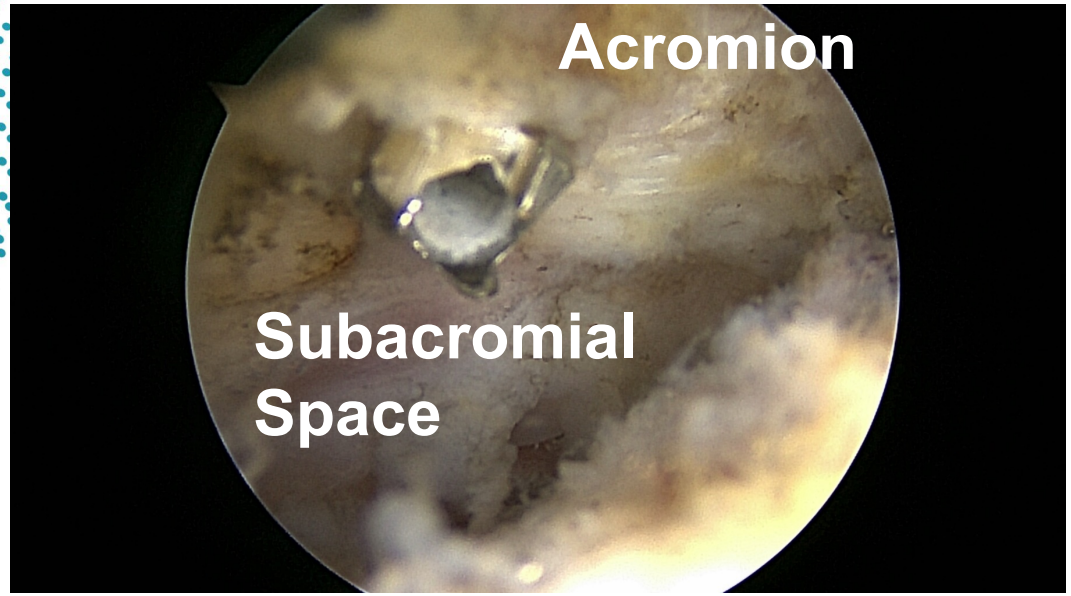

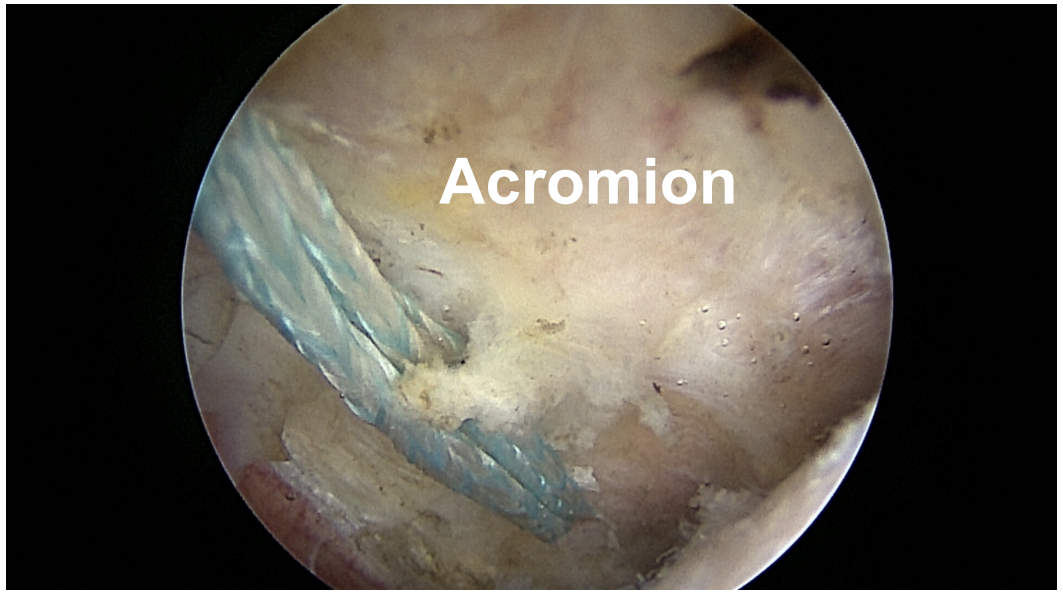

Post-operative course

- Smooth recovery
- Return to mountain biking in 9 months
- Radiologically stable construct
- At 2 years: excellent shoulder function, pain-free, full ROM



Case Analysis / Discussion

- Failure Risk with Hook Plate
  - Osteolysis
  - Pain
  - Second surgery
- Double Disruption of SSSC -
  - Structural instability of shoulder girdle
- Fix AC or Coracoid first?
  - Debatable

- Innovation in This Case:
- Used minimal coracoid stump for Dog Bone anchor
- Indirect fracture management
- Avoided direct surgical trauma to coracoid
- Intraoperative AC joint stabilization can restore coracoid alignment

Summary

- Concomitant injuries are common with coracoid fractures
- Double or triple disruptions of the SSSC require surgical management
- Reduction of other injuries of SSSC result in indirect reduction of coracoid fracture
- A suture button device is ideal in absence of base of coracoid fracture or glenoid fracture

References

1. Knapik DM, Patel SH, Wetzel RJ, Voos JE. Prevalence and management of coracoid fracture sustained during sporting activities and time to return to sport: A systematic review. *American Journal of Sports Medicine*. 2018;46(3):753–758
2. Pedersen V, Prall WC, Ockert B, Haasters F. Non-operative treatment of a fracture to the coracoid process with acromioclavicular dislocation in an adolescent. *Orthopedic Reviews*. 2014;6:5499
3. Thomas K, Ng VY, Bishop J. Nonoperative management of a sagittal coracoid fracture with a concomitant acromioclavicular joint separation. *International Journal of Shoulder Surgery*. 2010;4(2):44–47
4. Ogawa K, Yoshida A. Fracture of the coracoid process: classification and its relationship to treatment. *Journal of Shoulder and Elbow Surgery*. 1997;6(5):495–500
5. Eyres KS, Brooks A, Stanley D. Fractures of the coracoid process. *Injury*. 1995;26(5):303–306
6. American Academy of Orthopaedic Surgeons. Management of superior shoulder suspensory complex injuries. *Journal of the American Academy of Orthopaedic Surgeons*. 2020

ISAKOS CONGRESS 2025

MUNICH GERMANY

June 8–11